# BIOMIMETIC RESTORATIVE DENTISTRY

Pascal Magne, PD, DR MED DENT
Urs Belser, PROF, DR MED DENT

VOLUME 2

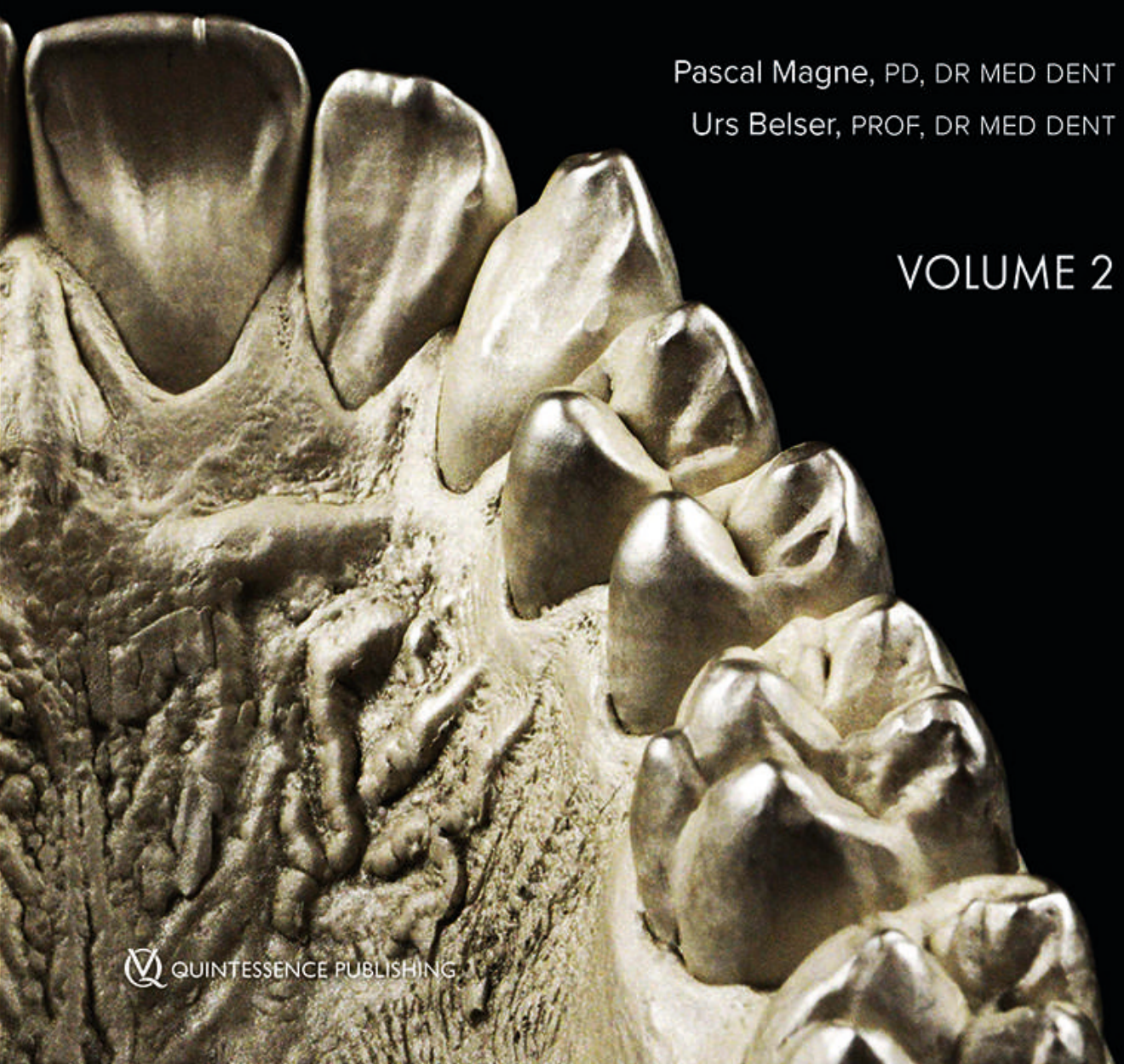

QUINTESSENCE PUBLISHING

Biomimetic Restorative Dentistry, Volume 2

Advanced Clinical Procedures and Maintenance

t.me/Dr_Mouayyad_AlbtousH

**Library of Congress Cataloging-in-Publication Data**

Names: Magne, Pascal, author. | Belser, U., author.
Title: Biomimetic restorative dentistry / Pascal Magne, Urs Belser.
Other titles: Bonded porcelain restorations in the anterior dentition
Description: Second edition. | Batavia, IL : Quintessence Publishing Co., Inc., [2021] | Preceded by Bonded porcelain restorations in the anterior dentition / Pascal Magne, Urs Belser. Chicago : Quintessence Pub. Co., c2002. | Includes bibliographical references and index. | Contents: Understanding the Intact Tooth and the Biomimetic Principle -- Natural Oral Design -- Ultraconservative Treatment Options -- Semi-Indirect Approaches in Anterior and Posterior Teeth -- Esthetic Treatment Planning and Diagnostic Approach -- Anterior Indirect Bonded Porcelain Restorations -- Maintenance and Advanced Repair Techniques. | Summary: "Applies the biomimetic principle to bonded restorations using composite resins and ceramics, describing the broad spectrum of indications and detailing the treatment planning, diagnostic approach, step-by-step treatment, and maintenance for each"-- Provided by publisher.
Identifiers: LCCN 2021005708 | ISBN 9780867155723 (hardcover)
Subjects: MESH: Dental Bonding--methods | Dental Restoration Repair--methods | Biomimetics | Esthetics, Dental
Classification: LCC RK652.5 | NLM WU 190 | DDC 617.6/95--dc23
LC record available at https://lccn.loc.gov/2021005708

A CIP record for this book is available from the British Library.
ISBN: 9780867155723

QUINTESSENCE PUBLISHING USA

©2022 Quintessence Publishing Co, Inc

Quintessence Publishing Co, Inc
411 N Raddant Road
Batavia, IL 60510
www.quintpub.com

5 4 3 2 1

All rights reserved. This book or any part thereof may not be reproduced, stored in a retrieval system, or transmitted in any form or by any means, electronic, mechanical, photocopying, or otherwise, without prior written permission of the publisher.

Editor: Leah Huffman
Design: Sue Zubek
Production: Sue Robinson

Printed in Croatia

t.me/Dr_Mouayyad_AlbtousH

# BIOMIMETIC RESTORATIVE DENTISTRY

## VOLUME 2

## Advanced Clinical Procedures and Maintenance

**Pascal Magne**, PD, Dr Med Dent

**Urs Belser**, DMD, Prof, Dr Med Dent



QUINTESSENCE PUBLISHING

Berlin | Chicago | Tokyo
Barcelona | London | Milan | Mexico City | Moscow | Paris | Prague | Seoul | Warsaw
*Beijing | Istanbul | São Paulo | Zagreb*

t.me/Dr_Mouayyad_AlbtousH

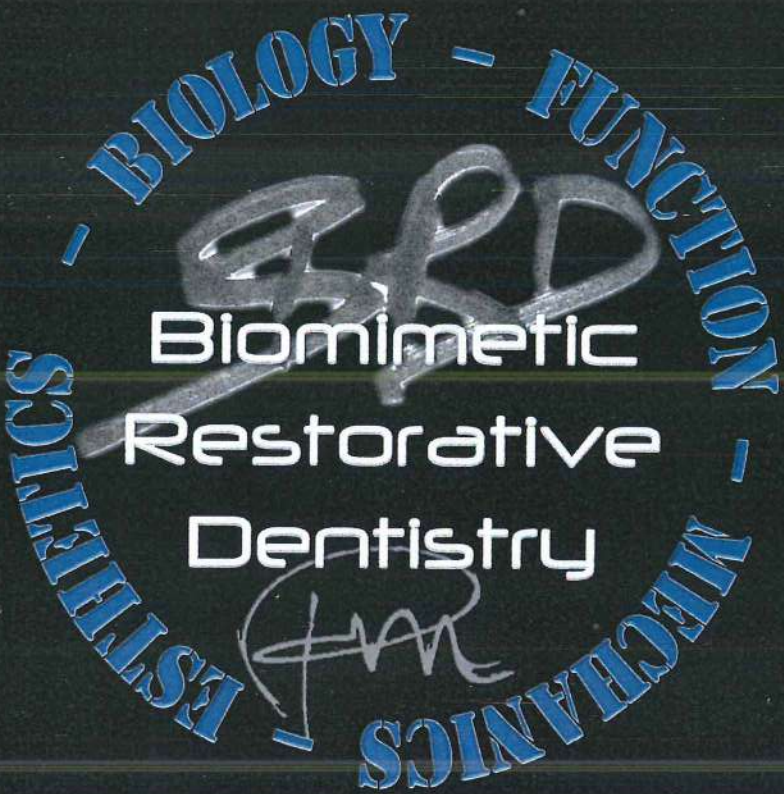


t.me/Dr_Mouayyad_AlbtousH

# CONTENTS

## VOLUME 1

*Foreword by William H. Douglas* *xxiv*
*Foreword by Panaghiotis K. Bazos* *xxv*
*Preface* *xxvii*
*The Four Elements* *xx*
*Gallery* *xxiv*

**1 Understanding the Intact Tooth and the Biomimetic Principle** *1*

1.1 Biology, Mechanics, Function, and Esthetics *2*
1.2 Optimal Compliance and Flexibility *4*
1.3 Rationalized Anterior Tooth Shape *6*
1.4 Rationalized Posterior Tooth Shape *8*
1.5 Mechanics and Geometry During Function *10*
1.6 Physiologic Enamel Cracking and the DEJ *20*
1.7 Natural Tooth Aging and Enamel Thinning *28*
1.8 Biomimetics Applied to Mechanics *36*
1.9 Copying vs Simulating Nature *52*
1.10 Biomimetic Implant Restorations *54*

**2 Natural Oral Design** *67*

2.1 General Considerations *68*
2.2 Fundamental Criteria *72*
2.3 Esthetic Integration and Smile Balance *132*
2.4 Morphology of Posterior Teeth *144*
2.5 Didactic Steps to Dental Morphology *178*
2.6 Drawing Models *184*

t.me/Dr_Mouayyad_AlbtousH

## 3 Ultraconservative Treatment Options *233*

3.1 Chemical Treatments and Biomimetics *234*
3.2 Nightguard Vital Bleaching *236*
3.3 Microabrasion and Megabrasion *250*
3.4 Remineralization and Resin Infiltration *254*
3.5 Nonvital Walking Bleach Technique *258*
3.6 Reattachment of a Tooth Fragment *272*
3.7 Adhesive Restorative Materials and Armamentarium *278*
3.8 Direct Restorations in Anterior Teeth *308*
3.9 Considerations for Direct Restorations in Posterior Teeth *340*
3.10 Deep Margin Elevation Technique *358*

## 4 Semi-(In)direct Approaches in Posterior and Anterior Teeth *379*

4.1 Historical Perspective and Classification *380*
4.2 The Chairside CAD/CAM Age *386*
4.3 Posterior CAD/CAM Restorations *388*
4.4 Immediate Dentin Sealing *400*
4.5 The Natural CAD/CAM Restoration *412*
4.6 Endocrowns and CAD/CAM Assemblies *414*
4.7 Luting Procedures in Posterior Teeth *416*
4.8 Anterior CAD/CAM Restorations *424*

*Index*

# VOLUME 2

## 5 Esthetic Treatment Planning and Diagnostic Approach *447*

5.1 Interactive Patient-Operatory-Laboratory Relationships *448*
5.2 Patient Management *450*
5.3 Photoshop Smile Design *452*
5.4 Treatment Planning and Initial Therapy *454*
5.5 Diagnostic Wax-up Step by Step *460*
5.6 Diagnostic Mock-up *478*
5.7 Special Cases *489*
5.8 Biocorrosion/Wear and Tight Bites *514*
5.9 Basics of Digital Dental Photography *542*
5.10 Shade Documentation/Communication *548*


t.me/Dr_Mouayyad_AlbtousH

## 6 Anterior Indirect Bonded Porcelain Restorations *565*

6.1 History and Classification of Indications *566*
6.2 Type I: Teeth Resistant to Bleaching *570*
6.3 Type II: Major Morphologic Modifications *574*
6.4 Type III: Extensive Restorations in Adults *588*
6.5 Combined Indications *606*
6.6 Types IV and V: Full-Coverage Crowns/Endocrowns *608*
6.7 Biologic Considerations *612*
6.8 Perspectives for Occlusal Veneers *616*
6.9 Tooth Preparation Principles *620*
6.10 Definitive Impressions *666*
6.11 Provisional Restorations *672*
6.12 Laboratory Procedures *682*
6.13 Try-in and Adhesive Luting Procedures *730*

## 7 Maintenance and Advanced Repair Techniques *769*

7.1 BPRs: Maximum Performance, Reduced Maintenance *770*
7.2 Routine Professional Hygiene *772*
7.3 Complications and Repairs *776*
7.4 Postbonding Crack Infiltration *790*
7.5 Replacement of Class 3 Composite Resin Restorations Adjacent to BPRs *796*

## αΩ The Whole Story: From La Chaux-de-Fonds to Los Angeles *801*

αΩ.1 Early Challenges: Setting the Stage *802*
αΩ.2 Early Academic Life and the Brothers *804*
αΩ.3 Touched by God *806*
αΩ.4 The Minnesota Experience *811*
αΩ.5 Geneva to Los Angeles *813*

*Index*


t.me/Dr_Mouayyad_AlbtousH



t.me/Dr_Mouayyad_AlbtousH

# ESTHETIC TREATMENT PLANNING AND DIAGNOSTIC APPROACH

Previous chapters have emphasized that *(1)* esthetics and function are equal concerns when restoring the anterior and posterior dentitions, and *(2)* modern concepts in restorative dentistry have introduced new solutions through bonded restorations that favorably distribute stress and involve the tooth crown as a whole in supporting occlusal force and masticatory function. The resulting biomimetic nature of adhesive restorations is particularly interesting when considering the restoration of an aging dentition; both function and appearance are affected by the physical characteristics of aging teeth. Biocorrosion and surface wear lead to progressive thinning of enamel, ultimately causing increased crown flexibility and higher surface strains. The restoration of tooth volume will not only restitute the original and more juvenile appearance of the smile but will also allow the comprehensive biomimetic recovery of the crown. This treatment outcome strongly depends on the therapeutic approach chosen, the driving force of which should be the preservation of the remaining tooth structure. For instance, a number of veneer preparation techniques will lead to major dentin exposures, the principle of enamel preservation can still be fulfilled by the use of a specific approach. This chapter describes a treatment rationale that incorporates the use of a diagnostic template resulting from the interactive relationships with the patient, and possibly the dental laboratory (when indirect techniques are chosen). This type of work strategy, documented with clinical cases, integrates additive wax-ups and acrylic mock-ups. The latter will provide a significant amount of diagnostic information and economy of tooth substrate invaluable to the realization and prognosis of the final restoration. Direct composite resin, semi-(in)direct, and indirect restorations can all benefit from this approach.





t.me/Dr_Mouayyad_AlbtousH

# 5.1 INTERACTIVE PATIENT-OPERATORY-LABORATORY RELATIONSHIPS

In most cases of esthetic rehabilitation, the treatment objective will be reached by means of a diagnostic effort.[1–6]

The diagnostic stage can be achieved in a two-step approach including *(1)* the elaboration of a diagnostic wax-up and *(2)* the fabrication of the corresponding template to be evaluated in vivo by both clinician and patient. In the case of anterior bonded restorations, a specific approach needed to be developed. Simple but essential tools are presented in this section—***the additive diagnostic wax-up and the acrylic mock-up—to be used during diagnostic steps, for molding direct restorations, to guide tooth preparation procedures, and to "Biocopy" semi-(in)direct restorations (see chapter 4, section 4.8).*** Four elements are emphasized: *(1)* the objectiveness and *(2)* simplicity of the approach as well as *(3)* the significant economy of tooth substrate and *(4)* invaluable amount of diagnostic information for design and prognosis of the final restoration.

***In the most complex indirect restorations, this strategy totally depends on adequate patient management and a close interactive relationship with the dental laboratory.***

The mastering of restorative techniques, optimal control of the esthetic parameters (see chapter 2), as well as adequate therapeutic choices (see chapters 3 and 4) will significantly enhance the probabilities of success. In the case of indirect restorations, the final outcome will also depend on *(1)* effective communication between the clinician's and the technician's team, and *(2)* the "champion-level" excellence of those teams. This exchange of knowledge also includes the patient,[7,8] who is evaluated by both clinician and technician and participates actively with them to the "triad of success" (Table 5-1). Patient management and initial therapy are therefore discussed in the first sections of this chapter.



t.me/Dr_Mouayyad_AlbtousH

**TABLE 5-1** Triad of success and generic flowchart for systematic patient evaluation and management in the case of indirect restorations

| | Operatory | Laboratory |
|---|---|---|
| Evaluation | Understand the patient's request | |
| | Radiographic survey, photographs, casts<br>Information to the patient<br>Photoshop Smile Design<br>Sequential treatment plan<br>Discussion | Esthetic and shade documentation<br>Discussion |
| Initial therapy | Orthodontics<br>Orthognathic surgery<br>Endodontics, bleaching | **Orthodontic setup** |
| Diagnostic phase | Periodontal surgery<br>Direct composite resins<br>**DIAGNOSTIC MOCK-UP** | **DIAGNOSTIC WAX-UP**<br>Shade documentation |
| Restorative phase | Tooth preparations and provisionalization<br>Impression<br>Adhesive delivery | Shade documentation (discolored teeth)<br>Master casts<br>Ceramic elaboration |
| Maintenance phase | | |

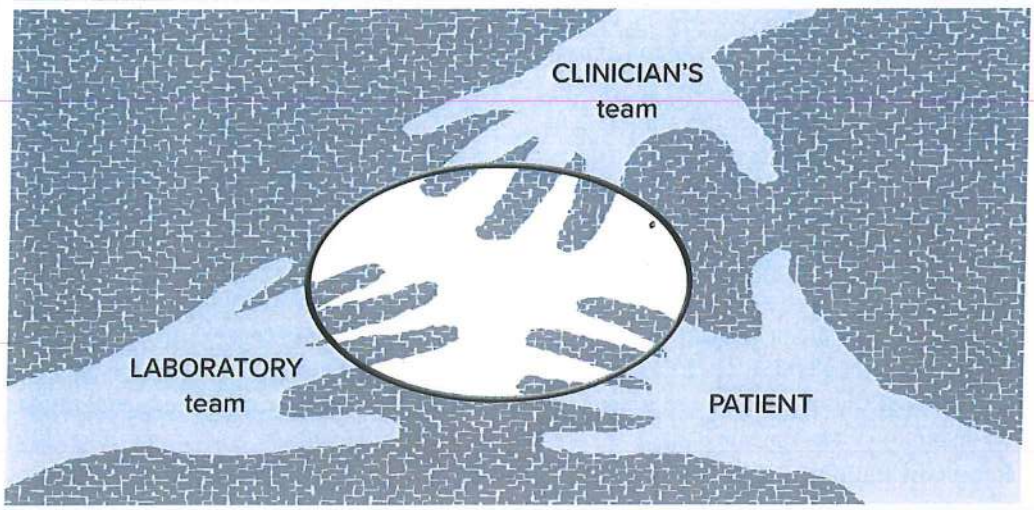


**The triad of success** is defined by a harmonious relationship between the patient, the operatory, and the laboratory. The restorative dentist only represents one "finger" of the operatory team's "hand" in the circle of this relationship. Other "fingers" represent the periodontist, the orthodontist, etc. Both the clinician and the dental technician must understand the patient's request. It is therefore ideal that the patient visits the dental laboratory even before treatment planning begins. The dental technician can then develop an esthetic status in the form of images and notes. Shade can be documented at this stage, but it is ideal that the patient visits the laboratory again, especially when bleaching and other preliminary procedures are probable. In the case of discolored teeth, additional shade documentation should be carried out following tooth preparation. Among preliminary laboratory procedures, the diagnostic wax-up is of paramount importance for the initial therapy. The diagnostic phase represents the most creative and interactive part of the treatment, and the diagnostic mock-up must allow envisioning the final objective. In this way, the creative effort during the restorative phase remains minimal and will be limited to the reproduction of the diagnostic mock-up in the form of the final restorations.


t.me/Dr_Mouayyad_AlbtousH

# 5.2 PATIENT MANAGEMENT

Appropriate management and counseling of patients with esthetic problems undoubtedly represents the most critical phase of the treatment. The task may be particularly challenging if the confidence of an individual (who suffered from a previous therapeutic failure) has to be recovered. In the case of indirect restorations, a combined and structured management by the dental operatory and the dental laboratory will provide adequate bases for full cooperation from a confident patient. During the initial phase, the clinician should respect the following sequence:

1. **Know the patient:** This first step aims at understanding the patient's primary request. It is of utmost importance that the clinician listens carefully to the patient's explanations in order to define the main expectations. The patient should not sit in the dental chair at this stage but at the same level as the clinician. Use of models of intact dentitions, photographs, and fashion magazines can significantly help in communicating with the patient.
2. **Initial documentation:** After the patient has expressed their desires, the clinician collects the basic elements of the initial documentation, ie, a radiographic survey and a systematic clinical examination (evaluation of temporomandibular joints, periodontal and endodontic conditions, existing restorations, etc). Photographs and study casts (or optical scans), possibly mounted in an articulator, complete the initial documentation.
3. **Inform the patient:** Based on the aforementioned documents, the clinician explains the existing problems to the patient, utilizing the radiographs, photographs, and study casts as aids. The use of simple and comprehensible terminology is essential. ***A patient who thoroughly understands the information will better perceive possibilities and limitations of the treatment.*** Finally, the major elements of the treatment options, when available, are explained (direct vs semi-direct or indirect). In that context, demonstration models and/or de-identified clinical photographs of other patients can be helpful in explaining the different types of restorations. ***The proposed treatment options should always be based on*** *"The Four Elements" (see pages xx–xxi in front matter): science, experience, common sense, and the patient.*
4. **Sequential treatment plan:** At this time, the clinician elaborates a sequential treatment plan including possible alternatives. Treatment duration and costs are determined. When using indirect techniques, the laboratory fee should be presented separately. Patients are often unaware of the amount of work required in the laboratory, especially when working with a "champion-level" ceramist. When treatment and patient management are shared equally by the clinician's and technician's teams, it is not unusual for laboratory and clinical fees to be similar.
5. **Final phase of initial patient management:** This is not a clinical session but a discussion in which the clinician explains the parameters of treatment (objectives, sequence, duration, costs, limitations, prognosis, and alternatives) to the patient. Once the patient gives informed consent, the practical modalities of the treatment can be planned.



t.me/Dr_Mouayyad_AlbtousH

## Indirect restorations and the laboratory team

The development of sophisticated techniques for indirect restorations traditionally involves a close cooperation with the dental laboratory. When possible, the patient should visit the ceramist as early as possible during the initial stages of patient management (Fig 5-1; see also Table 5-1). This first visit to the dental laboratory is essential for two reasons: *(1)* Having some knowledge about the technical aspects, the patient will better understand the treatment that has been proposed, and *(2)* it offers to the ceramist the opportunity to complete—similar to the clinician—his or her initial documentation, which represents the basis for the working plan. Patient management by the laboratory is quite similar to that by the operatory. The ceramist's documentation comprises a photographic status and shade selection.

***The first contact between the patient and the dental technician is of primary importance. Unfortunately, in daily practice, such an approach is frequently neglected.*** Undoubtedly, many clinicians hesitate to send their patients to a dental laboratory because they fear inadequate reception and lack of hygiene. For that reason, dental technicians must be educated to approach the patient. A dental laboratory should have a special area for patient consultations that includes basic items, such as a comfortable chair, sink with a hand-disinfecting device, examination gloves, and protective napkins. Virtual distance meetings are also possible but will never replace an in-person experience.



**FIG 5-1 The laboratory "factor."** Seeing the ceramist's laboratory with its multitude of ceramic powders and colorants helps the patient understand the fabrication process and monetary value of these unique ceramic pieces. A customized ceramic workpiece might require over 30 different masses. The patient's acceptance of future treatment is significantly enhanced by this visit to the laboratory.


t.me/Dr_Mouayyad_AlbtousH

# 5.3 PHOTOSHOP SMILE DESIGN

Photography and image processing are powerful tools not only to provide guidance in the treatment planning and diagnostic approach but also to motivate the patient.[9–11] The digital simulation process can take various forms, depending on the skills of the operator and software complexity. It ranges from sophisticated 3D approaches,[9,12–14] such as the DSD approach (Digital Smile Design),[9] which comprises many steps and the use of a specific software package to print 3D models, to the simplistic PSD (Photoshop Smile Design), which uses tools in the Photoshop software by Adobe.[10] While DSD uses 3D templates of existing dentitions, PSD is only 2D and relies more on the existing knowledge of the operator.

***The key element in PSD is the Liquify tool found under the Filters menu. Along with a few other tools such as the Rectangle Marquee and the Clone Stamp tools, the simulation can look very realistic and powerful (Fig 5-2). After looking at these simulations, patients are more prone to explore surgical and orthodontic options.***

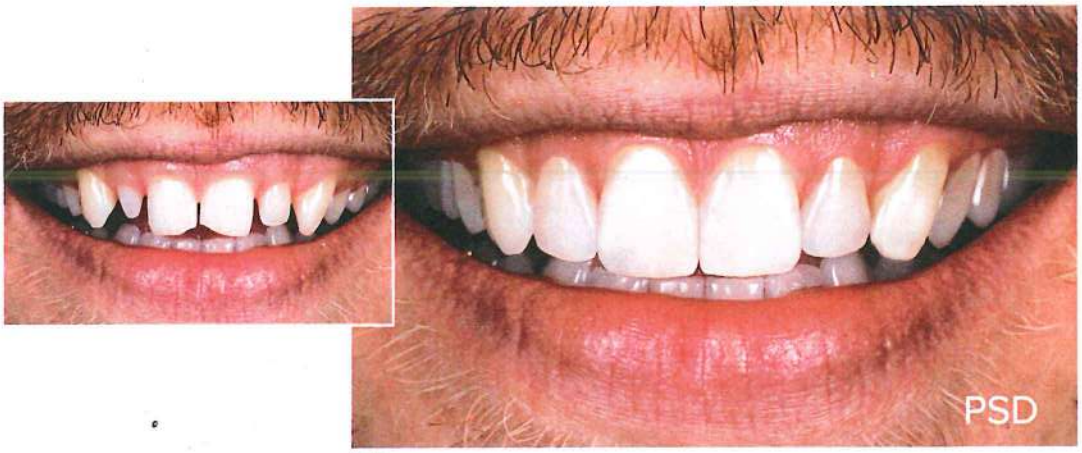


5-2a

**FIG 5-2 Step-by-step PSD.** This patient is not a candidate for orthodontic treatment and requests a low-cost and minimally invasive approach to improve his smile. *(a)* The PSD is applied. An experienced operator with good knowledge of morphology needs about 20 minutes to complete the following steps in the software: *(b)* The gingival contours are corrected to compensate for the canting. *(c)* Under Filters in the main menu of the Photoshop software, the Liquify tool is selected. *(d)* A new window appears with a circular tool. The tool size can be easily adjusted with the bracket keys "[" (smaller) and "]" (larger) on the keyboard. *(e)* By clicking and dragging the circle, the gingiva can be repositioned virtually. The left central incisor was edited first. *(f)* The procedure is illustrated on the right central incisor by selecting a rectangle that anticipates the dimensions of the tooth (Rectangle Marquee tool) and clicking on the Liquify tool. *(g)* The new Liquify window now includes only the tooth to be edited, allowing the dragging of the tooth outline near the rectangle outline to match the vertical interdental contact lines *(h)*. The process (Rectangle Marquee and Liquify tool) is repeated for each tooth. The Clone Stamp tool is used to clone some of the reflective line angles or translucent areas from other teeth and the Liquify tool to further shape them. The Blur/Smudge tools also help to blend the edited areas. The right canine was not modified at all, while the left canine was slightly shortened in addition to the virtual gingivoplasty. The left lateral incisor was modified (same process as the central incisors), and a mirrored copy (slightly stretched) was used to obtain the right lateral incisor. *(i)* Completed virtual simulation. The same case can be seen in Fig 2-17, with detailed treatment steps demonstrated in Figs 5-14 and 6-29.



t.me/Dr_Mouayyad_AlbtousH

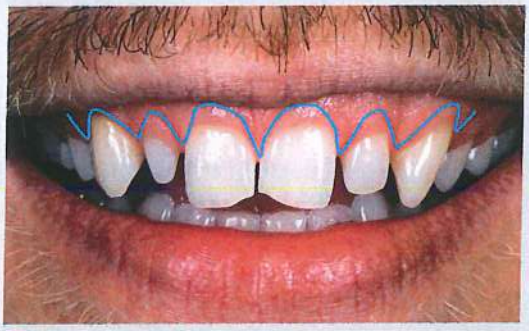

5-2b

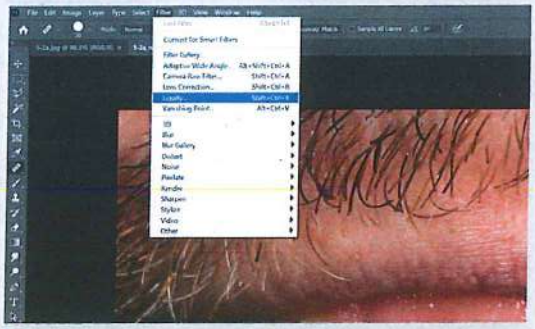

5-2c

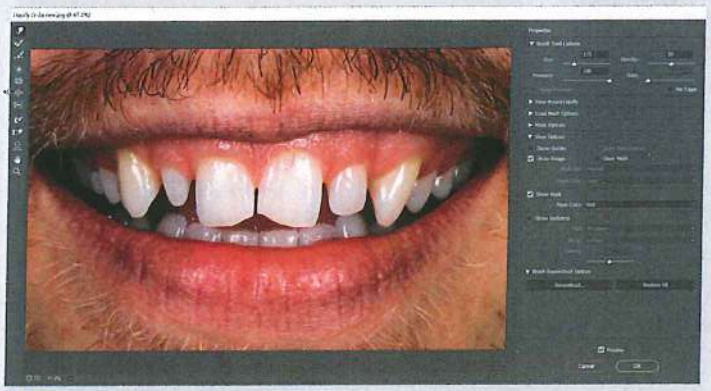

5-2d



5-2e

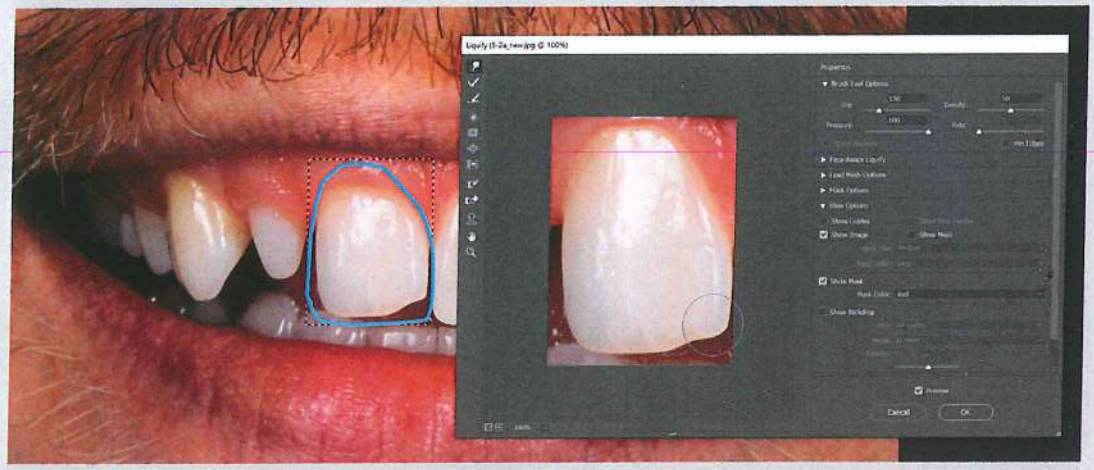

5-2f

5-2g



5-2h




5-2i



t.me/Dr_Mouayyad_AlbtousH

# 5.4 TREATMENT PLANNING AND INITIAL THERAPY

Treatment planning consists of determining chronologically the sequence of treatment and coordinating clinical and technical interventions. The clinician defines the number of clinical sessions corresponding to the sequence of treatment. ***When indirect restorations are planned, the clinician then informs the laboratory to coordinate the initial treatment plan and the dates of the principal restorative phases: wax-up, final impressions, eventual clinical trials, and delivery.***

The initial phase of treatment typically comprises preventive, periodontal, and operative aspects, which are too often neglected. They represent essential "touch-ups," sometimes only minor corrections that will have a significant effect on the final outcome. The diagnostic wax-up and corresponding mock-up described in the next sections can significantly influence this particular phase. The following interventions are most frequently undertaken when esthetics plays a key role: mucogingival surgery, bleaching, orthodontics, and direct composite resin restorations.

## Mucogingival surgery

***Adequate health and morphology of the periodontium are responsible for 50% of the final esthetic outcome. Even the best restoration will not be able to compensate for periodontal deficiencies.*** In some situations, graft-type interventions (Fig 5-3) or minor remodeling of gingival contours (Fig 5-4) can ensure the final integration of the restorations.



5-3a



5-3b

**FIG 5-3 Connective tissue graft to improve gingival contour before indirect porcelain veneers.** *(a)* There is significant tooth aging and enamel thinning of the central incisors and left lateral incisor, plus an unsightly black triangle between the central incisors. *(b)* Progressing recessions around the left central and lateral incisors are responsible for asymmetric gingival contours. A connective tissue graft from the palate was first completed using the "envelope" technique[15,16] (clinician: Dr Jean-Pierre Ebner). Undermining partial-thickness incisions create the envelope. *(c)* Vertical releasing incisions are not necessary. *(d)* The combined epithelial and connective tissue graft is placed over the denuded areas, and the flap is sutured with 7-0 polypropylene sutures, the graft being secured with two additional sutures. *(e)* One-week postoperative view. *(f and g)* Comparison of preoperative and 3-month postoperative views shows considerable enhancement of gingival contours. The preexisting Class 5 composite restoration was removed except for the most coronal part, which temporarily supported and maintained the gingival profile.



t.me/Dr_Mouayyad_AlbtousH



5-3c



5-3d



5-3e



5-3f



5-3g



5-3h




5-3i

**FIG 5-3** *(cont)* A specific diagnostic phase was then carried out, followed by preparation of the involved teeth for porcelain veneers, which are detailed in chapter 6 (Fig 6-45). *(h)* Maximum interdental preparation allowed for the ceramic to be extended with interdental "miniwings" to close the black interdental triangle (see also chapter 6, Figs 6-6b and 6-43a). *(i)* The 10-year postoperative view demonstrates good stability. There were extensive dentin exposures (90% of the prepared surface) during tooth preparation, which were sealed by the IDS technique (see technique in Figs 6-45h to 6-45l).



t.me/Dr_Mouayyad_AlbtousH

***In some complex cases such as that described in Fig 5-2 (major surgical correction planned), it might be necessary to give the patient a surgical "test drive" before the actual surgery using the dual-additive wax-up/mock-up (see Figs 5-13 to 5-15).***

## Bleaching

The optical conditions of the underlying dental tissues can have a negative influence on the final esthetics; bleaching procedures allow reestablishment of a tooth color that will facilitate integration of bonded restorations. The treatment of nonvital discolored teeth to be restored with bonded restorations is recommended exactly as described in chapter 3 (section 3.5). ***The restorative phase must be delayed for 3 to 4 weeks after the end of bleaching because of the inhibiting effect of oxygen residues on the bond strength of composite resins. The same protocol is followed for vital bleaching.***

## Orthodontics and orthognathic surgery

The realignment of teeth to be veneered is generally undertaken before the restorative phase. However, the placement of provisional crowns (see chapter 6, Fig 6-15) or "touch-up" composite resin restorations may improve crown shape and facilitate the fine positioning of each tooth by the orthodontist; the latter must, in turn, be guided by the orthodontic setup (see chapter 6, Fig 6-7). In some rare cases, orthognathic surgery might be indicated in conjunction with orthodontics, which requires special treatment planning (see Fig 5-17).

## Direct composite resins

Minor modifications of neighboring teeth are often necessary before placing semi-(in)direct/indirect restorations. A typical situation is the optimization of lateral incisor shape and volume before veneering central incisors (Fig 5-4). Lateral incisors are ideal for direct application of composite resins (small corrections of shape and position) because the restorative material is fully supported by intact underlying enamel and lateral incisors are normally not subjected to significant functional loads.

The wax-up and corresponding acrylic mock-up help significantly in detecting and correcting small problems of crown shape and length in neighboring teeth (Fig 5-4).

**FIG 5-4 Minor defects and irregularities of neighboring teeth and gingival contour revealed by basic mock-up.** *(a)* Preoperative clinical view. The patient has requested redefinition of volume and length of central incisors and closure of the diastema. *(b)* A quick diagnostic wax-up and a very basic mock-up (no coloring and glazing) were carried out and reveal that the lateral incisors must be modified *(white arrowheads)*; the gingival scallop around the left central incisor must also be increased *(black arrowhead)*. Direct composite resin restorations on the left and right lateral incisors as well as a gingivectomy around the left central incisor were performed during the same clinical session *(see next pages)* and followed by two other sessions for the realization of porcelain veneers on both central incisors. *(c)* Final postoperative view.



t.me/Dr_Mouayyad_AlbtousH



5-4a

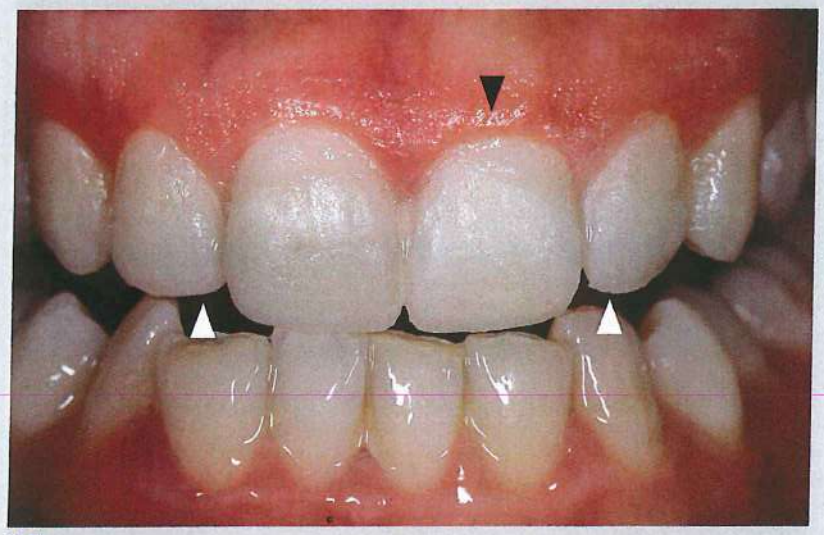

5-4b



5-4c



t.me/Dr_Mouayyad_AlbtousH



5-4d



5-4e



5-4f



5-4g

**FIG 5-4** *(cont)* Preliminary procedures (first clinical session). *(d)* Articulating paper has been rubbed on the surface of the right lateral incisor to highlight the missing mesial coronal volume and the corresponding transition line angle. Freehand bonding was carried out with enamellike and incisal composite resins. *(e)* The left lateral incisor is too short and must be modified using the silicon index of the wax-up. *(f)* Finally, the gingival contour around the left central incisor is too flat. *(g)* A minor gingivectomy was necessary. *(h and i)* Final intraoral views show a more harmonious relationship between teeth and soft tissues. *(j and k)* Direct comparison of the preoperative smile and the new situation. Tooth preparations for this particular case and the fabrication of master models and ceramic layering can be found in chapter 6 (Figs 6-31, 6-60 to 6-62, and 6-65).


t.me/Dr_Mouayyad_AlbtousH



5-4h



5-4i



5-4j



5-4k



t.me/Dr_Mouayyad_AlbtousH

# 5.5 DIAGNOSTIC WAX-UP STEP BY STEP

## General considerations

Enamel constitutes a highly specialized tissue. It has been particularly precious to the clinician since 1955, when Buonocore proved it to be an essential substrate for bonding.[17] Today, the predictable value of enamel bonding is witnessed by the medium- to long-term clinical success of porcelain veneers.[18–21] Enamel is a brittle substrate, and its integrity is dependent on the crack-arresting capacity of the thick longitudinally oriented collagen fibers of the dentinoenamel junction[22] (DEJ; see chapter 1, Fig 1-10).

***Therefore, both enamel and the DEJ must be carefully preserved by an adequate tooth preparation strategy.***

It is extremely important to identify the facial enamel wear pattern of the teeth to be restored (Fig 5-5). When the residual enamel is thin, as is the case with aged or worn incisors, preparation methods (for indirect porcelain veneers) using the preexisting tooth surface as a reference for enamel reduction are absolutely contraindicated. The "simplified laminate preparation," which uses specific cutting tools to avoid so-called "freehand preparation,"[23] is also contraindicated. In those techniques, a uniform tooth reduction of at least 0.5 mm is performed using diamond burs with calibrated rings. Another classical veneer preparation method, using the preexisting tooth surface as a guide, consists in taking silicon indexes of the labial surface of the unprepared tooth. Significant dentin exposures are to be expected when such freehand procedures are used on intact central incisors.[24] The situation is most critical when treating aging dentitions with thin residual enamel.

> Accordingly, a key element for enamel preservation during tooth preparation for semi-(in)direct/indirect bonded restorations is the prior definition of the final tooth volume.

When a significant thickness of enamel is initially missing because of wear or biocorrosion (Fig 5-5), the future restoration should aim to restitute the original volume of the tooth that has been lost over time. This in turn will restore an appropriate tooth prominence and biomimetic behavior of the crown[25]; above all, it will allow significant preservation of enamel substrate and supporting DEJ during tooth preparation.[26] Therefore, an additive wax-up, corresponding silicon indexes, and mock-up are essential references for tooth reduction (see chapter 6, Fig 6-23).[2,3,6]

**FIG 5-5 Typical enamel aging and effect on labial surface architecture.** *(a)* Schematic incisal view showing the volume loss and softening of the labial surface. *(b)* Incisors originally present strong enamel ridges and marked transition line angles (tangential facial view). *(c and d)* Examples of teeth exhibiting different wear patterns: little facial wear with textured surface *(c)* or severe facial wear with soft glossy surface *(d)*. Note the amount of enamel to be saved *(arrows and dotted line in d)* when using special preparation methods with an additive wax-up.





t.me/Dr_Mouayyad_AlbtousH

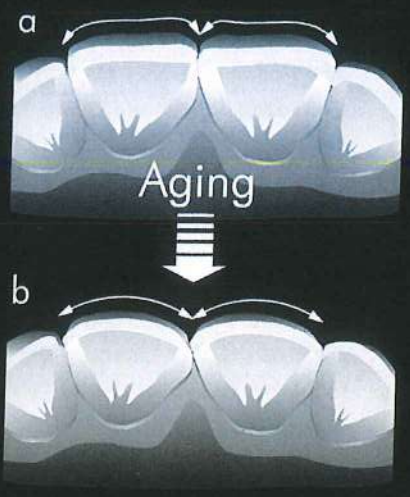


5-5a



5-5b

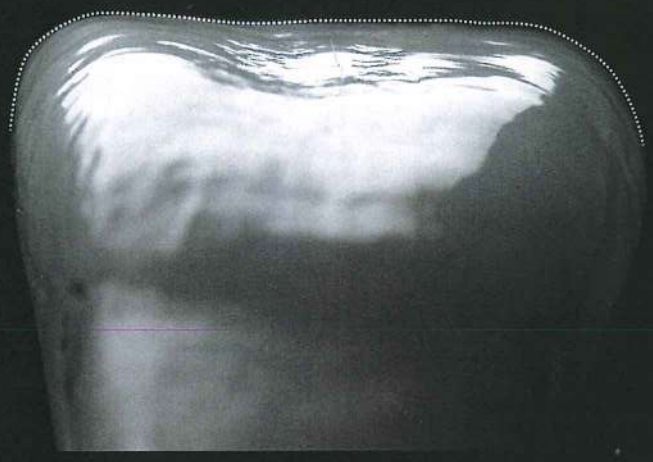

5-5c

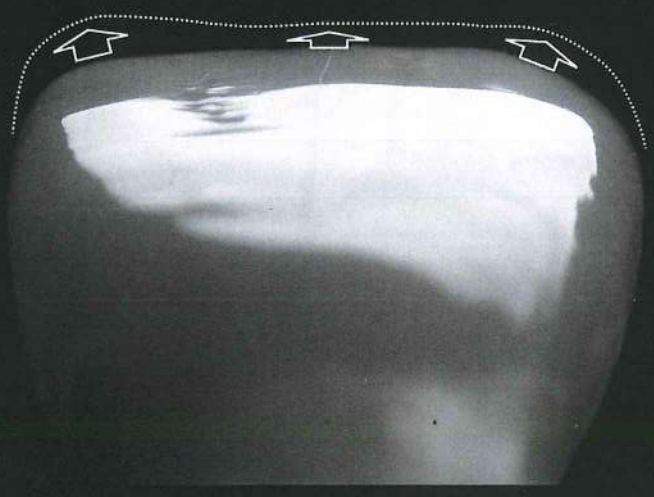

5-5d


t.me/Dr_Mouayyad_AlbtousH

## Essentials for the additive wax-up

### Analog vs digital

The future of additive wax-ups certainly holds in the use of numeric systems.[27] ***The craftsmanship required for a wax-up, however, is considered by many as a fundamental skill, which can be compared to the handwriting skill vs typing text on a keyboard,*** or the fabrication of a mechanical movement for an analog watch vs a quartz movement with a numeric display. There is a superior dimension in craftsmanship that cannot be explained rationally. It can be ascertained that to perform an analog additive wax-up, precise knowledge of morphology and esthetic integration is mandatory. Investing in this knowledge constitutes a long-term asset, which will contribute to multiple aspects of the dental work not yet mastered by numeric systems.

### Analog diagnostic models and facial reference

White diagnostic casts (Type IV stone; eg, GC Fujirock EP) should be generated from silicon impressions. ***As explained under criterion 14 in chapter 2 (smile alignment, see Fig 2-14), in 80% of cases the biometric reference of the interpupillary line should be transferred to the diagnostic models using an esthetic transfer device (eg, Ditramax system).***[28] The casts can be trimmed parallel to this reference line and assembled with flat prefabricated bases for mounting in the articulator (Fig 5-6). Visual perception while performing the wax-up will be highly influenced by the model base. A canted base may result in a canted wax-up. The line between auditory meatuses is often canted.[29] Hence, conventional facebows cannot be used as an esthetic transfer device but only as an approximate functional transfer, unless it is aligned to the bipupillary line instead of the auditory meatus.

### Brain conditioning for creativity

Arts in general stimulate the brain.[30] Listening to music is a significant way to increase cognitive and motor skills. The mood generated by classical music is a very inexpensive and efficient way to enhance creativity while performing the diagnostic wax-up.

Intuition, sensitivity, and a good perception of the patient's personality should allow the operator to define a preliminary restorative goal.

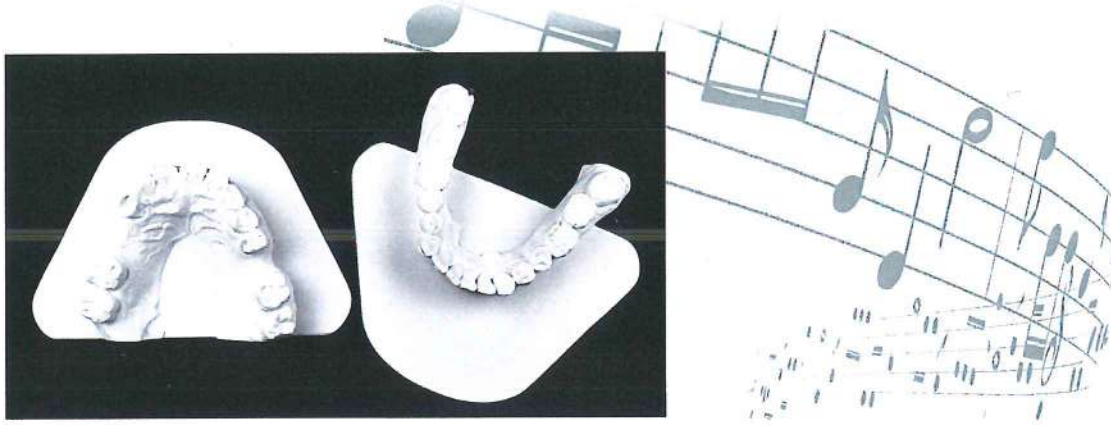

5-6a

**FIG 5-6 Model trimming and fabrication.** Horseshoe-shaped diagnostic casts (GC Fujirock EP Polar White) are trimmed parallel to the interpupillary line using an esthetic transfer device (see possible device and procedure in Fig 2-14c). Cast height should be about 20 mm thick (from cusp tip to base). *(a to c)* For the purpose of mounting in the articulator, they can be assembled to prefabricated bases (thickness ~ 7 mm) using cyanoacrylate adhesive gel. *(d and e)* The mandibular model can be mounted accurately in two steps (remounting technique). A first amount of mounting stone is allowed to set with a gap from the mounting plate. After 45 minutes (80% of stone expansion complete),[31] retentive grooves are drilled and bite registration material is used to fill the remaining gap. The diagnostic approach and treatment for this specific case can be seen in Fig 5-25.



t.me/Dr_Mouayyad_AlbtousH

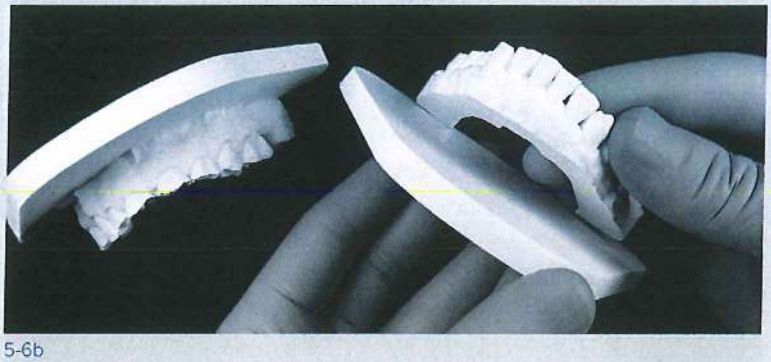

5-6b

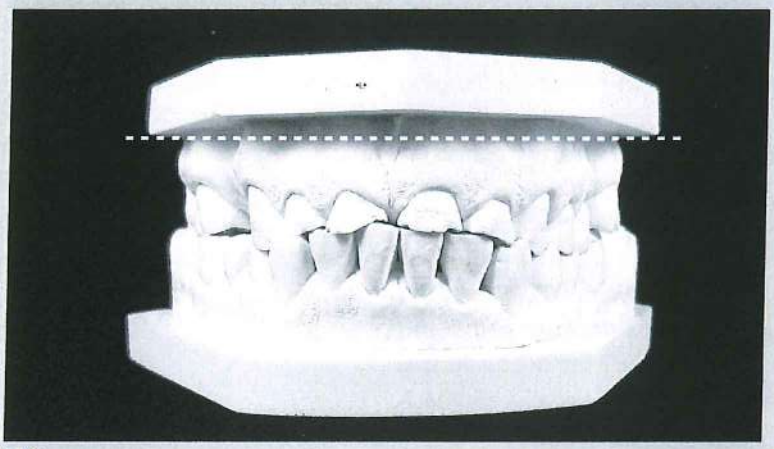

5-6c

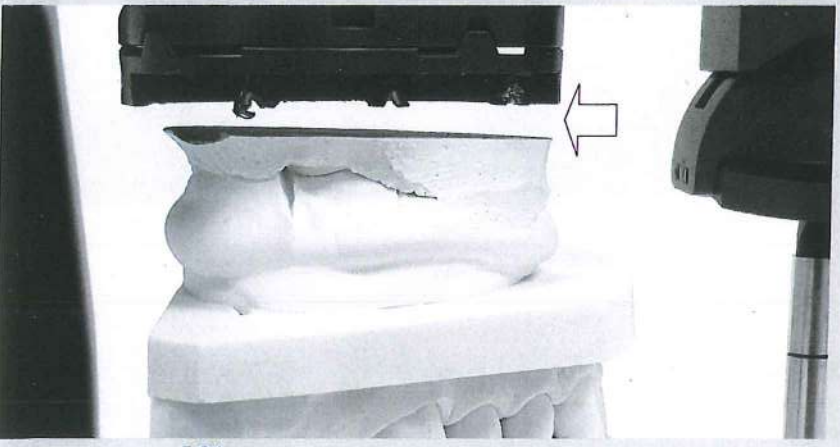

5-6d

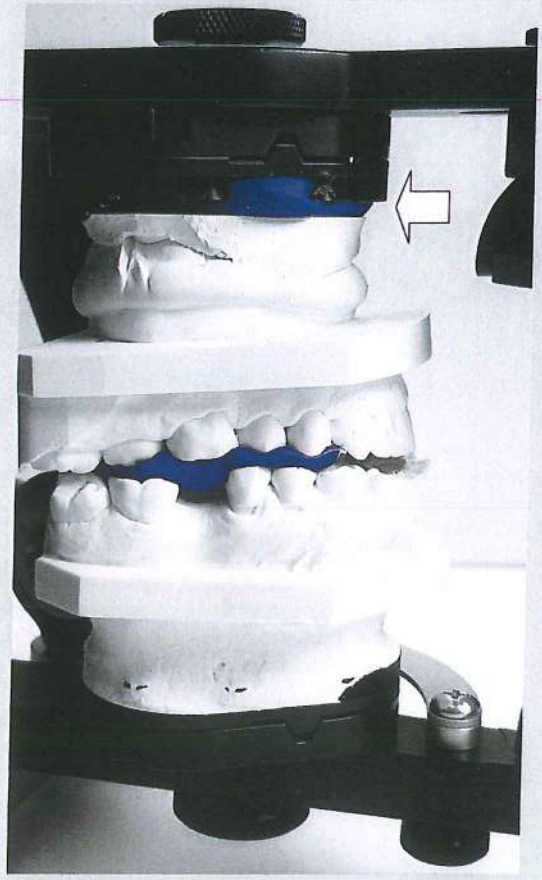

5-6e



t.me/Dr_Mouayyad_AlbtousH

## Example of step-by-step digital wax-up

As previously mentioned, the additive wax-up can be obtained in an analog way or in a digital way. There are numerous software packages included in most dental CAD/CAM design tools allowing numeric wax-ups. Analog posterior wax-ups, which have much less subjective components than anterior ones, can be easily replaced by very good digital proposals available in most CAD/CAM design software packages. ***Digital anterior proposals are the most challenging due to the esthetic components, numerous tooth shapes, and special effects needed for blending a given shape with the existing hard and soft tissues. Figure 5-7 illustrates the use of a free nondental design software (Autodesk Meshmixer, Autodesk) where STL files of the preoperative dentitions (including lips and face) can be imported and combined with files of natural dentitions.*** As in the analog approach, various intact dentition models can be collected over time, scanned, and presented to the patient to understand their perception of dental esthetics and tooth shape. Each tooth shape on those reference models can be imported and aligned tooth by tooth to create a digital design proposal. Numerous tutorials for the software are available online and will allow the user to become familiar with the process, which is summarized in Fig 5-7 (courtesy of Dr Ivan Contreras Molina). Upon completion of the numeric wax-up, a model can be printed and refined manually to make silicon indexes for the fabrication of a mock-up and to guide the future tooth preparations.

For the advanced operator, Blender (Blender Foundation) is another free design software, an Open Source suite allowing modeling, sculpting, textured animation with lighting, and ultrarealistic rendering.





5-7a

**FIG 5-7 Step-by-step digital wax-up with Autodesk Meshmixer.** *(a)* Preoperative intraoral image showing old, chipped composite resin restorations and initial intraoral scans showing incisal edge line discrepancy (visual tension, *arrows*) compared to ideal cohesive smile line *(dotted line)*. *(b)* Digital bite registration in Medit software (Medit). *(c)* Alignment scans of teeth, mouth, and nose in Medit Link software. *(d)* Occlusal analysis, showing safe overjet for anterior restorations. *(e to i)* Intraoral scans of the lips and nose (obtained with Medit too) are imported into the Autodesk Meshmixer program. If needed, photography with retractors can be aligned with the occlusal plane on initial scans, using the WindowTop program (free software to overlap two windows from different programs through a transparency effect).



t.me/Dr_Mouayyad_AlbtousH

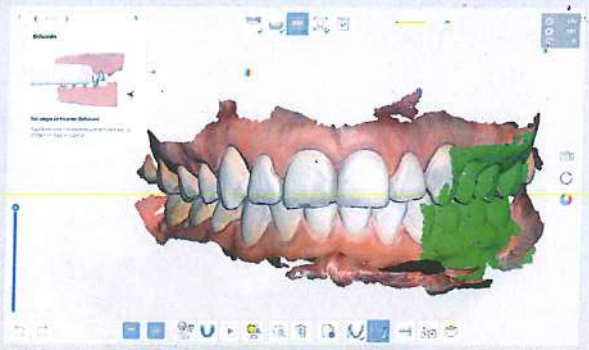

5-7b

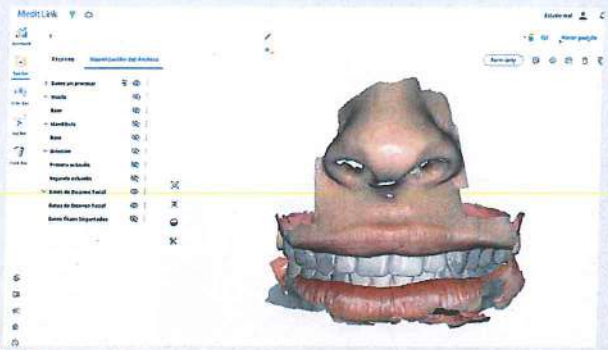

5-7c



5-7d

## Autodesk Meshmixer

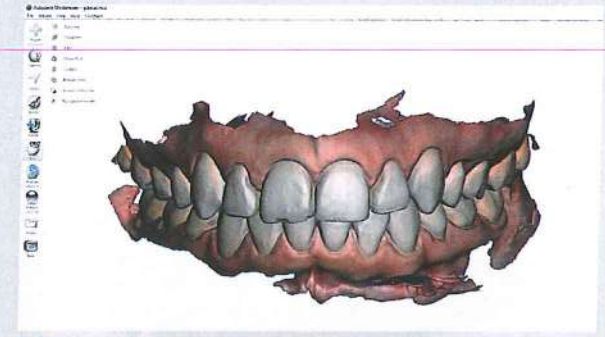

5-7e



5-7f

## WindowsTop



5-7g



5-7h



5-7i



t.me/Dr_Mouayyad_AlbtousH

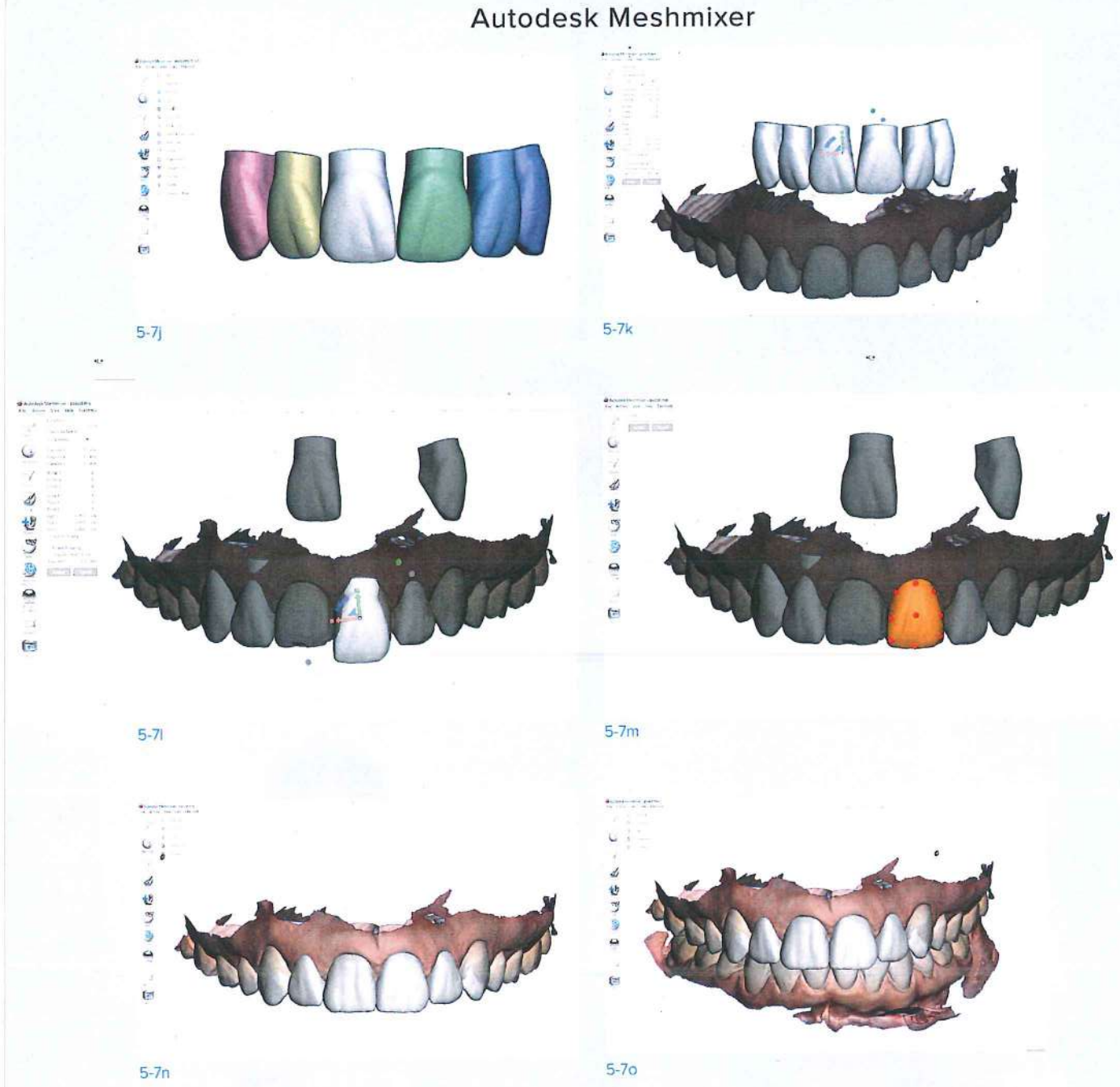


**FIG 5-7** *(cont) (j)* An STL library obtained from young patients with intact natural teeth can imported into Autodesk Meshmixer to be used as reference for the digital wax-up. *(k to m)* Initial alignment of the natural STL model with the initial maxillary scan in Autodesk Meshmixer. With the free transformation tool group, each natural tooth can be moved near its preoperative analog. Using the warp tool, the ideal shape and final cervical position can be fine-tuned to respect the soft issue and emergence areas. *(n to p)* Final wax-up and other views of digital wax-up in occlusion and with lip integration. *(q)* Digital model with final wax-up ready for printing. *(r and s)* Printed wax-up model. *(t and u)* Preoperative smile and smile with mock-up obtained by molding with silicon indexes from the printed model. (Courtesy of Dr Ivan Contreras Molina, Morelia, Mexico.)


t.me/Dr_Mouayyad_AlbtousH

Autodesk Meshmixer



5-7p

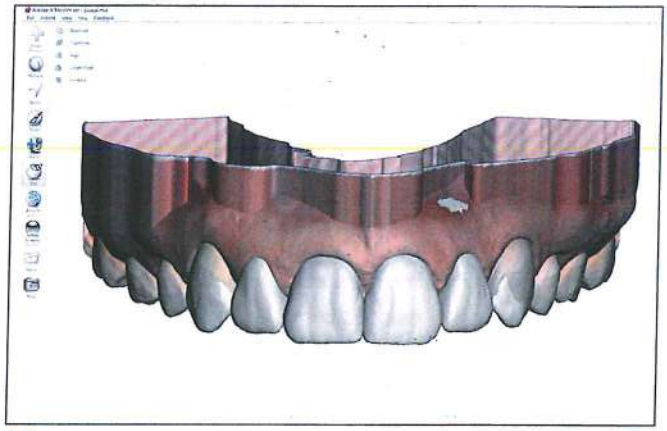

5-7q

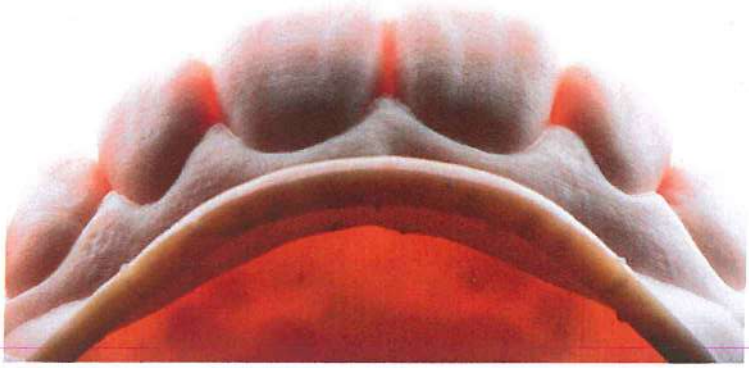

5-7r

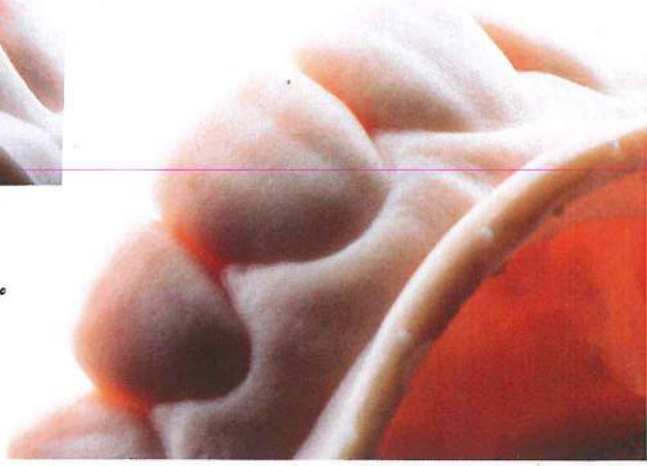

5-7s



5-7t



5-7u



t.me/Dr_Mouayyad_AlbtousH

## Step-by-step analog wax-up

### Basic materials

White type IV casts and white intensive wax (the so-called "white-on-white approach"), a Lecron no. 5 wax carver and an electric wax pencil are required (Fig 5-8a). ***Above all, the key element of a wax-up is the precise knowledge of the strategic elements of tooth anatomy, which can be learned by the systematic observation of natural teeth (see chapter 2).***

The following elements will provide essential guidance for the wax-up: *(1)* permanent inspiration by looking at **natural dentition casts**; *(2)* when appropriate, those reference casts can be presented to the patient in order to get a sense of their own sensitivity and preferences; *(3)* old photographs of the patient's previous smile; and *(4)* current portrait photographs and photographs of various degrees of smile.



The wax-up starts with the basic tooth shapes, which are defined by the vertical labioproximal transition line angles. Because of their prominence, these ridges are the first to wear off and therefore constitute the first element that should be restituted by the addition of wax on the diagnostic cast (Figs 5-8b to 5-8x and Table 5-2).

The position and arrangement of these lobes will be determinant for the definition of tooth form. The differential placement and contouring of the transition line angles can easily generate the illusion of a shorter tooth or wider tooth. A special section related to these special effects has been included in chapter 6 (see Figs 6-68 and 6-69).

A secondary step of the wax-up is to recreate the superficial developmental lobes and eventual horizontal components of surface topography resulting from the line of growth. The texturing process is very similar to that described in chapter 3 for composite resin restorations (see Fig 3-50). Table 5-2 provides detailed step-by-step instructions for anterior maxillary wax-up with key anatomical references.

**FIG 5-8a Materials for additive wax-up.** S-U-Diagnostic Wax-A intensive-white no. 60 202 2 (Schuler Dental), a Lecron no. 5 wax carver *(insets)*, a generic electric wax pencil, a scalpel blade #11, and a soft art brush #10 constitute the basic materials for wax-ups. This specific white intensive wax is ideal for wax-ups—totally opaque, with excellent modeling and carving properties—but it cannot be used for the lost wax technique.

**FIG 5-8 Step-by-step analog wax-up.** *(b)* The baseline view of the smile reveals existing ceramic veneers on the lateral incisors, old composite resin restorations mesial to the canines, and shortened central incisors. The lower lip line, cusp tip line, and interdental contact line display good cohesiveness, but the incisal edge line reveals that the central incisors are 1 to 2 mm short *(arrows)*. *(c)* The same discrepancy is visible on the diagnostic cast. *(d)* In addition, the central incisors display an inverted labial architecture with central lobes more prominent than the mesial and distal lobes *(arrows)*. Compare the shape of the dotted line *c* with that in *p*.



t.me/Dr_Mouayyad_AlbtousH




5-8a

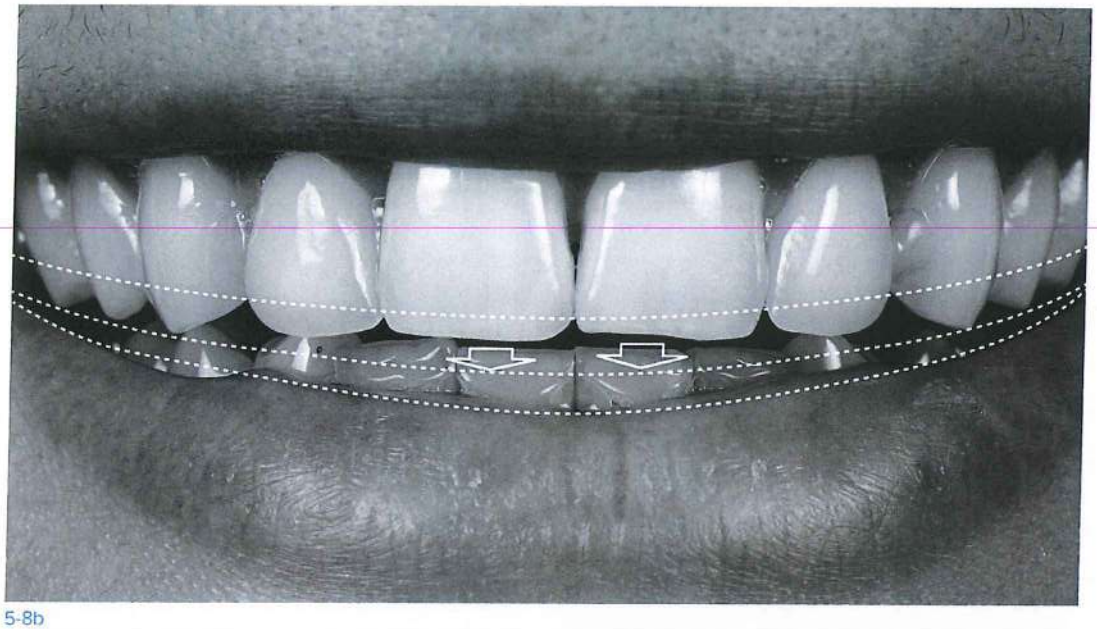

5-8b

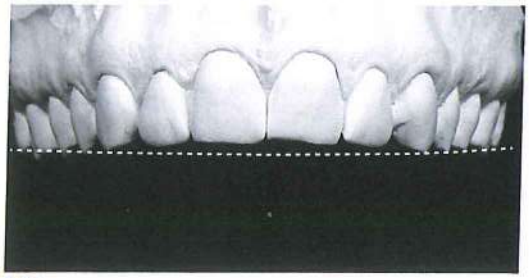

5-8c

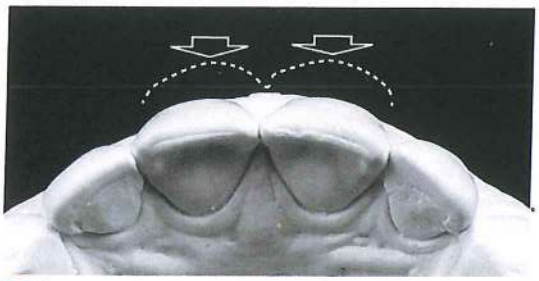

5-8d



t.me/Dr_Mouayyad_AlbtousH



5-8e



5-8f



5-8g



5-8h

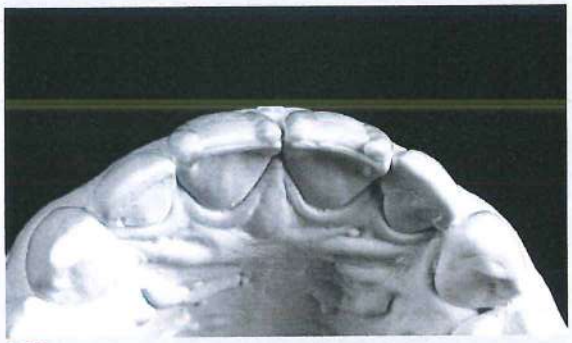

5-8i

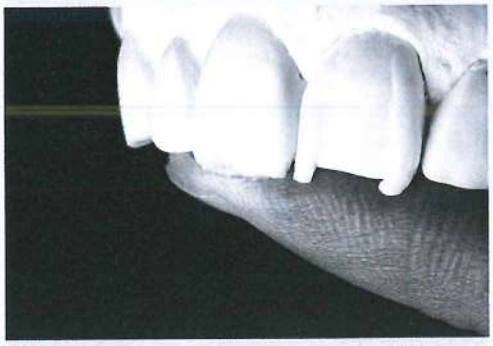

5-8j

**FIG 5-8** *(cont) (e to i)* The wax-up starts with the redefinition of labioproximal transition line angles. *(j)* The index finger is pressed onto the palatal surface and used as a guide to elongate the line angles and build the missing part of the incisal edges. *(k)* From the lingual view, the incisal edge appears to be less than 50% of its final thickness because only the labioincisal edge is formed at this stage. *(l)* The incisal length is cohesive with the cusp tip line, and the basic morphology is present. *(m)* The next step is to fill the gap between the mesial and distal transition line angles. *(n and o)* Placement of the central lobe facilitates this step. *(p)* Subsequently, most morphologic features described in chapter 2 (see Fig 2-5) should be present.



t.me/Dr_Mouayyad_AlbtousH

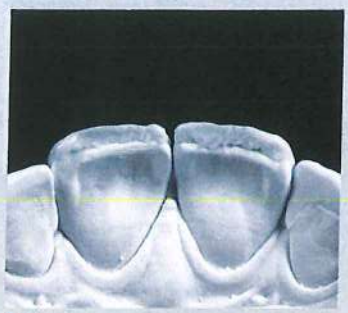

5-8k

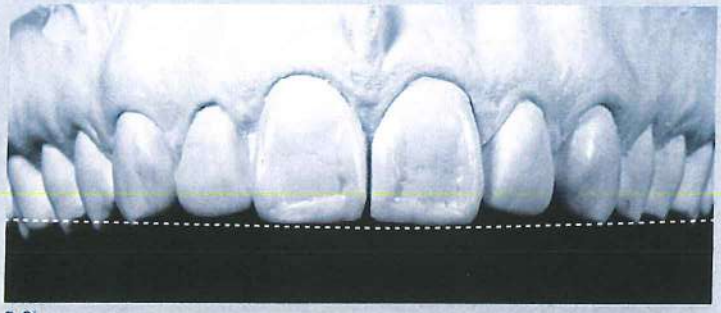

5-8l



5-8m

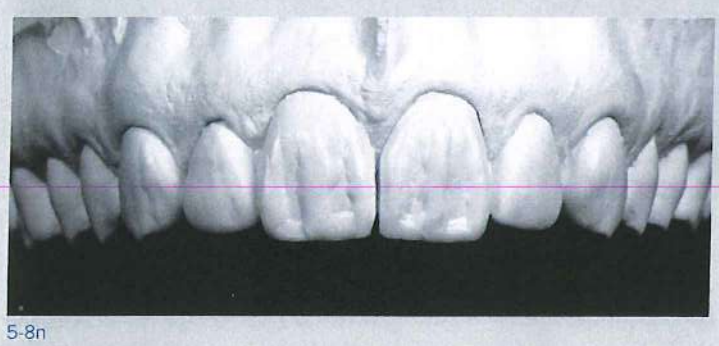

5-8n



5-8o

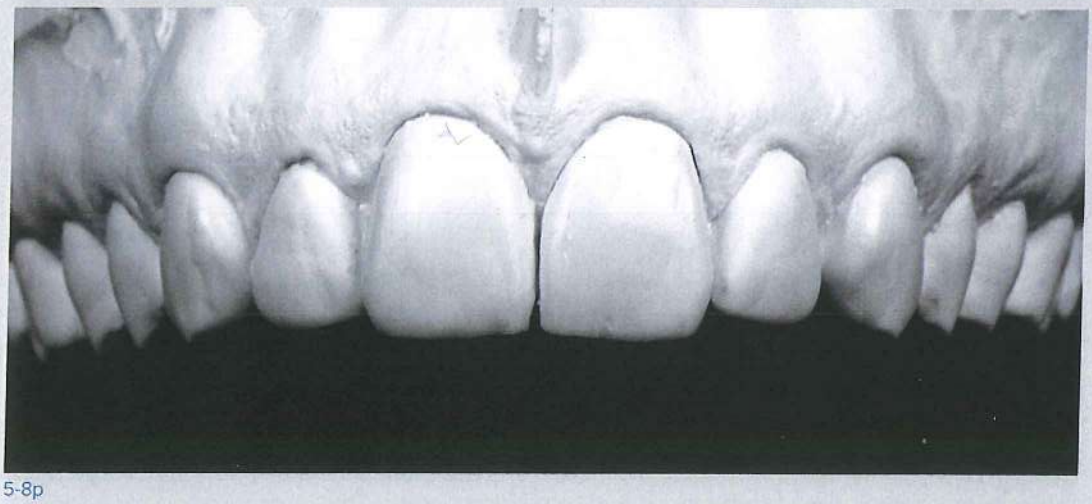

5-8p



t.me/Dr_Mouayyad_AlbtousH

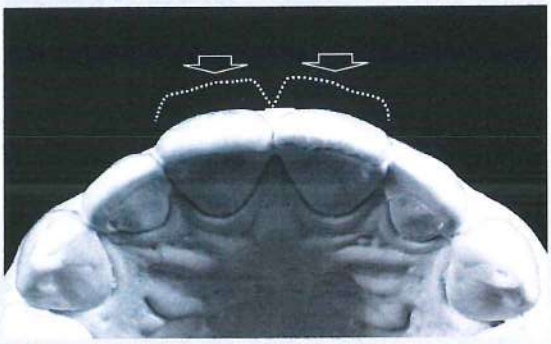

5-8q



5-8r





5-8s



5-8t

**FIG 5-8** *(cont) (q and r)* The incisal edge is completed by the addition of wax to create the linguoincisal side. Note the new labial surface architecture *(dotted line in q;* compare to *d).* The wax-up is almost complete *(s,* overlay image shows baseline), and the last step is completed by creating the surface texture *(t to x).* The mock-up (see Fig 5-10) will reveal whether these new shapes are compatible with the patient's expectations, comfort, function, and esthetics.


t.me/Dr_Mouayyad_AlbtousH

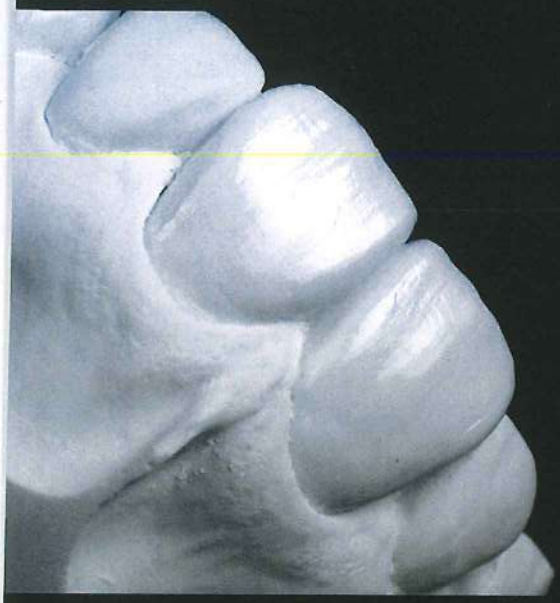

5-8u

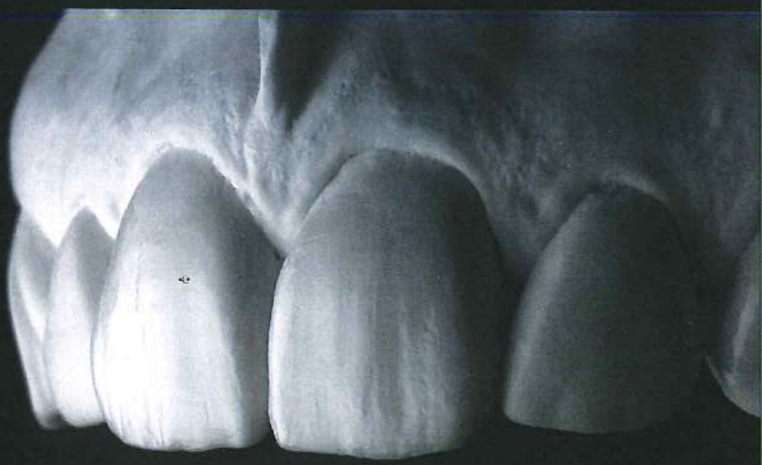

5-8v



5-8w



5-8x



t.me/Dr_Mouayyad_AlbtousH

**TABLE 5-2** Detailed instructions for analog wax-up (same steps as in Fig 5-8)

| Step | Instruments and methods | Notes |
|---|---|---|
| Material preparation | Instruments required:<br>• Pencil<br>• Scalpel blade #11<br>• Electric waxer with tips<br>• Lecron no. 5 wax carver<br>• White intensive wax cone (Schuler)<br>• Diagnostic casts (white type IV stone) | Electric waxer:<br>Only short small PKT and short large PKT tips are needed. |
| 1. Adjust the temperature of the electric waxer. | Turn on the electric waxer at the equivalent of about 70°C–90°C/158°F–194°F. Dip the tip straight into the wax, lift, and rotate: The drop of wax should stay liquid and move back and forth on the tip, with no smoke visible. | To load a small amount of wax, dip the tip only. To load larger amounts of wax, dip horizontally (side of instrument). |
| 2. Mark the tentative length on antagonistic teeth. | With a pencil, mark each antagonistic tooth with a dot corresponding to the anticipated length of each maxillary tooth depending on the amount of existing wear/biocorrosion and lower lip line (see Fig 2-13a). | In the case of discrepancy between the occlusal plane of posterior teeth and the incisal edges, the new length of incisal edges should correct this problem. |
| 3. Create the lobes ("fingertip-assisted"). | Drop by drop ("dip and draw" technique), place each labial lobe, with about 1-mm width and 0.5-mm thickness. For each lobe, use the index finger as a support on the lingual surface to extend the lobe incisally (see Fig 5-8j).<br>▶ **Both centrals first, then both laterals, then both canines; check the length of lobes for each pair.**<br>Use your knowledge of natural tooth anatomy (see chapter 2) as well as **direct comparison with models of natural dentitions**. Key elements:<br>• The general labial curve of lobes aims at the mandibular gingival margin (three sagittal planes; see Figs 2-5d and 2-5m).<br>• Torsio dentis (see opposite page and Figs 2-5d and 2-5f).<br>• Convex smile line (cohesiveness with lower lip line; see Fig 2-13a). | The thickness of lobes may vary depending on the amount of existing wear/biocorrosion. At the end of this step, you should be able to "visualize" and imagine the final shape of each tooth and the harmonious occlusal plane. |

*(continues on page 476)*

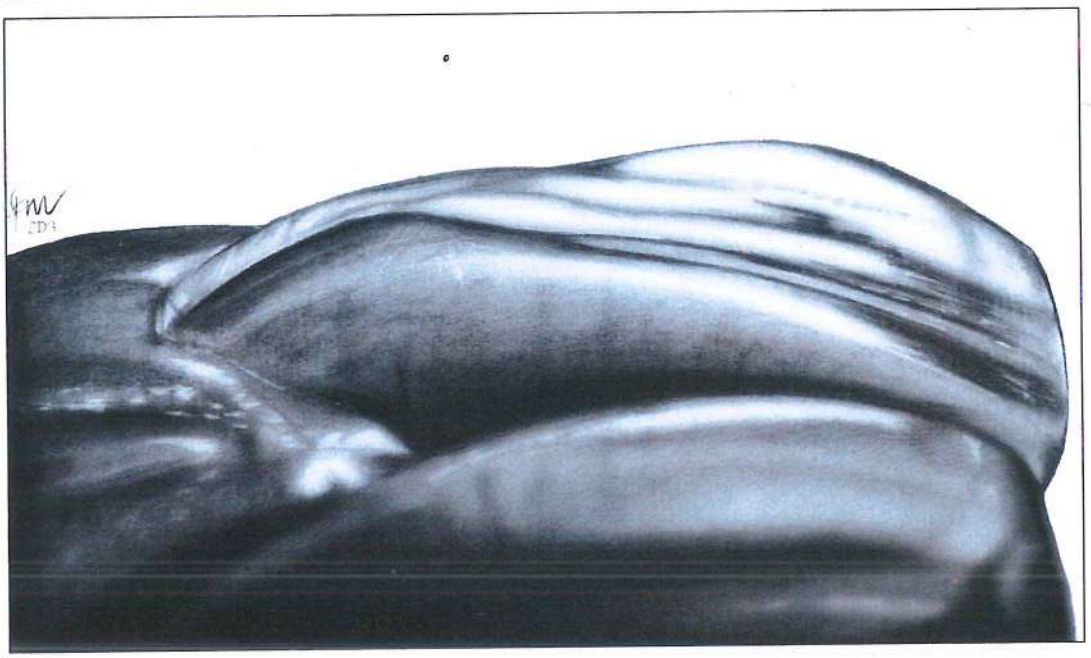



t.me/Dr_Mouayyad_AlbtousH

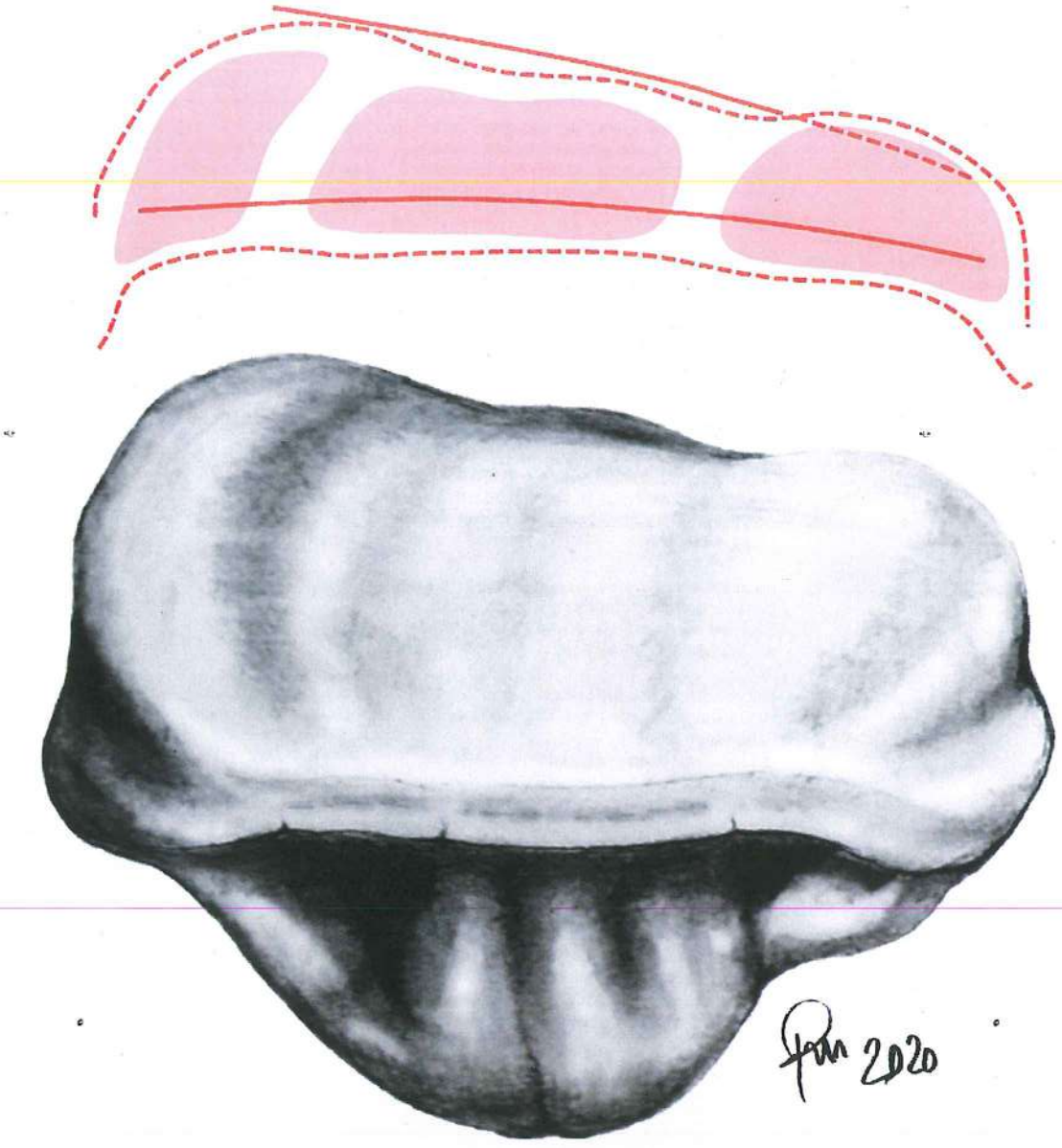

Incisor lobes and TORSIO DENTIS





t.me/Dr_Mouayyad_AlbtousH

**TABLE 5-2** *(cont)* **Detailed instructions for additive wax-up (same steps as in Fig 5-8)**

| Step | Instruments and methods | Notes |
|---|---|---|
| 4. Define incisal and cervical "belts" (incisors only, optional). | Drop by drop (using the "dip and draw" technique), link the lobes with a horizontal incisal belt of wax at about 1-mm width and 0.5-mm thickness and then with a cervical belt (slightly thinner). | The labial aspect of incisors is not flat but presents at least three main planes (see Figs 2-5d and 2-5m). |
| 5. Fill the "windows" of space between the lobes and belts. | Starting at the incisal edge (use fingertip for incisal part), establish continuity between the vertical and horizontal lobes for each tooth. **Do not touch the existing transition line angles, and respect existing landmarks defined by the lobes and belts!** | The labial surface should not feature any concavities after the procedure. Slightly smooth this surface with a Lecron no. 5 knife if necessary to remove irregularities left by the wax pencil. |
| 6. Thicken the incisal edge at the lingual aspect. | Add wax to support the lingual aspect of the incisal edge in order to obtain about 1.0 to 1.5 mm of labiolingual thickness (see Fig 5-8r). Check the incisal edge length with the antagonist model (pencil marks). Establish continuity with the lingual surface with a Lecron no. 5 knife (use existing lingual surface of stone as a guide). | |
| 7. Establish continuity with the interdental surface. | Fill in the labial interdental surfaces with hot wax (roll wax on tip before letting it touch the stone). Sharpen each embrasure with a scalpel blade #11 (interdental contact line). | |
| 8. Create final form and surface texture. | In three steps, use the Lecron spoon to create:<br>1. Vertical labial lobes and "V" shapes in between lobes.<br>2. Horizontal texture within the incisal "V" grooves.<br>3. Horizontal texture across the labial surface. | This technique is similar to composite resin finishing. Remember that labial lobes are not cylindric but tapered (see Fig 2-5g). |
| 9. Evaluate function. | Using the articulator, check that appropriate incisal guidance and canine guidance have been established; generate functional wear by gently simulating mandibular movements. The amount of simulated wear must be consistent with the remaining dentition wear (see Fig 2-12c). Check the incisal embrasures' inverted "V" shapes (see Fig 2-12d). | Final adjustments (esthetic and functional) are always carried out in the mouth, in the form of the mock-up and the "real" articulator (ie, the patient). |

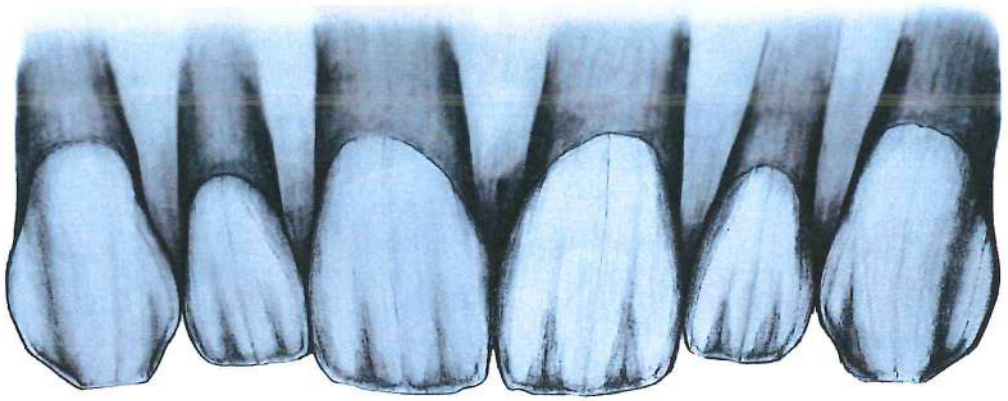



t.me/Dr_Mouayyad_AlbtousH

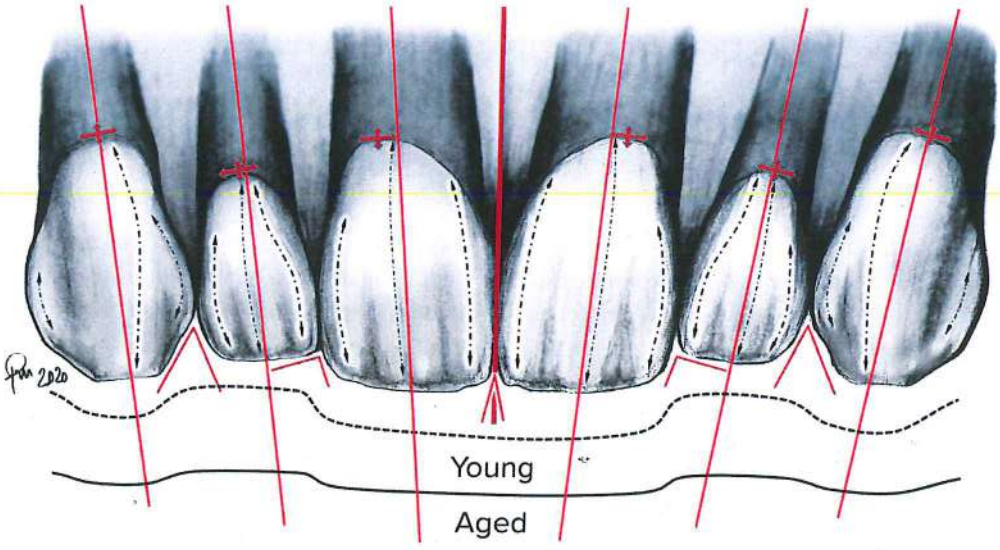


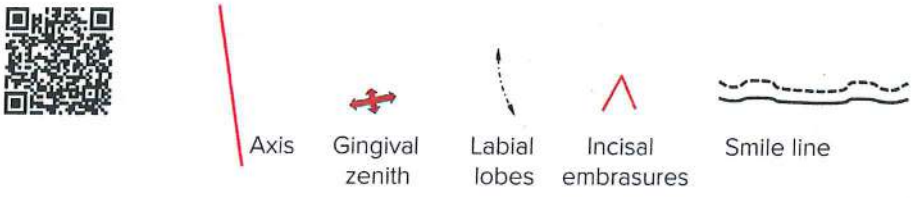


**Basic features of maxillary anterior teeth (see also chapter 2):**

| Central incisors | Lateral incisors | Canines |
|---|---|---|
| The mesial outline can be straight or only slightly convex. | Close resemblance to central incisors (similar basic outline and transition line angles), which they supplement in function. They differ mainly by the following:<br>• Reduced size<br>• More rounded mesioincisal angle<br>• Labioproximal transition line angles with more apical convergence | The mesial outline is slightly convex and resembles that of the lateral incisor. The mesial transition line angle is well developed in the form of a small mesial lobe. |
| The distal outline is more convex (compared to the mesial), and its curvature and inclination can vary significantly according to the typal form of the tooth (square, ovoid, triangular). | | The dominant lobe is the central lobe, tapered and curved toward the mesial to converge apically with the mesiocervical protuberance (this curvature is opposite to the incisor central lobes; see Figs 2-6l and 2-6m). |
| Torsio dentis: The mesial line angle is prominent also cervically, while the distal line angle converges into the root distocervically. | | The distogingival outline of the crown is flat or concave and resembles that of the premolar. |
| The distoincisal angle is more rounded than the mesioincisal angle. From a distobuccal view, the lingual escape route of the lingual fossa should be visible (young teeth only; see Figs 2-5h and 2-5i). | | The incisal outline is marked by the cusp tip, which is slightly mesial to the center of the root (unworn tooth). In the worn canine, the distal slope of the tip is convex and well curved and differs from the shorter and concave mesial slope. |
| The incisal outline can be irregular or rounded but usually becomes more regular and straight because of functional wear (see Fig 2-5k). | They show the greatest variation in form (eg, left lateral incisor can differ from right lateral incisor). | The canine is the longest tooth in the mouth (about 27 mm for mandibular canine with root). It is characterized by a series of curves or arcs thicker labiolingually due to the increased development of the cingulum compared to that of the incisors. This special anatomy (wedge shape) seems to offset functional forces and provides this tooth with a unique ability to resist nonaxial loads. |


t.me/Dr_Mouayyad_AlbtousH

# 5.6 DIAGNOSTIC MOCK-UP

Predicting the treatment outcome is essential when planning a substantial esthetic rehabilitation.[1,3–6,9–14] The diagnostic analysis is the foundation of the future therapy. Nevertheless, this should remain a simple and rational procedure. If subtle changes are considered, it is advisable to communicate with the patient using concrete devices in order to avoid even the slightest misunderstanding.

At this stage of the diagnostic approach, the new volume of teeth must be approved by the patient, resulting in total agreement on the definition of tooth shape, size, and length. In traditional prosthodontics (full crown coverage), preliminary tooth preparation usually precedes the realization of the diagnostic template, which is represented by the provisional restoration itself.[17,32,33] Such treatment planning is not possible with bonded restorations, especially indirect porcelain veneers.

> Because of the reduced thickness of the laminate and intrinsically conservative approach, the tooth preparation itself must be guided by the final volume of the restoration. The in vivo evaluation and full approval of the diagnostic template by the patient should therefore precede tooth preparation procedures.

The simplest method involves fabrication of a bonded acrylic template directly in the patient's mouth using a dentin shade of polymethyl methacrylate (PMMA) resin molded on the unprepared tooth surfaces with a silicon index of the wax-up. The procedure can be very basic and cost-effective (see Fig 5-4b and 5-11) or involve more sophisticated effects (see Figs 5-10, 5-12, and 5-13). Subsequently, the patient should be able to test-drive this mock-up for comfort, function, and esthetics. A highly accurate silicon index can be fabricated by firmly applying the silicon material onto the model. A Shore A hardness of 80–85 is recommended (Fig 5-9). The silicon matrices should present an optimal stiffness, which facilitates handling and repositioning and, in turn, should generate only minor excess resin (Figs 5-9d and 5-9e). Three different silicon indexes are fabricated in a specific order (Fig 5-9c) and each with a specific purpose.

***It is recommended to make a slight gingivoplasty of the stone cast (0.5-mm reduction/bevel of the gingival margin surrounding the wax-up) before fabricating the third silicon index. This will generate a light compression of the gingiva during the application of the resin and facilitate subsequent excess removal (Fig 5-9d).***

**FIG 5-9 Silicon indexes.** Stiff (Shore A hardness 80–85) and accurate silicon indexes must first be obtained by adapting the putty material onto the wax-up. *(a to c)* Indexes are fabricated in a specific order and trimmed to obtain a specific design for a specific purpose: Index no. 1 involves only the lingual surfaces and incisal edge wear facets (it stops at the labioincisal edges), index no. 2 involves mainly the labial surfaces and occlusal surfaces of two posterior teeth (** = occlusal stops) and is sectioned horizontally at the junction between the incisal and middle third of each tooth, and index no. 3 involves both labial and lingual surfaces and occlusal surfaces of two posterior teeth (** = occlusal stops). Index no. 3 can be discharged on the lingual surfaces *(arrow)* of the teeth to be restored by removing the gingival third of the index (this space will be occupied by periphery wax in the mouth; see Fig 5-10d). Index no. 3 is used to apply the PMMA resin. *(d and e)* When it is done properly from a recent silicon impression and positioned correctly in the mouth, resin flashes on the gingiva are paper-thin and can be easily peeled off. This is a very good sign that the index was seated 100%. This advantage of checking the seating accuracy is lost with some other techniques suggesting to scallop the index to the level of the gingiva.





t.me/Dr_Mouayyad_AlbtousH

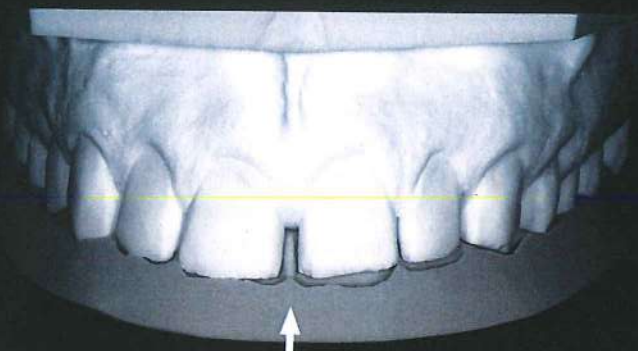

5-9a



5-9b

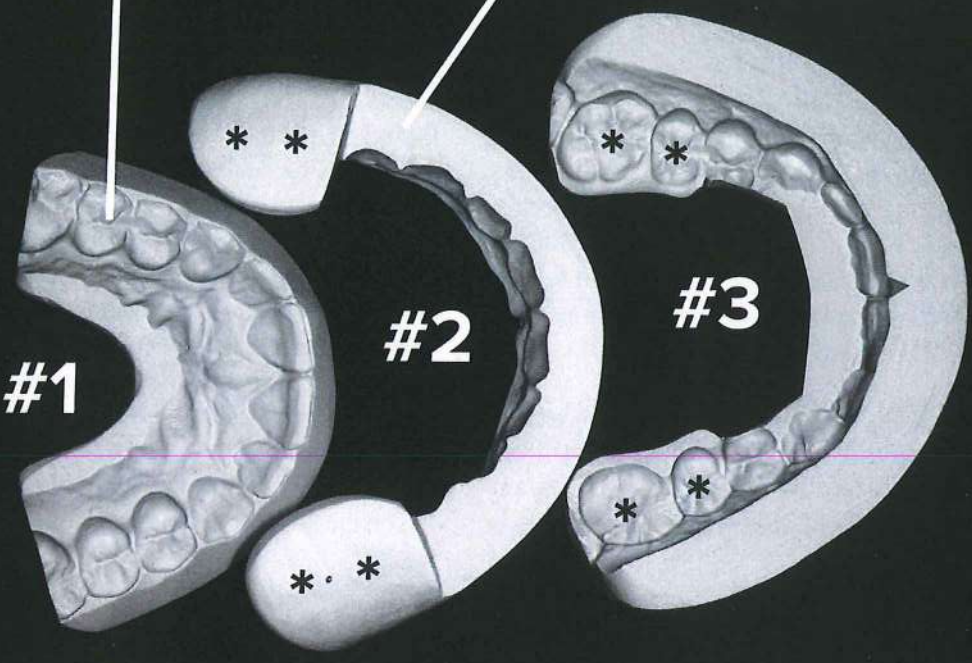


5-9c



5-9d

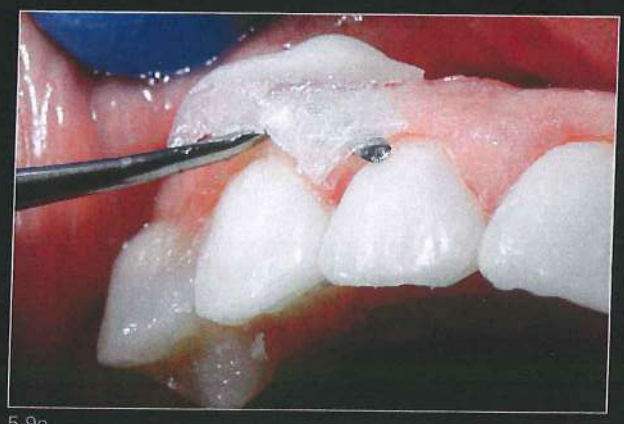

5-9e



t.me/Dr_Mouayyad_AlbtousH

A common situation must be pointed out. When looking at the template for the first time, the patient is likely to complain about the excessive tooth volume. This reaction is normal and understandable because the process leading to wear and biocorrosion is slow and extends over years; changes in tooth length and shape take place progressively, without generating sudden modifications in the patient's smile. When this long degenerative process is suddenly counteracted by an instant procedure (the mock-up itself) involving major changes in the smile design, the patient can be surprised. The person must therefore be prepared and informed that an objective esthetic assessment requires a prolonged clinical trial of several days, even several weeks. Accordingly, the unaltered mock-up is left intraorally for trial during 1 to 2 weeks. For a safe and efficient test drive, the template should be bonded by enamel spot-etching or should be allowed to lock by the shrinkage of the PMMA resin (Fig 5-10). At the next appointment, the patient generally feels more comfortable and will likely discuss eventual modification with much more moderation.

*Remodeling of the lip by the mock-up has been observed in some cases (see Fig 5-11h),* ***which emphasizes the importance of respecting the chronology and avoiding immediate editing of the mock-up.***

The method is not time-consuming. Hence, when indicated, major modifications of the initial diagnostic study can be carried out (new wax-up) and integrated into a new mock-up.

***Photographs of the mock-up should be presented to the patient for discussion rather than only looking at the mirror.*** Mirrors display an inverted image of the smile, which may lead to misunderstanding between the clinician and the patient regarding esthetic perceptions (see section "Beware of the mirror" in chapter 2, page 140).

The actual tooth preparations will only be performed after the patient's formal approval. The mock-up can also be prepared indirectly in the dental laboratory, which allows for more sophisticated results and characterizations (see Fig 5-13c). For both direct and indirect techniques, it is recommended that a dentin shade of PMMA resin be used instead of composite resin or stiffer bis-acryl materials that would be too brittle. PMMA resins feature optimal properties for mock-ups because of their elasticity and favorable handling properties. Table 5-3 provides detailed step-by-step instructions for anterior maxillary mock-ups. A significant advantage of powder/liquid PMMA is the ability to generate/mix a wide range of colors and opacities depending on the need for masking (Table 5-4).

**FIG 5-10 Mock-up step by step.** The same case appears in Figs 5-8 (wax-up) and 3-50 (final restorations). *(a)* First, the shade of the central incisors is determined using the Classic Vita shade guide. The teeth appear brighter than A1/B1. *(b and c)* Silicon indexes no. 1 and 2 are placed to confirm additive clearance for the mock-up. *(d)* A lingual barrier of periphery wax is applied to the gingival half of the teeth; perfect seating of the silicon index no. 3 must be confirmed (lingual wax must not impinge). *(e)* A partial enamel etching will provide additional stability to the future mock-up. Finally, a thick layer of Vaseline must be applied to the neighboring teeth and surrounding soft tissues to prevent adherence of the PMMA resin to existing restorations and gingiva. *(f)* The silicon index no. 3 is then filled partially with mixed resin (New Outline dentin by Anaxdent); 10% of "white dentin" and 10% of "High Value" enamel powders were added to dentin A1 powder to get a theoretical "A0" shade. The mixed powders should be added to the liquid monomer (not the opposite) until a runny consistency is obtained (drops falling from mixing spatula). *(g)* After pouring into the silicon index, the resin surface is allowed to dry for about 1 minute until the surface becomes dull and opaque.



t.me/Dr_Mouayyad_AlbtousH

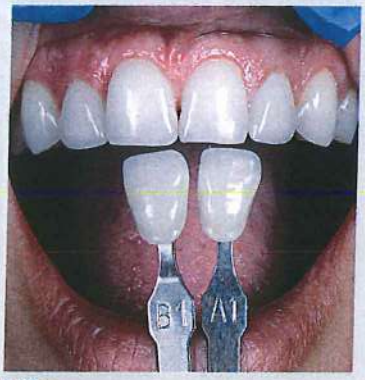


5-10a

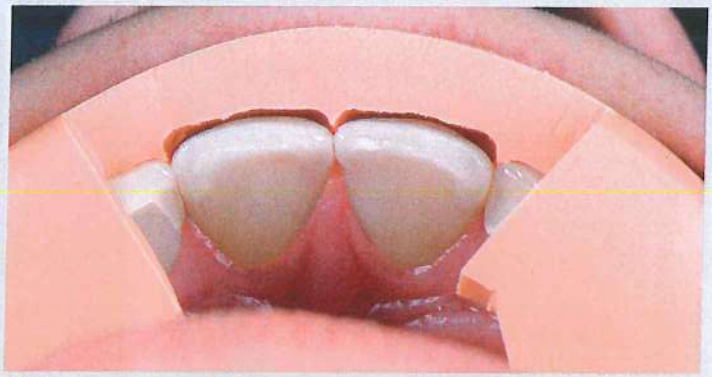

5-10b



5-10c

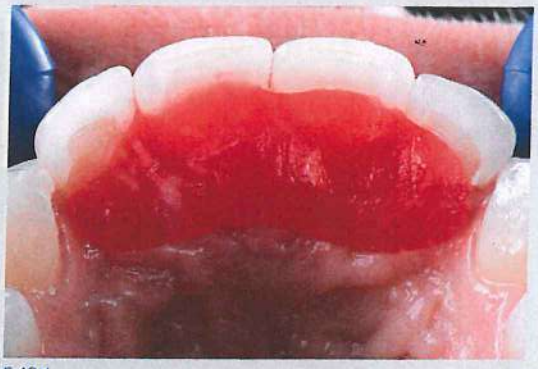

5-10d

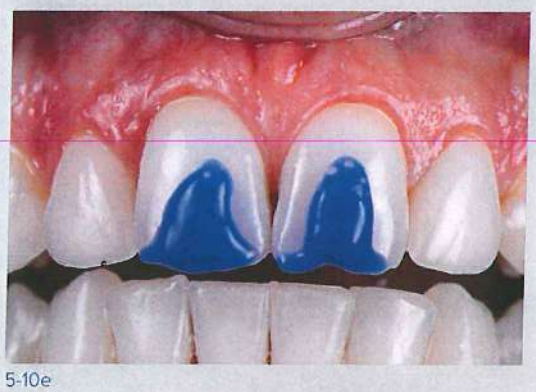

5-10e




5-10f

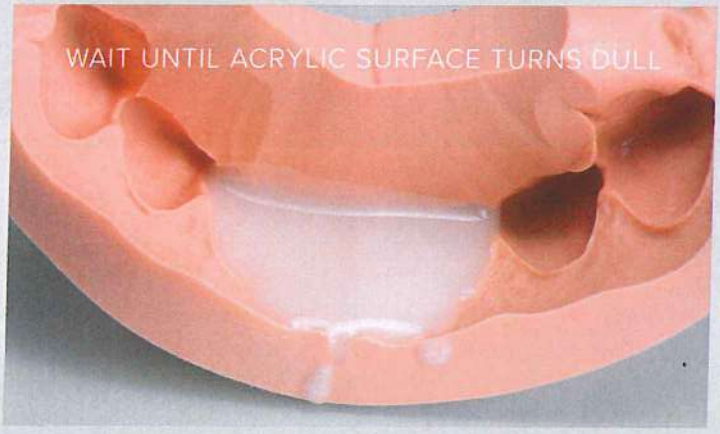


5-10g



t.me/Dr_Mouayyad_AlbtousH

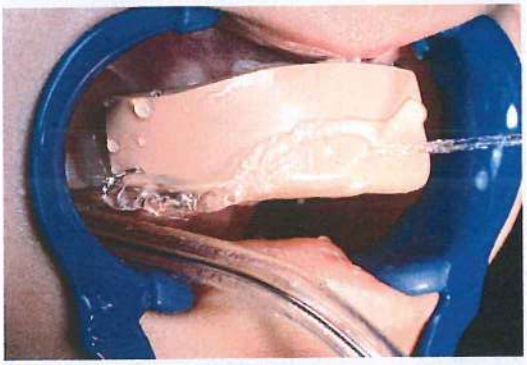

5-10h



5-10i

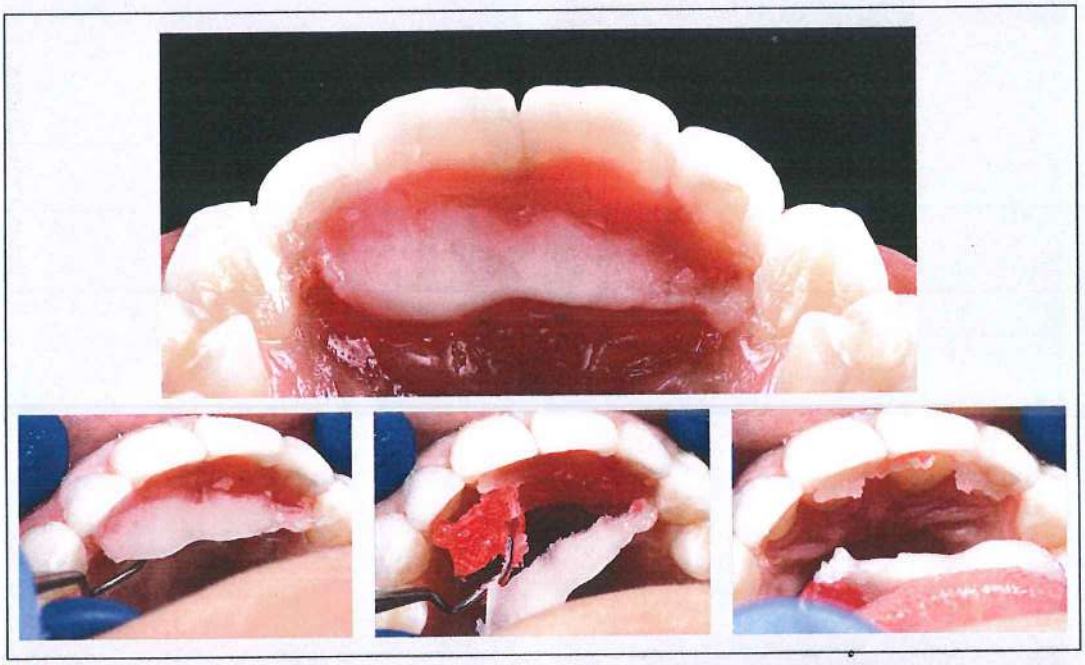

5-10j



5-10k


t.me/Dr_Mouayyad_AlbtousH

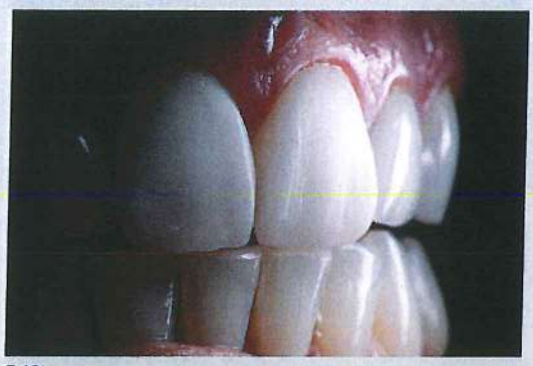

5-10l

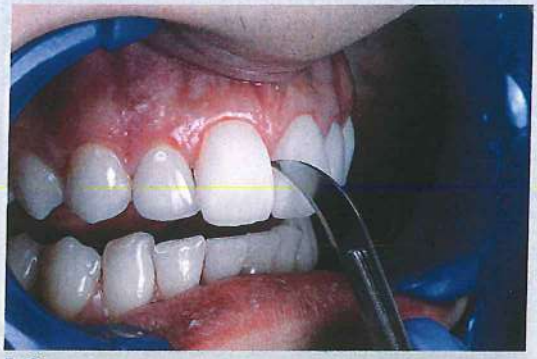

5-10m



5-10n

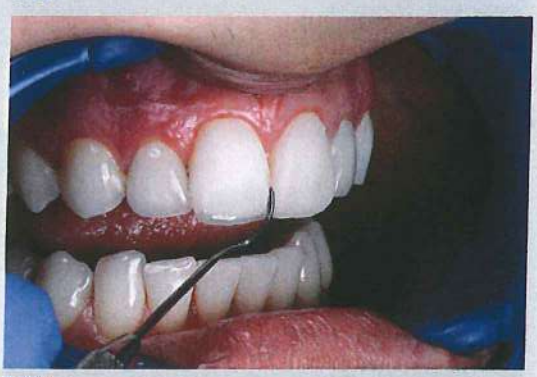

5-10o



5-10p



5-10q

**FIG 5-10** *(cont) (h)* The index is then slowly applied to the teeth and firmly maintained in position until the resin is completely set (the mock-up is usually thin and would be deformed by premature removal), the operatory field being cooled with abundant rinsing. *(i)* The resin covers the central incisors, but there are paper-thin excesses all over. *(j)* The lingual wax barrier facilitates removal of excesses. *(k)* A scaler is used to peel off the thin layer of remaining resin on neighboring surfaces, teeth, and gingiva. *(l)* The raw mock-up is an exact copy of the wax-up. There are three steps in the surface characterization of the mock-up: *(1)* Application of a thin brown line to the interdental contact area *(m and n)*; the tip of a scalpel blade is used to infiltrate only the gingival embrasure. *(2)* Application of incisoproximal effects: One drop of blue resin, one drop of lavender resin (Kerr Kolor + Plus), and one drop of glazing resin (Skin Glaze by Anaxdent) are mixed and painted on with an explorer *(o)*, then smudged with a brush *(p)* and light-polymerized *(q and r)* before the last step. *(3)* Glazing is performed *(s and t)* with clear resin (Skin Glaze).



t.me/Dr_Mouayyad_AlbtousH



5-10r

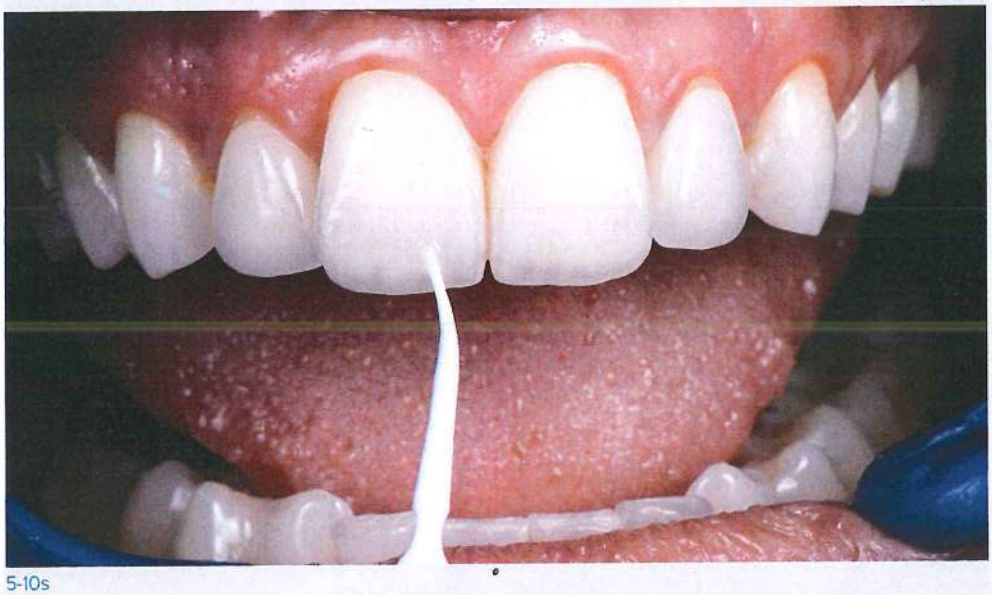

5-10s



5-10t

**FIG 5-10** *(cont)* The polymerized effect resins *(r)* are covered with a protective layer of clear glazing resin *(s,* Skin Glaze), which is polymerized in turn and covered with glycerin jelly followed by additional exposure to light (10 seconds per surface). *(t to w)* The same-day images reveal a lifelike simulation, allowing the patient a true test drive of function, comfort, and esthetics. Note the beautiful twist of the labial surface *(arrows in u, right).* The overlay image in *w* is the preoperative view for comparison. The wax-up of this case is presented in Fig 5-8 and the definitive restorations in chapter 3, Fig 3-50.


t.me/Dr_Mouayyad_AlbtousH

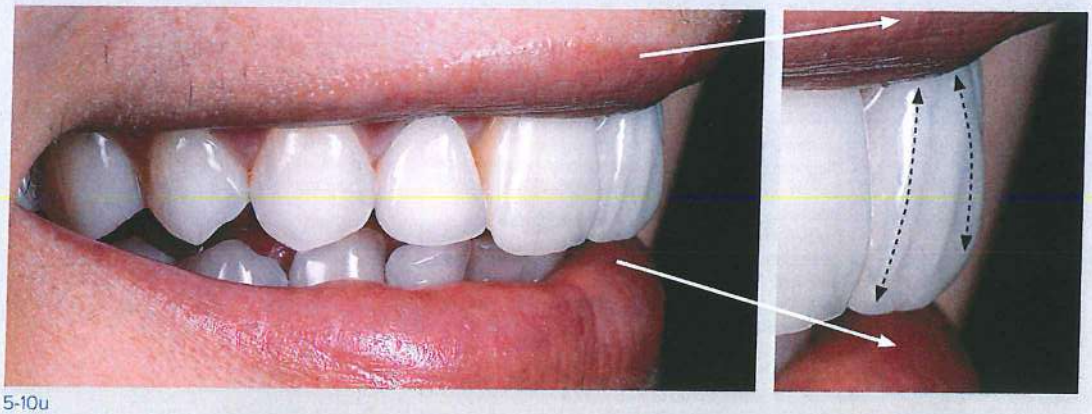

5-10u



5-10v

MOCK-UP



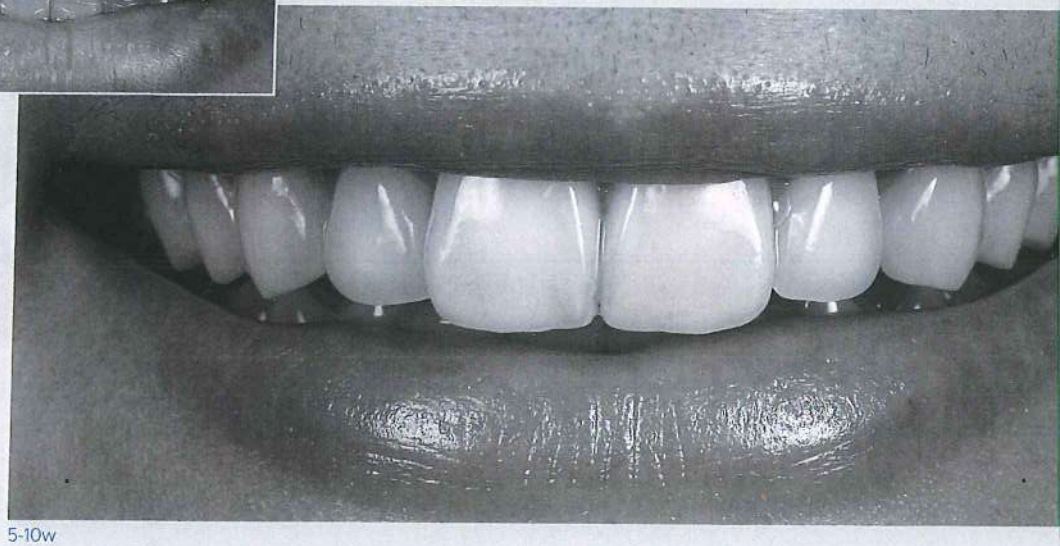

5-10w



t.me/Dr_Mouayyad_AlbtousH

**TABLE 5-3** Detailed instructions for additive mock-up (same steps as in Figs 5-9 and 5-10)

| Step | Instruments and methods | Notes |
|---|---|---|
| Material preparation | Instruments required:<br>• Diagnostic cast with additive or digital wax-up<br>• Silicon putty (Shore A hardness 80–85) for three indexes<br>• Scalpel blade #11<br>• Colorless rope positioning wax<br>• Vaseline<br>• PMMA resin (New Outline Dentin, White Dentin, Enamel HV)<br>• Dappen dishes (2) and mixing spatula<br>• Vivapad (Ivoclar)<br>• Kolor + Plus kit (Kerr; Blue, Lavender, Brown, White)<br>• Skin Glaze and glycerin jelly<br>• 000 sable brushes | A pressure pot can be used to increase precision and hardness of silicon material. |
| 1. Fabricate the silicon indexes. | Clean the wax-up surface with alcohol and dry. Three consecutive indexes are fabricated by mixing equal amounts of silicon putty. Homogeneous mixing is obtained using the "fast-folding technique" and uniform thickness using the palm of your hand to apply it to the cast. Fabricate three consecutive indexes (see Fig 5-9c):<br>• **No. 1: Incisal clearance index:** Use only 1/3-spoon of the catalyst and base. Shape the putty in the form of a ball and apply it to the lingual surfaces. Do not overlap the incisal edge but include incisal wear facets/canine tip.<br>• **No. 2: Labial clearance index:** Use only 2/3-spoon of the catalyst and base. Shape the putty in the form of a "short sausage" and apply it to the labial surfaces with the palm of the hand. Fold it slightly to cover the occlusal surface of premolars.<br>▶ After setting: Using blade #11, remove any labial excess (2 mm from the gingival margin of teeth) and make a horizontal cut to eliminate the incisal third.<br>• **No. 3: Mock-up index:** Use a full spoon of the catalyst and base. Shape the putty in the form of a "cylinder" and apply it to the incisal edges with the thumb and index fingers placed in a "V."<br>▶ After setting: Using blade #11, remove any labial excess (2 mm from the gingival margin of teeth) and make a horizontal cut to eliminate the lingual gingival half. Also make a small notch to identify the labial midline. | Appropriate mixing should result in total absence of "colored streaks" in the material.<br><br>Fabricating the silicon index in two increments—the so-called *dual-layer technique* (with the first increment being pushed tightly against the model by the second increment)—will result in more accurate indexes.<br><br>A minimum material thickness of 7 mm is critical to get a stiff silicon index.<br><br>It is recommended to make a slight gingivoplasty of the stone cast (0.5-mm reduction/bevel of the gingival margin surrounding the wax-up) before fabricating the third silicon index. This will generate a light compression of the gingiva during the application of the resin and facilitate subsequent excess removal (see Figs 5-9d and 5-9e). |
| Silicon indexes: | <br>#1 #2 #3 | |



t.me/Dr_Mouayyad_AlbtousH

| | | |
|---|---|---|
| 2. Test the seating of the silicon indexes. | Check individually that each silicon index is completely seating on the original wax-up cast. A tight fit can be confirmed at cross-sectioned premolar/molar occlusal surfaces and at a horizontal section with labial attached gingiva. | |
| 3. Check clearances in the mouth. | Using silicon index no. 2, check that a minimum of 0.1 to 0.2 mm of space is available (see Fig 5-10b). Using silicon index no. 1, do the same control incisally. | Some clinical cases will call for a subtractive mock-up requiring preliminary tooth reduction (see Figs 5-11 and 5-12). |
| 4. Apply barriers. **VERY IMPORTANT!** | Place periphery rope wax on the lingual surfaces to fill any space between the mock-up index and gingiva (see Fig 5-10d). Make sure this does not prevent the index from fully seating! Test the seating and remove eventual excesses of wax at the incisal half of lingual surfaces.<br><br>Apply a thick layer of Vaseline to gingiva, premolars, and lingual surfaces. | If necessary for additional retention of the mock-up, spot-etch enamel surfaces. |
| 5. Prepare the acrylic resin. | For six teeth, fill 70% of a small dappen dish with resin powder mix (see Table 5-4 for types of mixes) and another identical dish half filled with monomer liquid. Drop small amounts of powder into the liquid (let the liquid infuse into the powder) and gently mix with slow horizontal movements. Avoid tossing. Add powder until a very light creamy consistency is obtained; the resin must still be able to make drops when lifting the mixing spatula. | The resin should be preferably too fluid rather than too "dry."<br><br>Please refer to the table on the next page for patient mixes depending on mock-up thickness and need for masking. |
| 6. Fill index no. 2 with PMMA resin and insert on the teeth. | From a vertical distance of 4 to 5 inches, pour resin into the incisal edges of the silicon index until the teeth are filled completely. When resin becomes slightly dull at the surface, slowly insert it into the mouth. Make sure that the notch on the index is aligned with the midline. Apply strong pressure to the occlusal surfaces of premolar areas and wait for 3 to 4 minutes before removing the index. | Intraorally, you can check resin setting by poking excesses on the labial aspect. |
| 7. Clean up any resin flashes and check the occlusion. | Using a Composculp blue instrument, gently peel off all excesses of resin on the gingiva, lingual surfaces, and premolars (see Figs 5-9d and 5-9e). Excesses on the labial gingiva should be paper-thin (see Fig 5-12m). Use blade #11 to refine the interdental contacts and embrasures. No excesses or flashes should be left on the gingiva, premolars, and lingual surfaces. Adjust the occlusion if necessary. | Thick excesses on labial gingiva result from incomplete seating of the index (likely from the use of an altered or outdated model for the wax-up); in this case, the mock-up must be redone. |
| 8. Stain and glaze. | Dispense tiny amounts of Kolor + Plus colorants and Skin Glaze in Vivapad:<br>• **Brown:** Place with #11 blade at the gingival embrasure as a "extension" of the papilla. Brush off excesses. Brown color should never reach the incisal edge!<br>• **Blue/lavender mix:** Smear with a small brush at the incisoproximal edge to simulate translucency (see Fig 5-10s).<br><br>**Air-blocking:** Light-polymerize colorants for 10 seconds per tooth, then glaze the entire surface of the mock-up with a layer of Skin Glaze. Light-polymerize again. Cover with glycerin jelly and light-polymerize again. Rinse with water. | Colorants are always diluted in glazing resin (one drop of each); otherwise, they are too thick.<br><br>Clean brushes carefully before using for the next color, or use disposable brushes.<br><br>**An important rule when coloring: "Less is more."** |



t.me/Dr_Mouayyad_AlbtousH

**TABLE 5-4** Mock-up powder mixes (New Outline) according to thickness and need for masking

| | | | | |
|---|---|---|---|---|
| **Normal-opacity mock-up** | | | | |
| eg, target A2 | Regular thickness | 100% dentin A2 | | |
| eg, target A0 | Regular thickness | 80% dentin A1 | + | 10% WD 10% HV |
| eg, target A2 | High thickness | 80%–90% dentin A2 | + | 10%–20% HV |
| **High-opacity mock-up** | | | | |
| eg, target A2 | – | 80%–90% dentin A3 | + | 10%–20% WD |
| **Very high–opacity mock-up** | | | | |
| eg, target A2 | – | < 80% dentin A4 | + | > 20% WD |

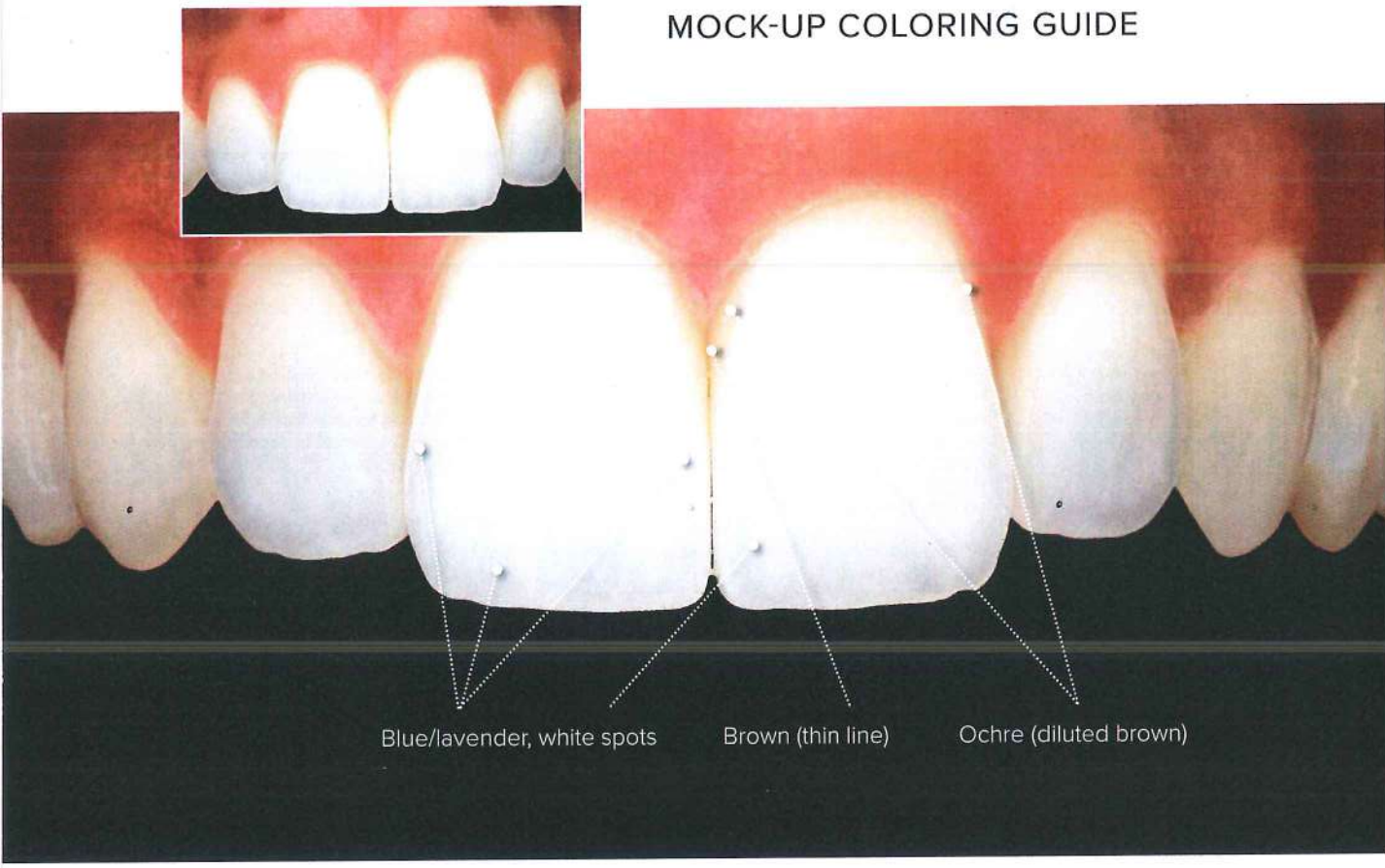




t.me/Dr_Mouayyad_AlbtousH

# 5.7 SPECIAL CASES

## Subtraction/displacement of coronal volumes

Under some specific circumstances aimed at subtracting or displacing the original tooth volume (eg, correction of tooth position but mostly due to the presence of overcontoured restorations), the previously described approach is not applicable. These instances require subtractive corrections of the crown shape to generate clearance for the fabrication of the mock-up, which will also act as an interim restoration. Figure 5-11 presents a basic mock-up (not colored), and Fig 5-12 presents an advanced mock-up. Only after the patient's approval of objective modification of the mock-up configuration can the tooth preparations be scheduled and carried out with a very specific technique (see chapter 6, section 6.9).

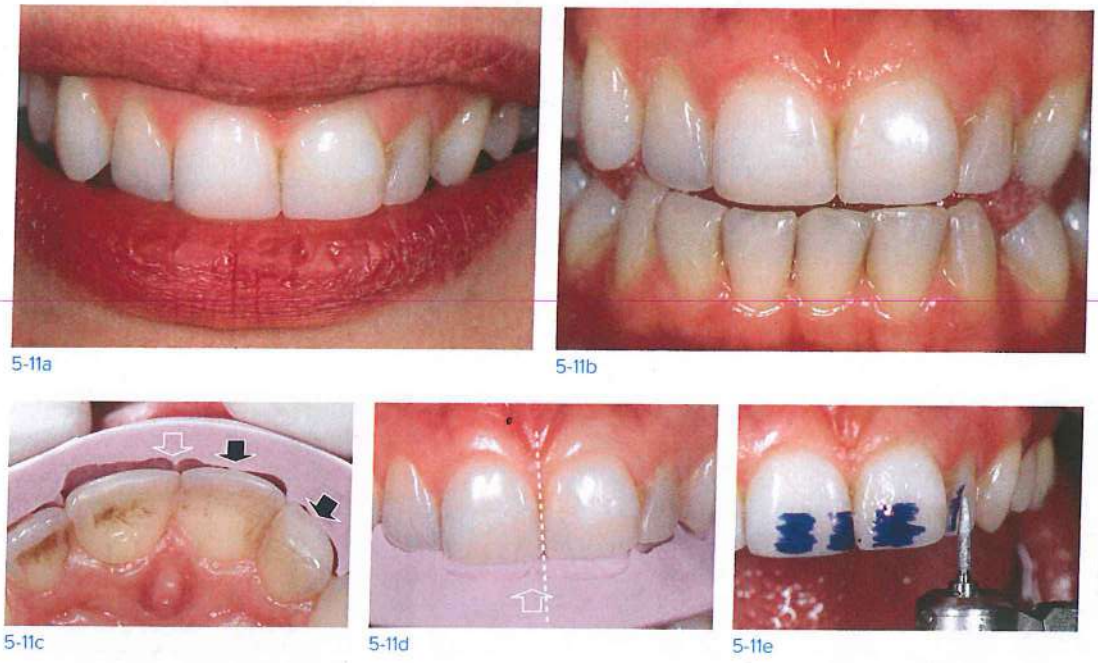


**FIG 5-11 Subtractive basic mock-up—remodeling of the lower lip by the mock-up.** *(a and b)* Initial clinical views showing combined indication for porcelain veneers (expressly requested by the patient): correction of incisal slant, restitution of incisal prominence, and restoration of previously fractured crowns. Worn composite resin restorations are found at the facial and incisal aspects of the maxillary right central incisor to the left canine as well as the mandibular right central and lateral incisors. Note the slant of the maxillary central incisors *(b)*. The treatment objective was defined by a corrective wax-up. *(c and d)* The corresponding sectioned silicon indexes are placed intraorally. Note the repositioning and shift of the midline *(arrow in d*, interincisive line) and the insufficient space for the mock-up *(blue arrows)*, especially at the level of the left central and lateral incisors. *(e)* These areas are marked, and reduction of existing composite resin restorations was carried out with the patient's consent.


t.me/Dr_Mouayyad_AlbtousH



5-11f



5-11g

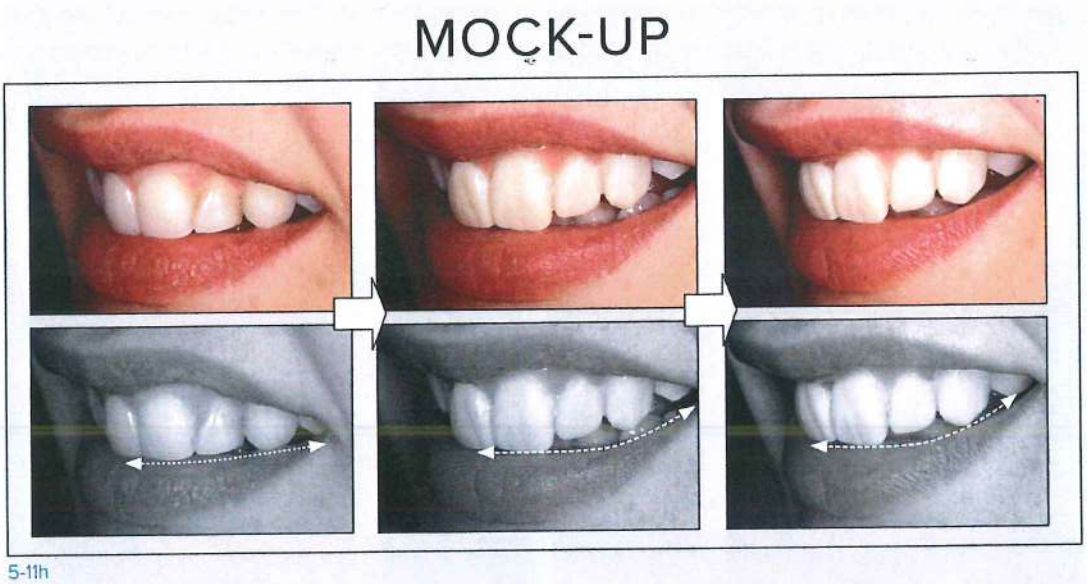


5-11h

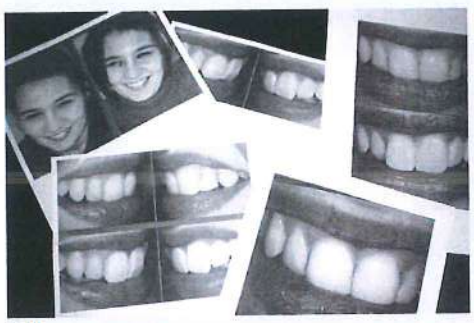

5-11i



5-11j

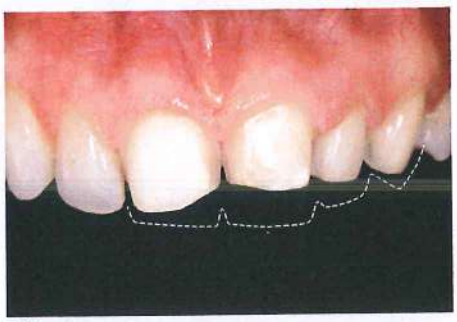

5-11k

**FIG 5-11** *(cont) (f and g)* Enough clearance is created for a basic mock-up. Significant improvements were obtained by this simple technique (corrected tooth length and smile line). *(h)* Restoration of incisal prominence by the mock-up is often accompanied by spontaneous remodeling of the lower lip; compare the flat lip line at baseline *(left)* with the recontoured lip at "mock-up day" *(center)* and even more curved lip line 1 week later *(right). (i and j)* Modifications of this preliminary goal can be easily and objectively discussed using before-and-after photographs of the mock-up presented to the patient. In this specific case, the exchange of information revealed that the patient expected softer, more rounded shapes. *(k)* Tooth preparations were guided by the silicon indexes. The left central incisor had to be prepared more extensively because of its more labial position. Tooth reduction was minimal on other teeth.


t.me/Dr_Mouayyad_AlbtousH



5-11l



5-11m



5-11n




5-11o

**FIG 5-11** *(cont) (l to n)* Immediate final views and smile show the objective modifications compared to the diagnostic mock-up. *(o)* Corresponding situation after 19 years of clinical service. Note the stability and health of the soft tissues as well as the slight difference in length between the central incisors, deliberately complying with the difference of gingival levels. Other images of this case are presented in chapter 6, Fig 6-12.



t.me/Dr_Mouayyad_AlbtousH



5-12a



5-12b



5-12c

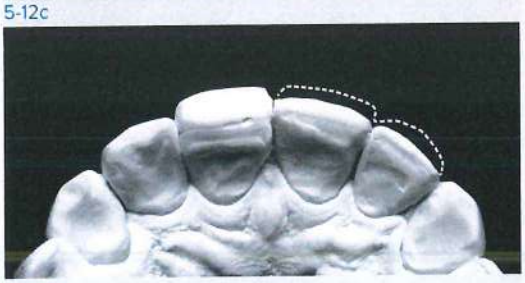

5-12d

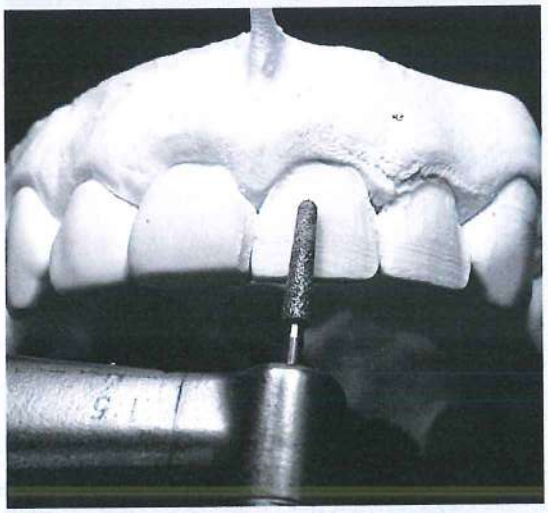

5-12e



5-12f



5-12g

# WAX-UP

**FIG 5-12 Subtractive advanced wax-up and mock-up.** *(a to c)* This patient presented with thick and overcontoured ceramic veneers on the maxillary incisors. *(d and e)* The stone cast must be modified subtractively in order to start the wax-up (left side reduction demonstrated here). *(f to i)* All four incisors were modified, and the wax-up was completed additively over the subtracted surfaces, except for a slight addition to the right canine tip. *(j)* The patient consented to having the existing veneers removed. *(k and l)* Note the lack of clearance for the mock-up at the distoproximal line angle of the left lateral incisor *(arrow)* and subsequent reduction of the tooth.


t.me/Dr_Mouayyad_AlbtousH



5-12h

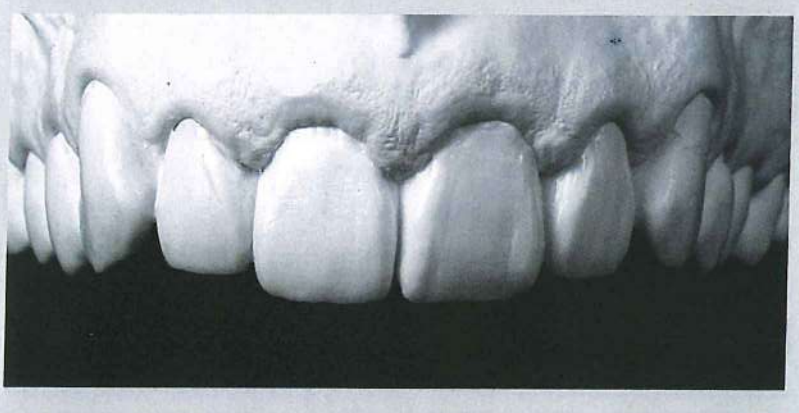

5-12i



5-12j

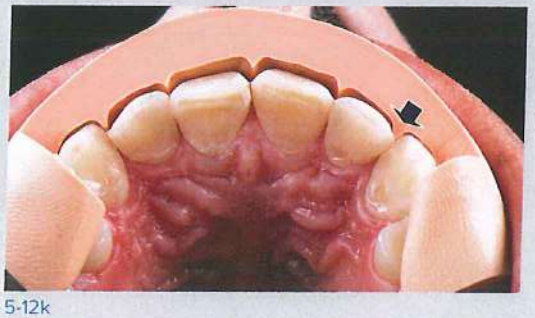

5-12k



5-12l



t.me/Dr_Mouayyad_AlbtousH



5-12m



5-12n



5-12o

MOCK-UP





5-12p

**FIG 5-12** *(cont) (m and n)* Silicon index no. 3 was applied with PMMA, and the mock-up was refinished with resin coloring and glazing resin as previously explained. *(o and p)* Note the more natural flow of the smile and emergence profile of the mock-up compared to the baseline (overlay image in *p*).


t.me/Dr_Mouayyad_AlbtousH

The direct mock-up methods presented so far are simple and time-effective. Figures 5-4 and 5-11 describe the most basic direct mock-up, but it could be easily enhanced using light-polymerized colorants to characterize the interdental area (eg, Kolor + Plus, Kerr) and a liquid glazing resin (eg, Skin Glaze, Anaxdent) to soften the surface (as seen in Figs 5-10 and 5-12); the brown interdental coloring increases teeth's individuality by giving the illusion of an interdental "microgap," the blue/lavender provides an incisal translucency effect, and the soft glossy surface of the glaze improves the surface scattering and patient comfort. The same exact methods can be applied when fabricating provisional restorations (see chapter 6, section 6.11).

## Indirect mock-up

When clinicians do not feel comfortable with the direct technique, demanding patients can receive an indirect mock-up. Increased clearance facilitates indirect procedures; hence, a possible strategy is to proceed to preliminary tooth preparations and impressions (with the patient's consent). A short-term basic mock-up is placed as an interim. This will enable the fabrication of a more elaborate mock-up by the laboratory using, for instance, a sandwich technique (Fig 5-13).[1,34] Fabrication of refined mock-ups may seem exaggerated; however, it offers maximum predictability of the treatment outcome and invaluable influence to reestablish patients' confidence. This aspect of the relationship is priceless when compared to the possible consequences of inadequately defined treatment objectives. As a matter of fact, it would be costlier to miss the esthetic goal and have to redo the final ceramic work. Instead, ***the additional effort given to the diagnostic mock-up provides invaluable predictability and assurance to the dental technician when fabricating the final ceramic restorations.***



5-13a



5-13b

**FIG 5-13 Indirect mock-up for a demanding patient.** *(a)* Recovery of esthetics and function of anterior teeth as well as the patient's expressed demand for ceramic restorations were the driving forces for planning indirect porcelain veneers in this patient (see also chapter 6, Fig 6-8, type IIC). *(b)* Because the direct mock-up did not satisfy the patient, preliminary tooth preparations and impressions were carried out to fabricate an indirect mock-up. Here is the clinical situation just before impression-making. (Reprinted with permission from Magne and Douglas.[35])



t.me/Dr_Mouayyad_AlbtousH

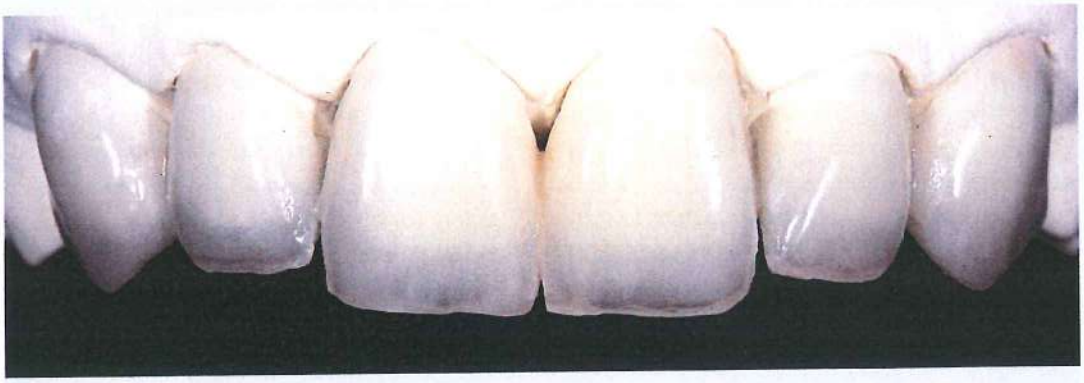

5-13c

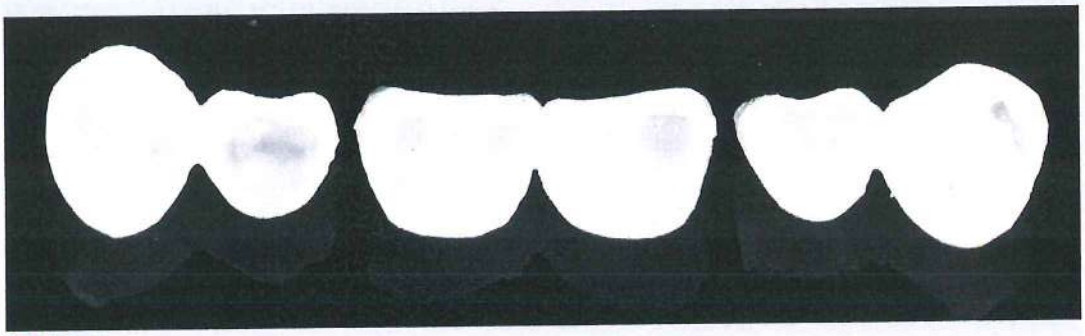

5-13d



5-13e



5-13f

**FIG 5-13** *(cont) (c)* The indirect mock-up is made similarly and with the same PMMA materials (New Outline) used for the direct technique; however, different translucencies (enamellike and dentinlike) were combined in a sandwich technique described elsewhere.[1,34] *(d)* Due to incompatible insertion axes, the mock-up was divided into three segments and placed two by two using a clear temporary luting cement (Temp-Bond Clear, Kerr; see chapter 6, Fig 6-53). The three segments were then connected and locked into position by adding flowable composite resin in the lingual embrasures. *(e and f)* The patient's satisfaction and confidence were established through this indirect diagnostic approach. *(g)* Because of the optimal quality of the original impression and the fact that tooth preparations did not require modifications, the final porcelain restorations could be fabricated without additional clinical steps, and the intact original single dies were used (see chapter 6, fabrication of master models, Figs 6-59 to 6-63). *(h and i)* Final views following definitive insertion of the porcelain veneers. Other views of this case are presented in chapter 6, Fig 6-8. (Part *h* reprinted with permission from Magne and Douglas.[35])


t.me/Dr_Mouayyad_AlbtousH

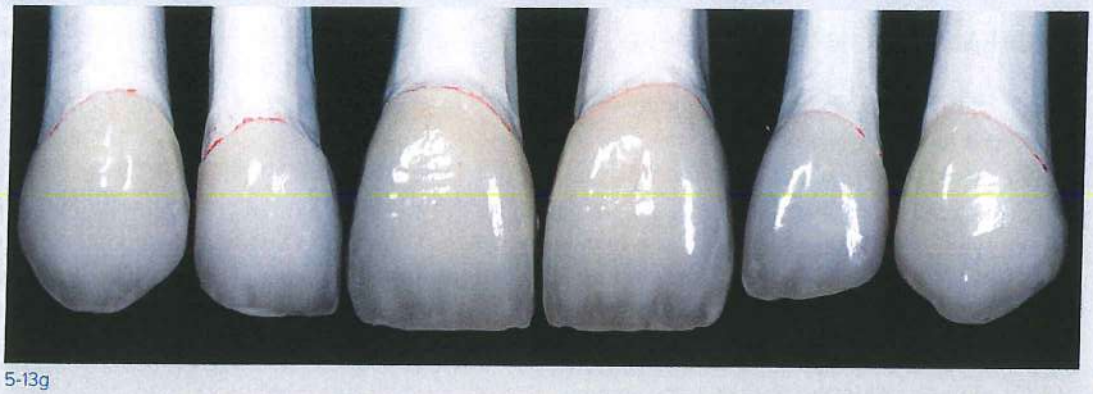

5-13g



5-13h



5-13i



t.me/Dr_Mouayyad_AlbtousH

## Dual-additive wax-up/mock-up

Corrective measures sometime need to involve both the teeth and the periodontal tissues (Fig 5-14). This situation calls for a specific diagnostic approach to confirm the treatment goals before leading the patient toward an irreversible corrective periodontal surgery.

> The use of a so-called "dual-additive" wax-up/mock-up (additive over the teeth and over the gingiva) allows the patient to test-drive not only the morphologic modifications of the teeth but also preview the outcome of the potential periodontal surgery.

The information gathered during the first stage (Figs 5-14a to 5-14p) is used to fabricate surgical guides for the second stage (Figs 5-14q to 5-14s), namely the periodontal surgery itself. The third stage can be initiated after the healing is complete; when indicated, the healed situation is used for a second wax-up/mock-up to confirm the treatment goal (Figs 5-14t to 5-14y). The fourth stage is the replacement of the mock-up by the final restoration, whether via a direct, semi-indirect, or indirect approach. Figure 5-15 shows another patient who benefited from the dual-additive approach before receiving direct composite resin restorations without any need for stage 3.



5-14a



5-14b

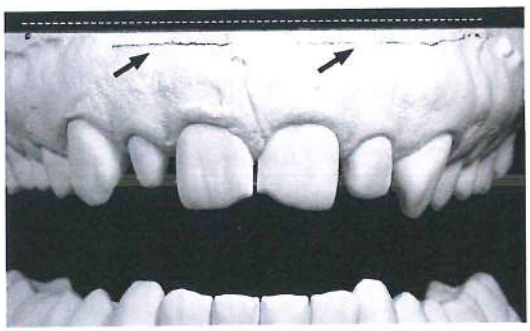

5-14c

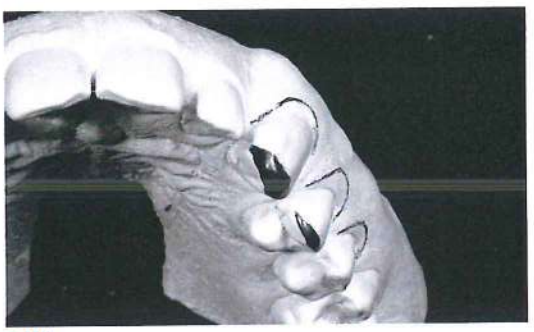

5-14d

**FIG 5-14 Multidisciplinary case requiring dual-additive approach—stage 1.** This patient requested ultraconservative esthetic correction of his maxillary anterior teeth without orthodontics. *(a and b)* The interpupillary and intercommissural lines coincide *(dotted line)* and are reported on the study cast using the Ditramax facial analyzer *(c, pencil mark, arrows)*. The assessment clearly reveals the need for corrective mucogingival surgery. The tips of the left canine and first premolar are too long. *(d and e)* Pencil marks outline the gingival corrections on the cast (see also Photoshop Smile Design in Fig 5-2), which involves all anterior teeth and premolars except the right canine. *(f and g)* A slight reduction of the stone between the tooth and the pencil mark leaves a clean surface to guide the wax-up. *(h)* The wax is applied additively to the teeth and overlaps the reduced surface of the gingiva.



t.me/Dr_Mouayyad_AlbtousH

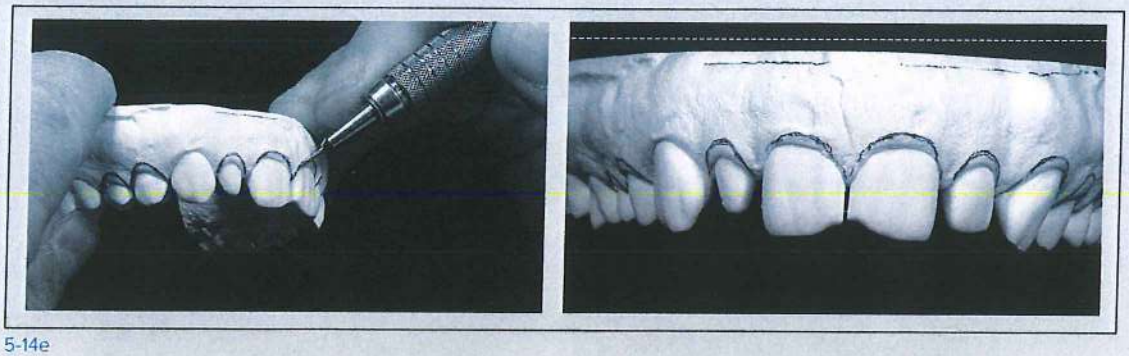

5-14e

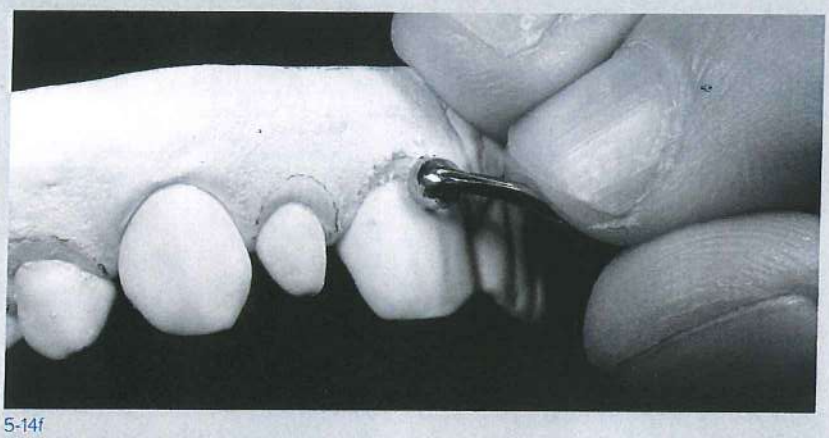

5-14f

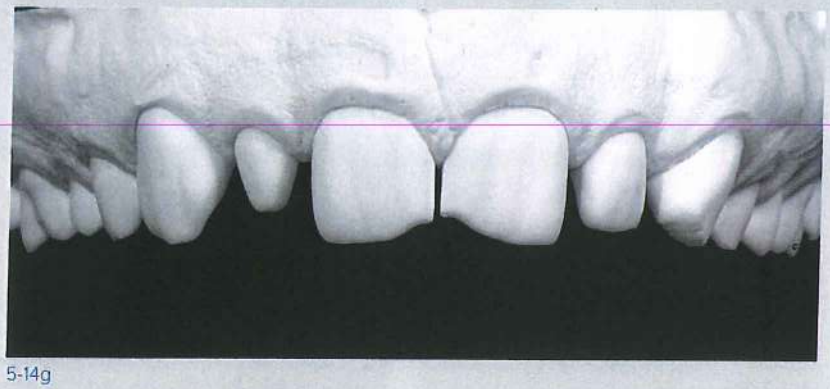

5-14g

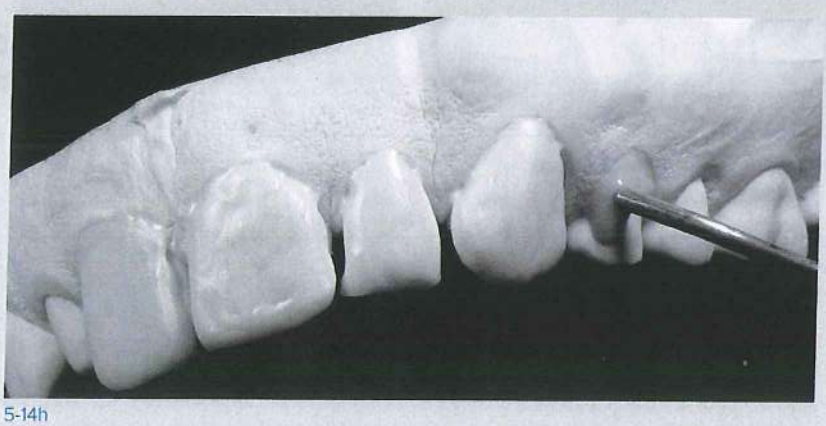

5-14h



t.me/Dr_Mouayyad_AlbtousH

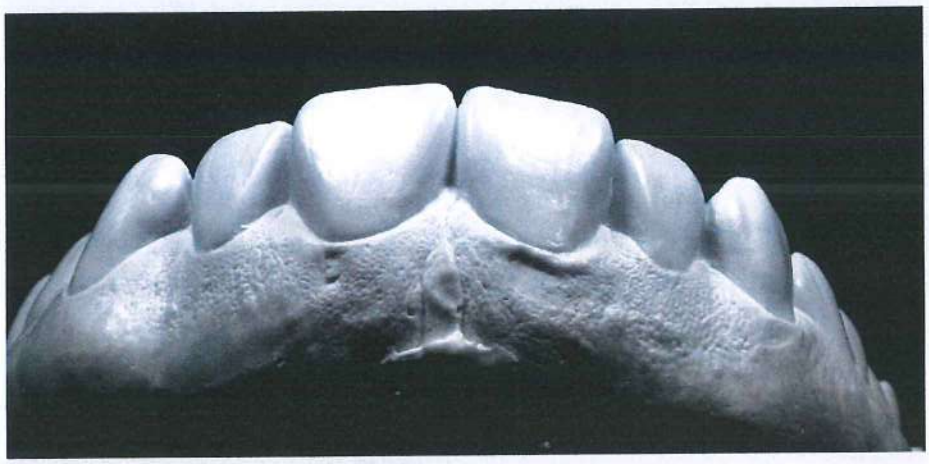

5-14i

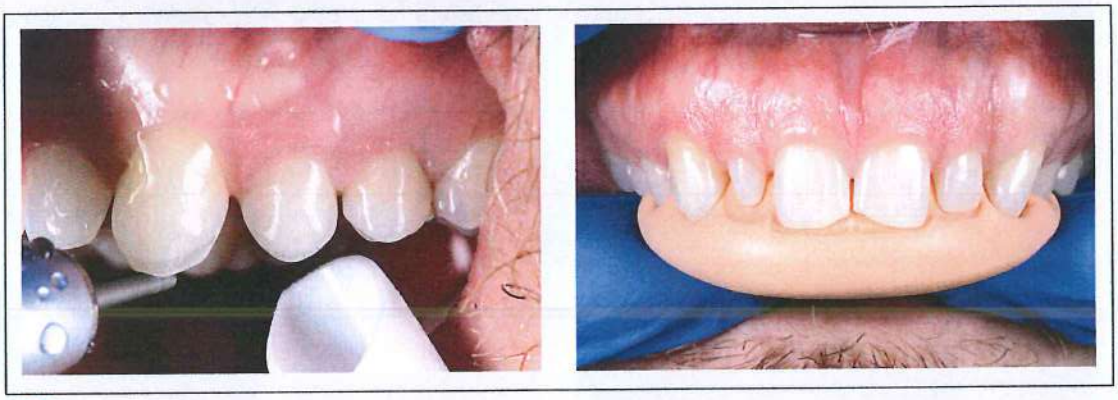

5-14j



5-14k

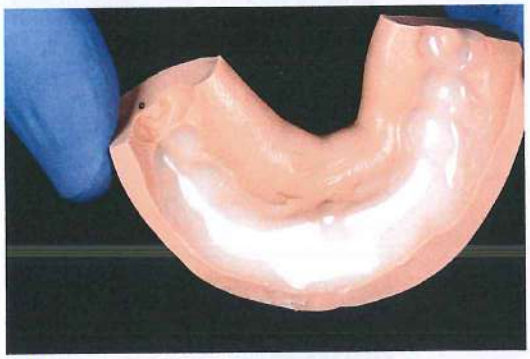

5-14l

**FIG 5-14** *(cont) (i)* Completed wax-up. *(j)* The patient consented to have the tips of his left canine and first premolar slightly shortened in order to place the mock-up, and clearance was checked with silicon indexes. *(k)* The mock-up will be thin on those teeth, so spot-etching was applied. *(l)* The resin mix was poured into the silicon index no. 3. When the surface turned matte, the index was slowly applied to the teeth and left until complete setting of the material. *(m and n)* Finishing, coloring, and glazing were carried out. *(o and p)* Like the wax-up, the mock-up is additive on both the teeth and the gingiva (ridge-lap design) to simulate gingival corrections (compare with preoperative overlay images). The patient fully approved the design during the "test drive" and consented to have surgery. An impression was made to fabricate the surgical guides corresponding to the approved diagnostic template.


t.me/Dr_Mouayyad_AlbtousH



5-14m

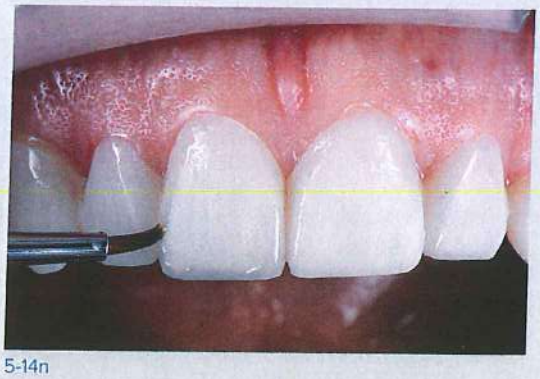

5-14n



MOCK-UP #1



5-14o



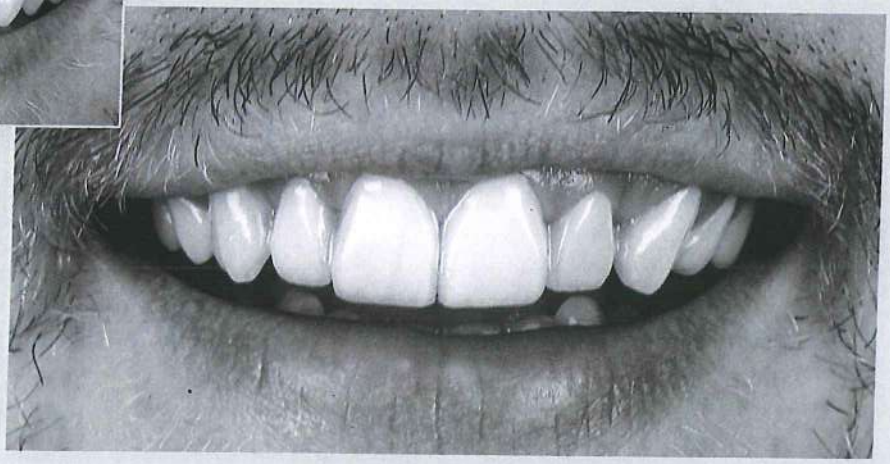

5-14p



t.me/Dr_Mouayyad_AlbtousH

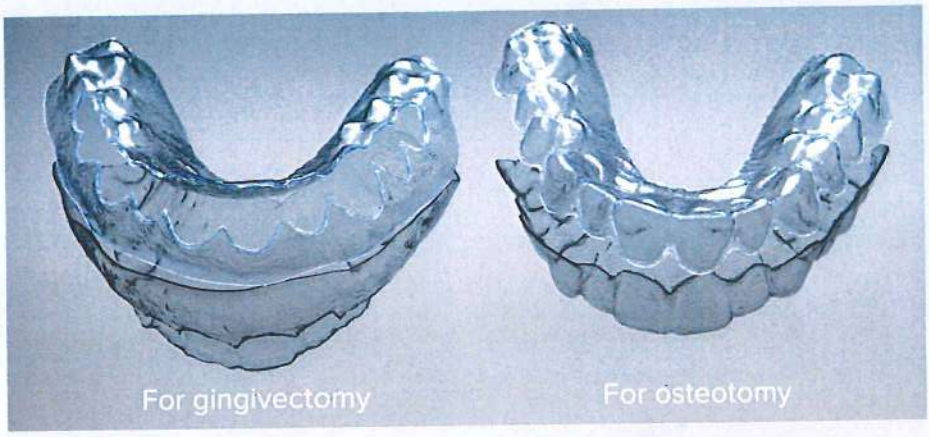


5-14q



5-14r

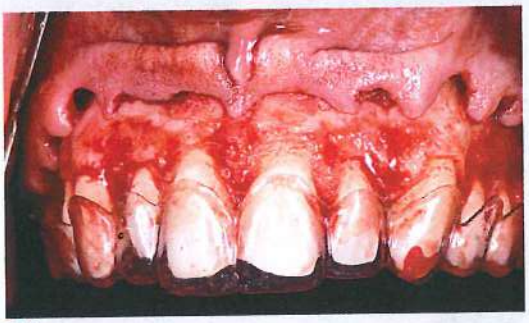

5-14s



5-14t


t.me/Dr_Mouayyad_AlbtousH



5-14u



5-14v



5-14w



5-14x

MOCK-UP #2



5-14y

**FIG 5-14** *(cont)* **Dual-additive approach—stages 2 and 3** (surgical phase and second mock-up). *(q)* Two surgical templates were fabricated from the stone cast of the dentition with the mock-up: On the first guide, the teeth were removed *(left)*; on the other side, the gingival overlap was removed *(right)*. *(r)* The first template was used by the periodontist to guide the gingivectomy, and *(s)* the second template was used to guide the osteotomy. (Surgery performed by Dr Ramon Ceballos.) Once the healing phase was complete, new impressions/casts were obtained for the second wax-up *(t and u)* and the corresponding mock-up *(v to y*, preoperative view for comparison in *w)*. The patient again approved of minor modifications (left lateral incisor needs to be more buccal). (Case treated in collaboration with Dr Amber Parker.) See final restorative steps using semi-indirect CAD/CAM composite resin veneers in chapter 6, Fig 6-29.



t.me/Dr_Mouayyad_AlbtousH



5-15a



5-15b



5-15c



5-15d



5-15e

**FIG 5-15 Dual-additive wax-up/mock-up before direct composite resin restorations.** *(a)* This patient requested interdental closure of diastemata, which would lead to unfavorably high width/length ratios. *(b to e)* Hence, corrections of the gingival contours were also proposed through a dual-additive wax-up. *(f)* Corresponding mock-up (with ridge-lap design) during coloring phase and *(g to i)* final glazed mock-up. The patient approved stage 1 and consented for stage 2 surgery. Her wish, however, was toward slightly shorter incisors compared to the mock-up. Surgical guides were produced accordingly as presented in Fig 5-14q (previous case).


t.me/Dr_Mouayyad_AlbtousH



5-15f

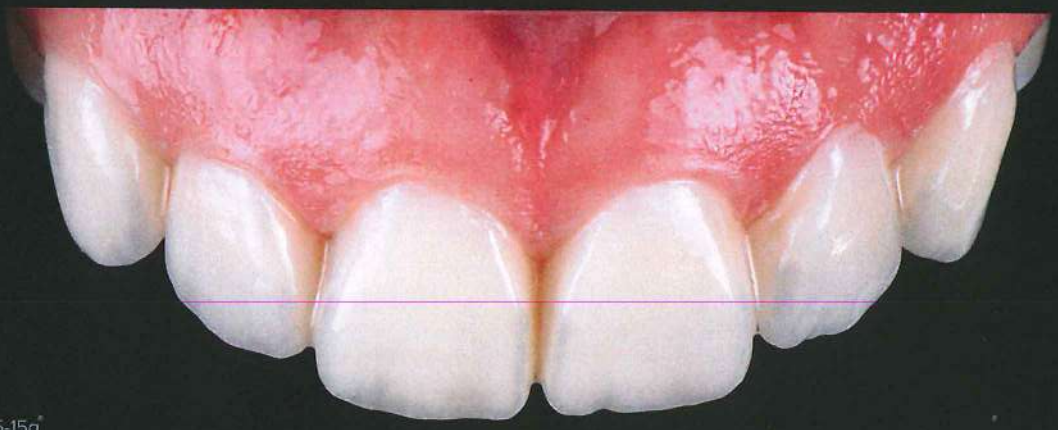

5-15g



5-15h

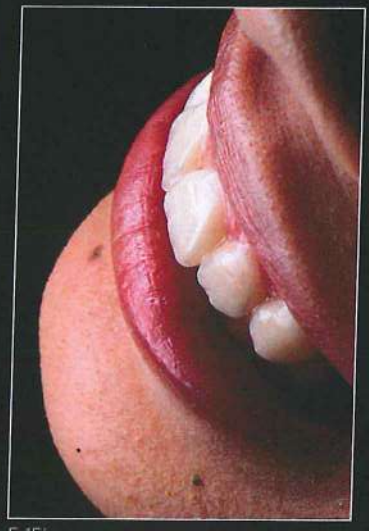

5-15i



t.me/Dr_Mouayyad_AlbtousH

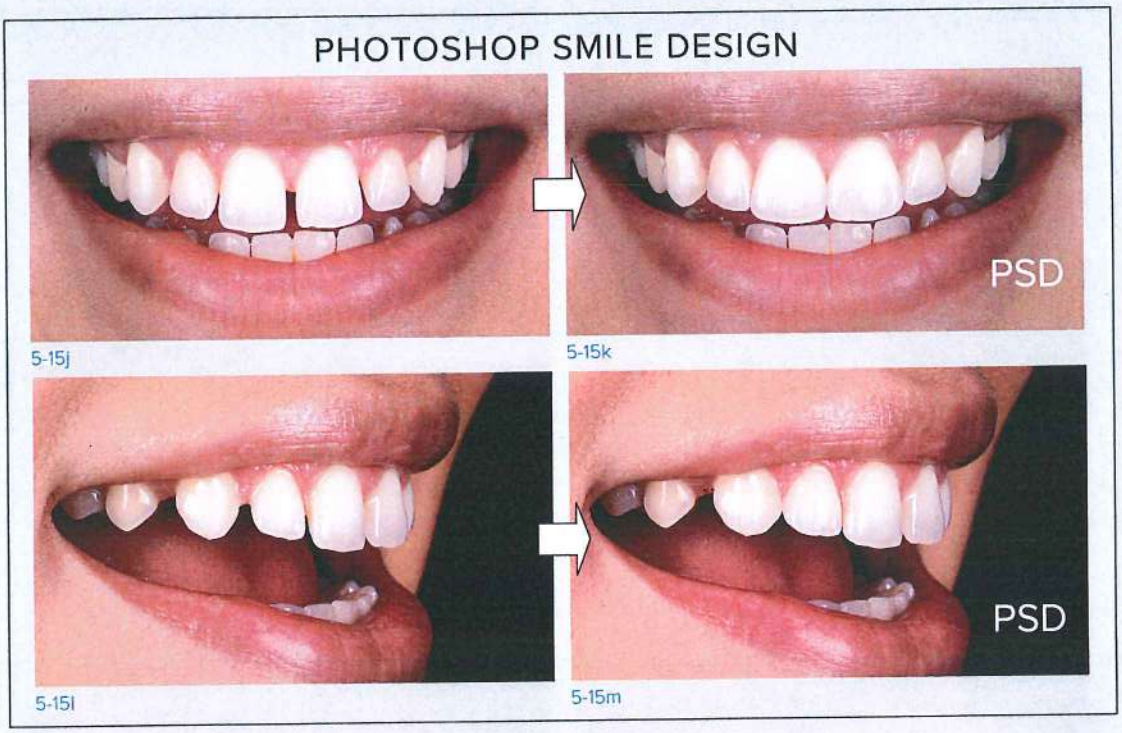


5-15j

5-15k

5-15l

5-15m



5-15n



5-15o



5-15p



5-15q

**FIG 5-15** *(cont) (j)* View of the smile after healing of the corrective periodontal surgery. (Surgery by Dr Shantia Kazemi.) *(k)* PSD was briefly used (see method in Fig 5-2) to confirm that the gain in coronal length allows for interdental closures without compromising the width/length ratios. Further closure of the spaces between the canines and premolars would require orthodontic treatment, which was not an option for this patient. *(l and m)* The same PSD procedure was applied to a three-quarter view. *(n to q)* Additive contours were so small and localized that it was decided to proceed directly with freehand composite resin restorations from canine to canine. *(r and s)* The final restorations were shorter than the mock-up (as per the patient's wish) and display attractive internal effects (with corresponding preoperative views in overlay images for comparison). The incisal embrasure between the central incisors was left more open than predicted by PSD to lessen the contrast with the previous diastema. (Case treated in collaboration with Dr Mehrdad Razaghy.)


t.me/Dr_Mouayyad_AlbtousH



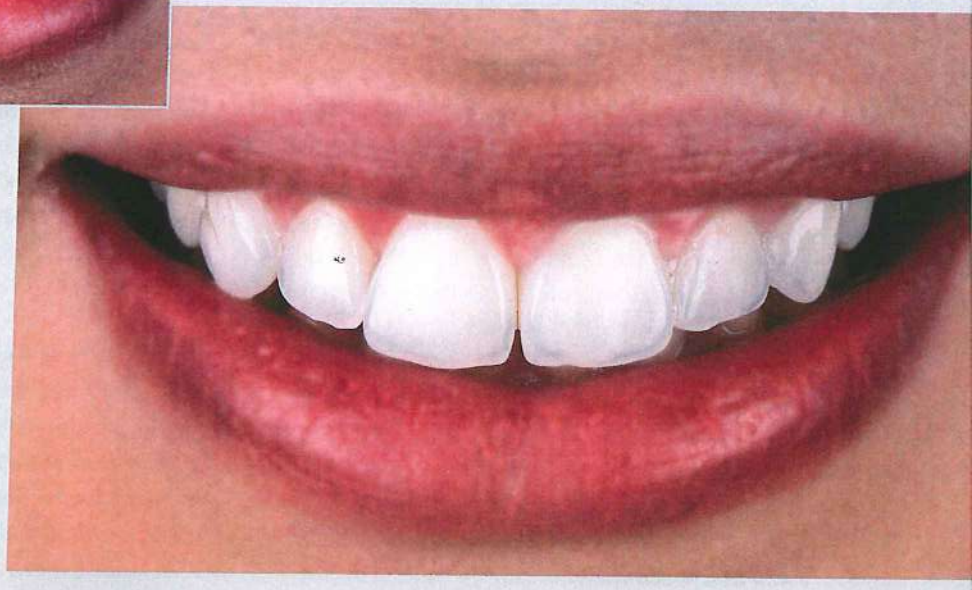

5-15r



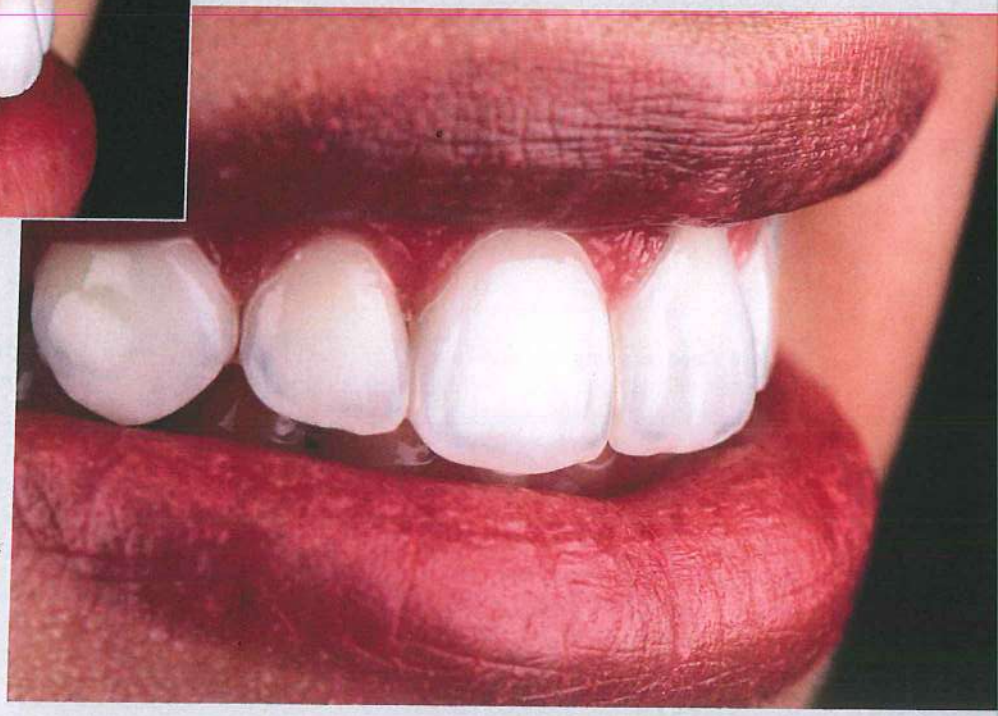

5-15s



t.me/Dr_Mouayyad_AlbtousH

## Bonded porcelain combined with traditional full coverage

Situations in which existing anterior full crown coverage must be replaced in combination with bonded porcelain restorations on neighboring or antagonistic teeth are not uncommon. Figure 5-16 depicts a difficult case requiring a full-coverage crown on one central incisor and a porcelain veneer on the other. It would be difficult for the dental technician to fabricate these different types of restorations simultaneously. The challenge lies in the fact that the esthetic integration of thin bonded porcelain is highly related to the underlying tooth substrate, adhesive luting agents, and tooth-hydration conditions. On the other hand, the final esthetic outcome of thicker and more opaque cemented crowns (PFM or zirconia-based) is only minimally influenced by the tooth, the underlying cement, or hydration conditions. A special sequence may facilitate the ceramist's work:

1. **Diagnostic phase:** Inappropriate crowns are removed and replaced by direct provisional crowns (Fig 5-16b), using, for instance, prefabricated resin shells; the traditional PMMA mock-up is then carried out over the preexisting restorations and teeth.
2. **Restorative phase I:** ***Definitive bonded porcelain restorations are produced first and delivered*** along with PMMA provisional crowns on teeth requiring full coverage (Figs 5-16e and 5-16f).
3. **Restorative phase II:** About 2 to 4 weeks later (the estimated time required for stabilization of color/hydration of bonded restorations), ***a separate impression is taken for replacement of the remaining provisional crowns with definitive crowns***. Shade selection and photographs should be repeated at this stage. In this way, the ceramist can accurately complete the full-coverage crown and reproduce optical properties identified on the already "integrated" bonded porcelain restorations.

For the case in Fig 5-16, inversion or simplification of this sequence (ie, by proceeding to a single impression and simultaneous fabrication of definitive restorations on both central incisors), would have resulted in an unpredictable esthetic outcome due to the different integration modes of the two types of restorations. Note that experienced ceramists will tend to use the same porcelain brand for both the bonded veneers and cemented full-coverage crowns. They will also tend to layer both restorations simultaneously to include similar internal effects. They will, however, keep the full-coverage crown in a bisque (incomplete) stage, to be tried in and completed after bonding and rehydration of the porcelain veneers.

**FIG 5-16 Case requiring combined use of a PFM restoration and bonded porcelain restorations.** *(a)* This patient presented with an open gold crown on the right lateral incisor and an old resin crown on the left central incisor. *(b)* After removal of the latter, a direct provisional restoration was placed; removal of the open crown did not require temporization. Two porcelain veneers were planned for the right central and lateral incisors, and a regular crown was planned for the left central incisor. *(c)* New volumes, including longer central incisors, were carefully designed by the wax-up. This final treatment objective was tested in vivo by a traditional mock-up and approved by the patient. Following tooth preparation for the veneers *(d)* and final impressions, the ceramist fabricated the final bonded porcelain restorations first along with a laboratory-fabricated provisional restoration for the left central incisor *(e)*. *(f)* The next session consisted of the try-in and adhesive delivery of the porcelain restorations and provisional crown; note the black interdental triangle between the central incisors. *(g)* Two weeks later, the soft tissues had matured (note perfect closure of the interdental space). *(h)* The PFM crown was completed only at this final stage, following a second impression. *(i)* With this particular sequence, the dental technician could fabricate a PFM perfectly reproducing the preexisting veneers. Other aspects of this case (veneers on the right central and lateral incisors) are presented in chapter 6, Fig 6-85, and chapter 7, Fig 7-8.



t.me/Dr_Mouayyad_AlbtousH



5-16a



5-16b



5-16c



5-16d

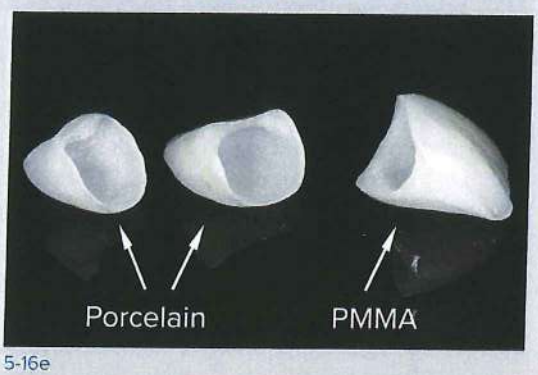


5-16e



5-16f




5-16g



5-16h

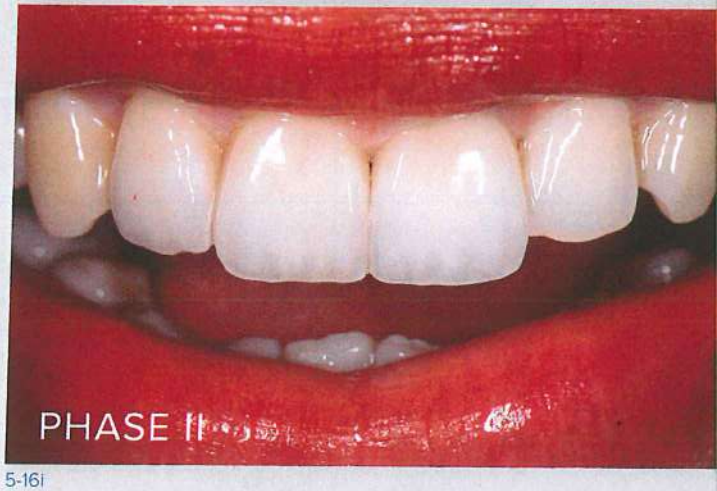


5-16i



t.me/Dr_Mouayyad_AlbtousH

## Special considerations related to orthodontic therapy

> Incisal edge wear develops in a specific pattern related to the exact tooth position and long axis. When bonded restorations are planned subsequently to orthodontic therapy, the orthodontist should position teeth ideally, according to their main axis, crown emergence, and gingival contour (see Fig 2-1a in chapter 2). Preexisting wear facets and incisal edge configuration must be absolutely ignored at this stage.

As a result of this approach, the dental composition can appear esthetically displeasing following orthodontic treatment because incisal edges no longer conform to the newly designed occlusal plane and smile. This is to be expected and will be resolved subsequently by diagnostic and restorative procedures. Figure 5-17 depicts a case of severe Class II, division 1 (dental and skeletal) malocclusion treated by combined orthodontic/orthognathic surgery (Figs 5-17a and 5-17b). In the presurgical stage, space analysis required extraction of a mandibular incisor and interdental stripping of anterior maxillary teeth. The patient was referred for restorative work only at the end of this extensive orthodontic/orthognathic treatment. Crown shape and length still appeared inappropriate, as illustrated by the inverted incisal line (Figs 5-17e and 5-17f), but this problem is easily corrected by the future restorations. Most importantly, tooth positions and gingival contours were favorable and allowed a traditional additive diagnostic procedure. Two consecutive mock-ups were required to reach a satisfactory situation (Figs 5-17g to 5-17n), which was subsequently reproduced in the form of four bonded porcelain restorations (Figs 5-17o to 5-17v).



5-17a



5-17b

**FIG 5-17 Planning for bonded porcelain restorations following combined orthodontic/orthognathic surgery.** The patient originally presented with a Class II, division 1 malocclusion. The extraction of a mandibular incisor and stripping of anterior maxillary teeth preceded orthognathic surgery. *(a)* The cephalometric radiograph clearly demonstrates the presurgical skeletal defect and marked overjet. *(b)* Adequate skeletal and dental relationships were obtained following a bilateral sagittal split osteotomy procedure. *(c and d)* Intraoral views taken after removal of the orthodontic appliance reveal adequate tooth position and favorable periodontal architecture; the tooth forms, however, suffer from the stripping of proximal surfaces. *(e and f)* The configuration of incisal edges is reversed and in tension with the lip line and smile. *(g to i)* A first wax-up and its corresponding basic mock-up were carried out to restore a cohesive incisal edge line.



t.me/Dr_Mouayyad_AlbtousH



5-17c



5-17d



5-17e



5-17f

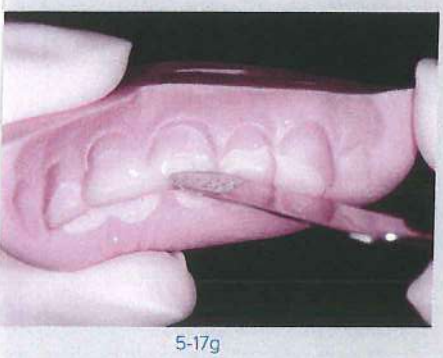

5-17g



5-17h



5-17i



t.me/Dr_Mouayyad_AlbtousH



5-17j



5-17k

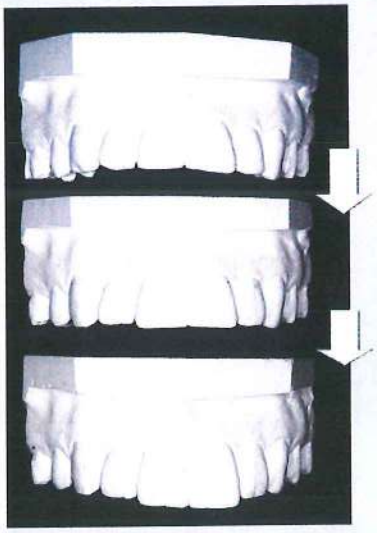

5-17n



5-17l



5-17m

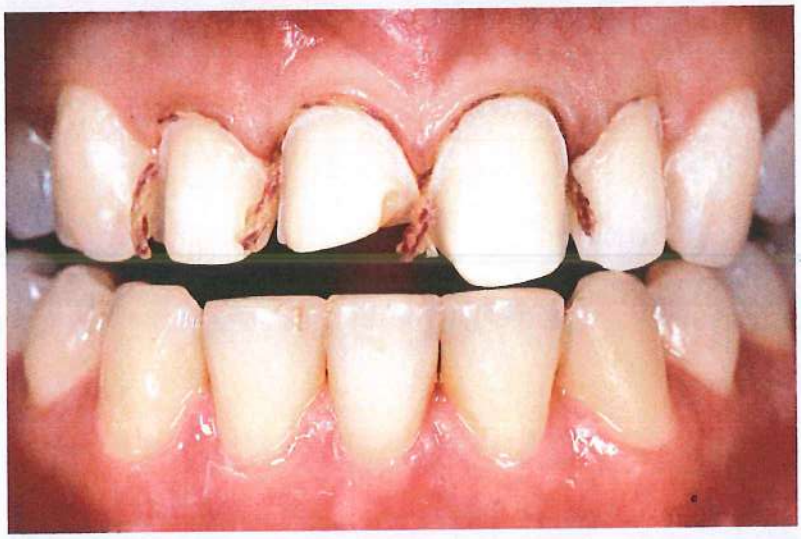

5-17o



5-17p



t.me/Dr_Mouayyad_AlbtousH



5-17q



5-17r



5-17s



5-17t

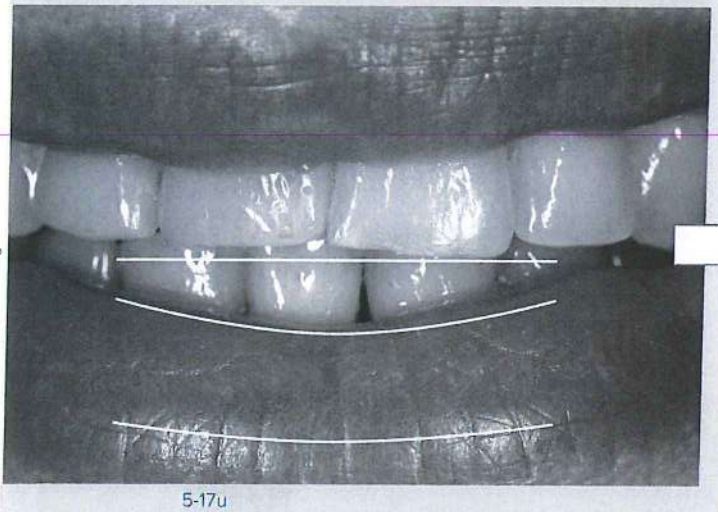

5-17u

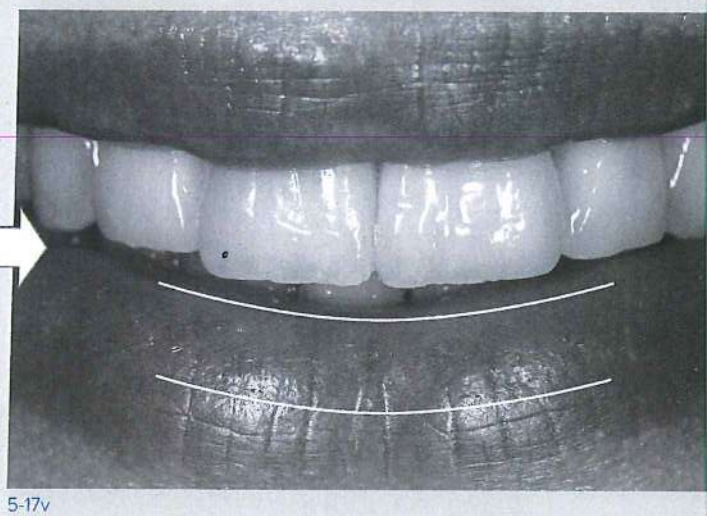

5-17v

**FIG 5-17** *(cont) (j and k)* The patient was pleased with the first mock-up but still asked for longer incisors. *(l and m)* A second basic mock-up was fabricated and resulted in an even more harmonious relationship between the lower lip and incisal edges. *(n)* The final incisal edge elongation was approximately 3 mm; this is now a well-defined objective *(bottom)* compared to the first wax-up *(center)* and initial situation *(top)*. *(o)* Tooth preparations just before taking final impressions. *(p to r)* Final intraoral views with bonded porcelain restorations demonstrate the restored coronal volume and length and faithfully reproduce the diagnostic template *(s and t*; compare with *l and m)*. *(u and v)* The before-and-after black-and-white reproductions aid in understanding the pertinence of cohesive forces generated by the parallelism between the incisal edges and the lower lip. Other aspects of this case are found in chapter 6, Fig 6-68. (Part *t* reproduced with permission from Belser et al.[36])



t.me/Dr_Mouayyad_AlbtousH

# 5.8 BIOCORROSION/WEAR AND TIGHT BITES

## General considerations

Some cases feature additional challenges due to the occlusal status of the patient. So-called "tight bites" represent either patients with deep bite (typically due to localized biocorrosion/wear of maxillary anterior teeth) or Class III malocclusion (edge-to-edge). In both cases, anterior clearance for additive restorations of the teeth is missing.

Tooth surface loss is manifested through various clinical aspects, and a wide range of etiologic factors are possible. Among these, dental biocorrosion problems are growing in younger individuals.[37] Dietary acids are popular (especially soft drinks). Bulimia, consumption of acidic foods, acid reflux, and chlorine exposure (from swimming) are other possible etiologic factors in younger patients. While it is paramount to recognize the causes of the disease, including possible underlying medical conditions, and establish immediate preventive measures (eg, behavioral changes, switching to nonacidic drinks and food with calcium and phosphate, fluoridation, etc), the restorative dentist will ultimately have to select the appropriate treatment strategy. Immediate dentin sealing (IDS) with a filled light-polymerized dentin bonding agent is certainly the most appropriate measure to reduce the rate of wear and biocorrosion.[38] While it provides instant protection and desensitization, the application of dentin bonding agents does not address the real biomechanical issues and long-term prognosis of the eroded/worn teeth. Loss of form, function, and esthetics are additional reasons to consider a true restorative approach to the treatment of biocorrosion lesions. Bonded restorations, due to their conservative nature, should be chosen whenever possible.[39–41] Based on the individual situation and the perceived needs and concerns of the patient, direct and semi-(in)direct application of composite resins[39,42,43] and/or bonded porcelain restorations[40,41] can be proposed.

## Restorative strategies: Deep bite

***In order to define the right treatment strategy, two parameters need to be assessed: (1) whether the biocorrosion wear is generalized or localized, and (2) whether the amount of tooth structure loss is severe or moderate (Fig 5-18).***

**FIG 5-18 Localized vs generalized biocorrosion/wear: Basic treatment strategies to open the bite.** *(A)* Localized anterior loss can be treated noninvasively by opening the bite using a deprogrammer (eg, Lucia jig),[39] which will provide enough lingual clearance for direct composite resin restorations (incisors and canines) or semi-indirect composite resin veneers in the case of more severe loss. When posterior teeth do not need restorative work or are not showing significant substance loss, they can be left to spontaneously move into occlusion (posteruptive movement by the Dahl principle). When necessary, small occlusal adjustments of posterior teeth may be carried out, mostly additively with composite resins, to complete the desired occlusal scheme. Cases with moderate generalized hard tissue loss can also benefit from the same strategy by restoring erosive lesions (usually cusp tips) with direct composite resins before the last stage of the Dahl principle. *(B)* Severe generalized loss of hard tissue is also treated by opening the bite. Deprogramming might not be required depending on the anterior teeth's relationship (eg, existing Class II). The dentition can be restored with various techniques depending on the severity of the clinical situation and economic status of the patient, from a low-cost approach with direct and semi-indirect composite resins to more sophisticated and expensive indirect techniques implementing ceramics. In some instances, one arch is less severely affected than the other and can be restored directly (B1 antagonistic arch indirectly); in other cases, both arches are restored equally (B2), depending on occlusal plane relationships. In both *A* and *B*, the treatment can be further completed with labial restorations on anterior teeth when indicated (low-cost direct composite resins or indirect ceramic veneers).



t.me/Dr_Mouayyad_AlbtousH

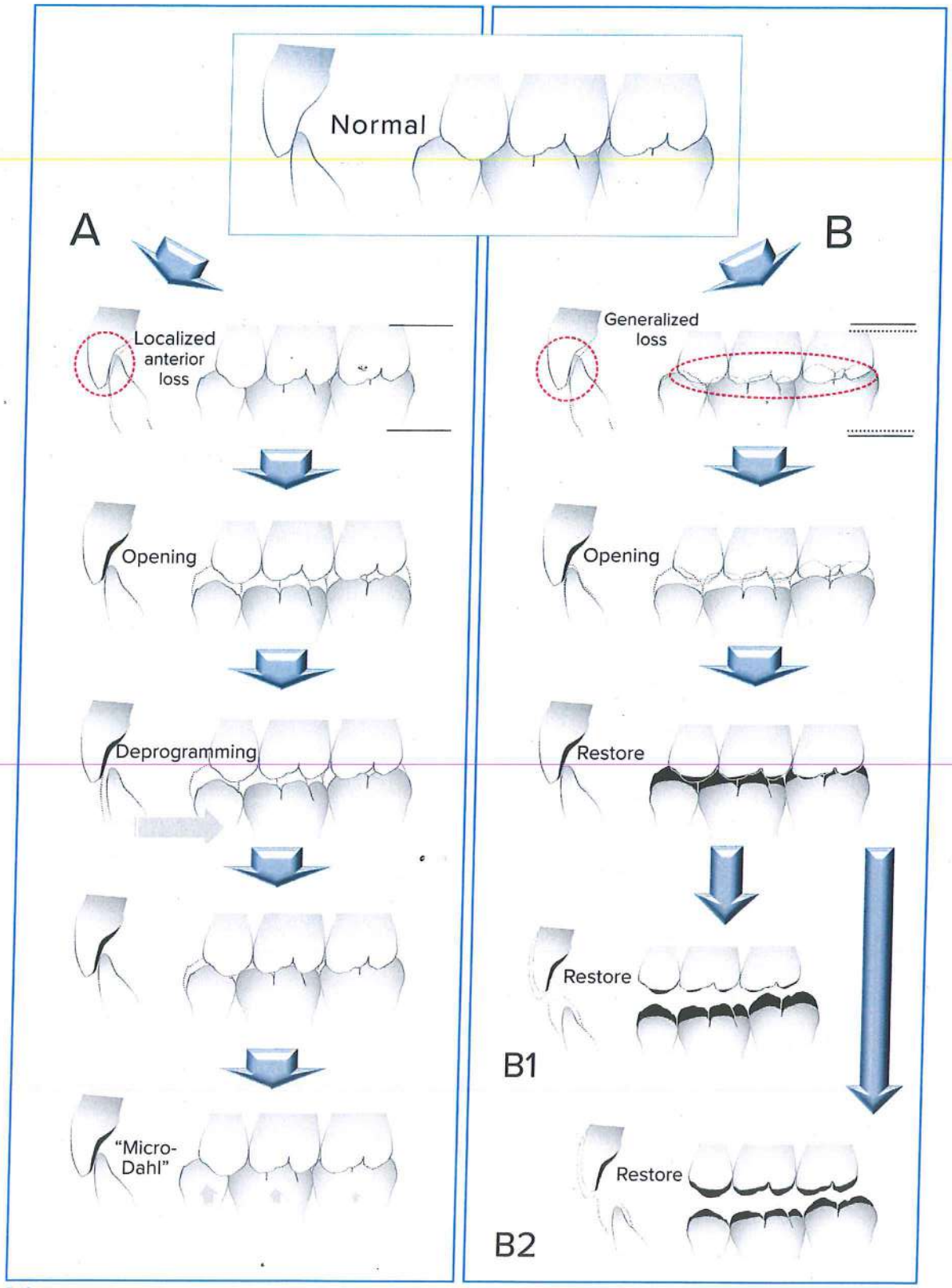


5-18



t.me/Dr_Mouayyad_AlbtousH

Opening and passively deprogramming the bite[39] and sometimes using the Dahl principle[44] can significantly simplify the treatment and allow noninvasive additive procedures (Figs 5-18A and 5-20).[41]

## Creating lingual clearance

Lack of lingual space for the restorative material is particularly challenging in cases of deep bite and combined facial/palatal biocorrosion (Fig 5-20). Those maxillary anterior teeth are usually extremely thin in the buccolingual direction. The lingual surface of maxillary anterior teeth is always a difficult area to prepare because of its geometry, which provides little retention and stabilization features and concentrates tensile stresses (concave). While proceeding to full-coverage crown preparations would be tempting, such a procedure would result in significant loss of intact tooth structure—up to twice the loss of tooth substance compared to a traditional veneer or adhesive preparation.[45,46] In addition, eroded teeth are often short, thin, and flat and may present insufficient retention and resistance, calling for even more invasive procedures compromising pulp vitality (intraradicular posts, etc). Adhesive restorations should always be preferred instead; they are esthetically seamless, and preparation finish lines can generally be left equigingival or supragingival, so they are less likely to generate gingival inflammation compared to traditional full-coverage crowns.[47]

Once the bite is opened (and/or deprogrammed), there are many adhesive restorative options including direct and semi-indirect composite resins as well as indirect ceramics (Fig 5-19). There are several ways to generate palatal interocclusal space in order to additively restore this volume. In cases of generalized biocorrosion/wear, the bite can be opened through the restoration of posterior teeth (see Fig 5-18B and cases in Figs 5-21 and 5-22). In cases of localized anterior biocorrosion/wear with relatively intact posterior teeth, lingual clearance can be obtained with orthodontics. Some patients, however, might not be able to afford these expensive multidisciplinary treatments. Instead, two basic occlusal principles can be combined to approach these cases (see Fig 5-18A):

1. **Passive deprogramming of the bite:** Cardoso et al[39] proposed the use of an anterior deprogrammer (modified Lucia jig) to aid repositioning the mandible toward centric relation (CR) and retain the space for the placement of direct composites. The use of an acrylic jig for recording CR was originally presented by Lucia in 1964,[48] then refined to retain the space required for the placement of restorations.[39,49] Direct composites themselves can also be used as anterior deprogrammers (Fig 5-20). In fact, because of their resilience and ease of manipulation, even in small thicknesses, composite resins represent an ideal material to restore the lingual surface of maxillary teeth. ***There is no need to manipulate the patient in order to move the mandible into the retruded position. It will happen spontaneously via muscle relaxation when disoccluding posterior teeth with the flat anterior jig for 10 to 15 minutes. Only light chin point guidance will be required due to the removal of proprioceptive feedback.***

**FIG 5-19 Four restorative options for anterior maxillary teeth.** A tight bite (loss) can be reopened by orthodontics or more simply by occlusal therapy (deprogramming and implementing the Dahl principle). There are many options to retain the space, from direct techniques with composite resins (both buccal and lingual) to direct composite resins on the lingual with indirect ceramic veneer on the labial (see Fig 5-20), indirect composite resins on the lingual with indirect ceramic veneer on the labial, and, finally, indirect composite resins or ceramics with the "taco-shell design" (V-shaped, one-piece; last option at bottom right; see also Fig 5-27).

**FIG 5-20 Localized anterior loss: Deprogramming and the modified "micro-Dahl" approach.** *(a)* This patient with moderate anterior tooth loss shows a difference between maximal intercuspal position (MIP) and CR. *(b)* There is labial biocorrosion as well as lingual notches ("steps") revealing the deep bite and absence of restorative space. *(c)* Direct freehand composite resin restorations were placed (including replacement of existing Class 3 restorations) to open and deprogram the bite. *(d)* After minor occlusal adjustments and a few months without intervention, all posterior contacts have been reestablished due to the Dahl principle (passive eruption movement). Because of the reduced time and amount of passive eruption (as a result of the deprogramming), the term "micro-Dahl" was coined by the author. (Parts *b*, *c*, and *d* reproduced with permission from Magne et al.[41])



t.me/Dr_Mouayyad_AlbtousH

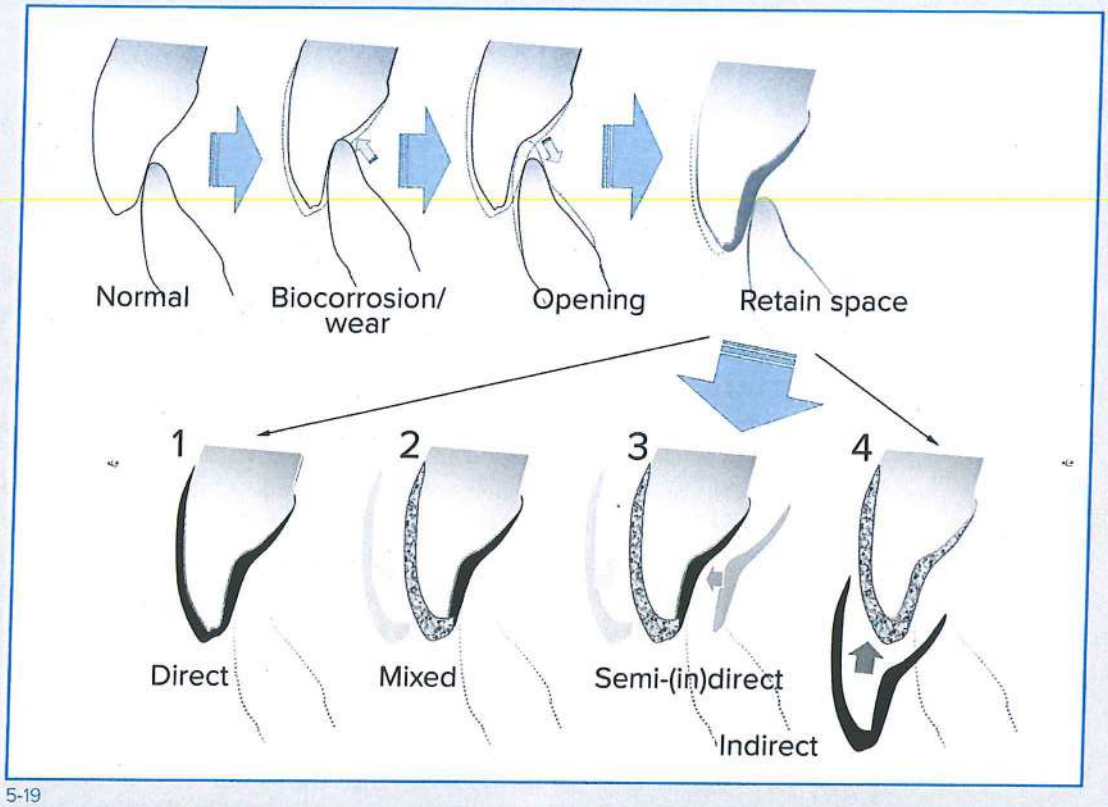


5-19



5-20a



5-20b



5-20c




5-20d



t.me/Dr_Mouayyad_AlbtousH

2. **The modified Dahl principle or "micro-Dahl":** Dahl and Krogstad[44] proposed to open the bite in the treatment of localized anterior tooth wear by separating the posterior teeth through an anterior bite plane for about 4 to 6 months. A combination of passive eruption (posterior teeth) and intrusion (anterior teeth) allowed the reestablishment of posterior occlusion while maintaining the anterior space.[44,50] Dahl originally used an anterior cast metal appliance to separate posterior teeth. The same goal can be achieved today using provisional restorations, mock-ups, and direct composite resins.[51,52] ***Deprogramming should always be attempted before using the Dahl principle in order to reduce the time and the amount of passive eruption (the so-called "micro-Dahl" approach).*** Contacts on the definitive lingual restorations as well as premature CR contacts in posterior teeth can be adjusted in order to increase the number of posterior contacts. The residual interocclusal space (in the most posterior teeth) should be so minimal that it is rapidly eliminated through the "micro-Dahl" principle (ie, a few weeks or months). Careful monitoring of the patient is recommended to ensure proper development of the new occlusal situation.

## Sequential diagnostic approach

There are numerous ways to sequence the treatment for each strategy described in Fig 5-18. The three-step approach by Vailati and Belser[53–55] is the most basic and simplest sequence: *(1)* anterior wax-up/mock-up, *(2)* posterior wax-up/direct posterior composite resins, and *(3)* finalization of anterior guidance (lingual maxillary composite veneers). This logical basic flow can be complemented by adding a few extra steps in order to cover a wider range of clinical situations and restorative techniques[56,57] (Fig 5-21).

Noninvasive indirect (Fig 5-21k) and direct (Figs 5-21l and 5-21m) sectional mock-ups can be combined to open the bite and start the diagnostic phase.

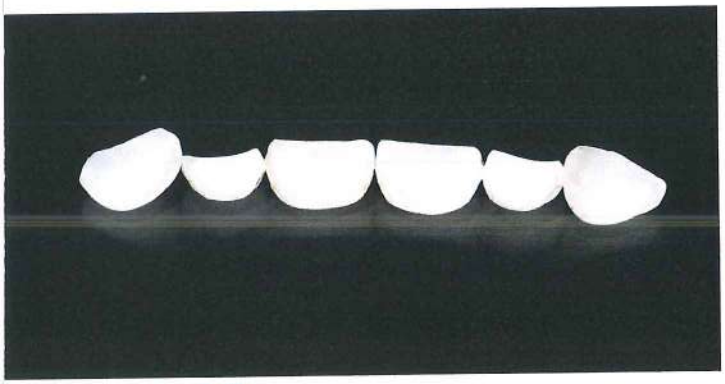

5-20e



5-20f

**FIG 5-20** *(cont) (e and f)* Once the newly established position (slightly posterior to the original MIP) was fully approved by the patient (possibly after a few weeks of testing and stabilization), the anterior teeth received porcelain veneers as per the patient's wish. The final adjustment of the occlusal scheme can be carried out at this stage in order to take into account the newly established anterior guidance, which was also tested in the form of the mock-up prior to the tooth preparation and fabrication of the final veneers. *(g and h)* The case is totally stable after 5 years of clinical service. (Part *f* reproduced with permission from Magne et al.[41])



t.me/Dr_Mouayyad_AlbtousH




5-20g







5-20h



5-21a



5-21b



5-21c



5-21d

**FIG 5-21 Sequential diagnostic approach in a case of severe generalized loss.** *(a to d)* This case of severe generalized loss of tooth structure by endogenic acid reveals deep dentin lesions in almost all teeth except the mandibular incisors. Some loss of VDO may be present. (Part *d* reproduced with permission from Magne et al.[58])



t.me/Dr_Mouayyad_AlbtousH

## Creating a stable "test drive"

When major changes in the vertical dimension of occlusion (VDO) are planned, it is important ***to place the patient in the most accurate "test-drive" conditions possible but still reversible***. For most cases, this can be achieved noninvasively in the following sequence (Fig 5-21):

1. Diagnostic study casts are mounted in the articulator at a tentative open position, with or without deprogramming, depending on existing anteroposterior relationships. Deprogramming in case of Class II occlusions might not be indicated because it would worsen anterior relationships (excessive overjet).
2. An anterior additive wax-up is produced to assess the smile line and occlusal plane. In cases of severe generalized loss including posterior teeth, a posterior wax-up and the corresponding indirect mock-ups can be simply fabricated in the laboratory (Fig 5-21k).
3. The anterior mock-up is more conveniently fabricated intraorally (Figs 5-21l and 5-21m; technique explained earlier in this chapter) and can be complemented by the posterior indirect mock-up, provided by the laboratory, which can be seated in the same clinical session.

For the patient in Fig 5-21, a full-mouth mock-up (in five sections) was provided without need for tooth preparations. Because all mock-ups have been delivered adhesively, this situation can be assessed for several weeks, even months if necessary. Following this test drive, the mock-ups can be replaced sequentially, one sextant at a time, one arch at a time, or one side at a time. There is total versatility because of the stability of the occlusal situation. ***Some clinicians prefer to use the anterior mock-up to keep the bite open while restoring posterior teeth (see Figs 5-25 and 5-26). In other cases, posterior mock-ups can be used to keep the bite open while restoring anterior teeth (Fig 5-21)***. In both cases, mock-ups can be used as a reference to guide the tooth preparations for CAD/CAM occlusal veneers or "veneerlays" (including the buccal surface) in composite resin and ceramics.

***The bilaminar veneer with lingual composite resin, possibly complemented with labial ceramic veneers, is the most conservative approach in anterior maxillary teeth,[56,57] with a load-bearing capacity similar to that of metal-ceramic and lithium disilicate crowns.[59]***

**FIG 5-21** *(cont) (e and f)* Diagnostic models were mounted at a tentative 2-mm open position (preferably not deprogrammed in this case due to the existing Class II bite) using a jig. *(g)* Comparative view of the original bite *(left and h)* and the open bite used to generate a full-mouth wax-up *(right*; opening distributed equally on maxillary and mandibular posterior teeth). *(i)* The anterior wax-up was produced first, and a duplicate model was generated to fabricate the anterior mock-up silicon indexes. *(j)* The full-arch wax-up was then completed. *(k)* Four posterior indirect mock-ups mimicking the posterior wax-ups were fabricated in the laboratory by simply pressing PMMA resin onto the isolated baseline cast using silicon indexes from the posterior wax-up. *(l and m)* The full anterior mock-up (buccal and lingual) was fabricated intraorally, which is best for precision and locking by "shrinkage fit."

**FIG 5-21** *(in following pages) (n and o)* The posterior mock-ups were bonded by enamel/dentin etching using a filled adhesive system (OptiBond FL by Kerr) as a luting agent. *(p and q)* Both arches, additively restored to the tentative VDO, are ready for this noninvasive and totally reversible test drive. After the patient confirmed that this interim situation was comfortable, esthetically and functionally, the restorative phase started with the maxillary anterior teeth using two steps (first lingual composite resin veneers then labial porcelain veneers): All lingual dentin surfaces were roughened with a diamond bur,[60] and then IDS was applied before taking a final impression *(r)* for indirect lingual composite resin veneers *(s). (t and u)* The laboratory-fabricated veneers were designed with a buccal "finger" to facilitate delivery at the correct position. *(v and w)* The lingual veneers were bonded one by one using appropriate adhesive procedures (air abrasion, silane, enamel etching, preheated restorative composite, etc) under strict isolation. Following the delivery of the lingual veneers *(x*, overlay images with veneers on stone cast), the teeth were prepared for labial indirect porcelain veneers *(y*, overlay image of tooth preparations, canine to canine). Note that the lingual margins of the labial veneers terminate in composite resin (schematic cross section in *y*). The patient requested a lighter shade in anticipation of the high-value "veneerlays" planned in the maxillary posterior teeth. The last step of the treatment is the replacement of the mock-ups in the posterior sextants (not illustrated), which can be achieved one sextant at a time, one arch at a time, or one side at a time depending on the clinician/technician's choice. (Case treated in collaboration with Dr Matthew Nejad.)



t.me/Dr_Mouayyad_AlbtousH

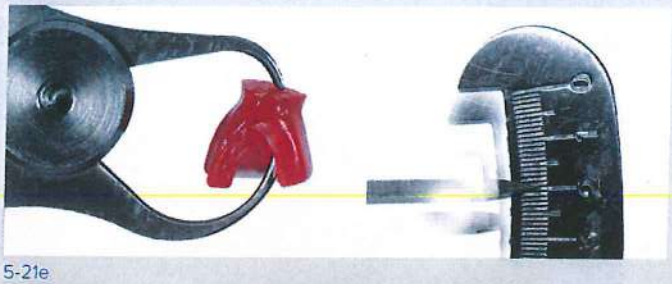

5-21e



5-21f

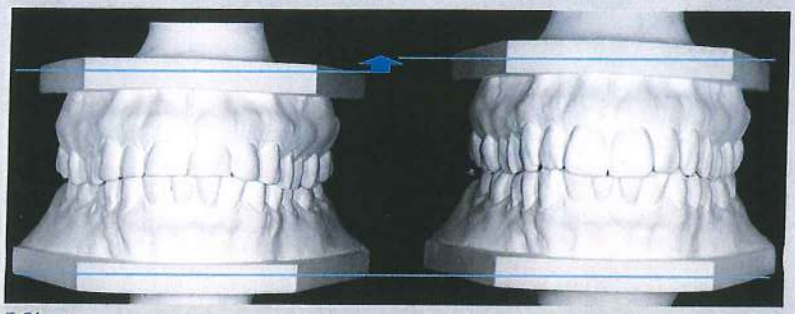

5-21g



5-21h

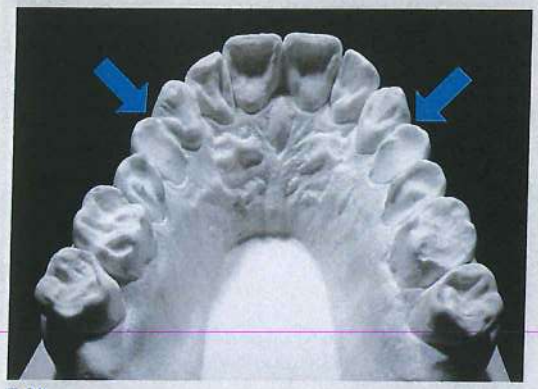

5-21i

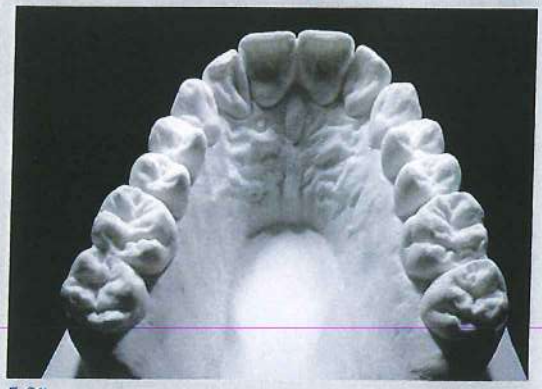

5-21j

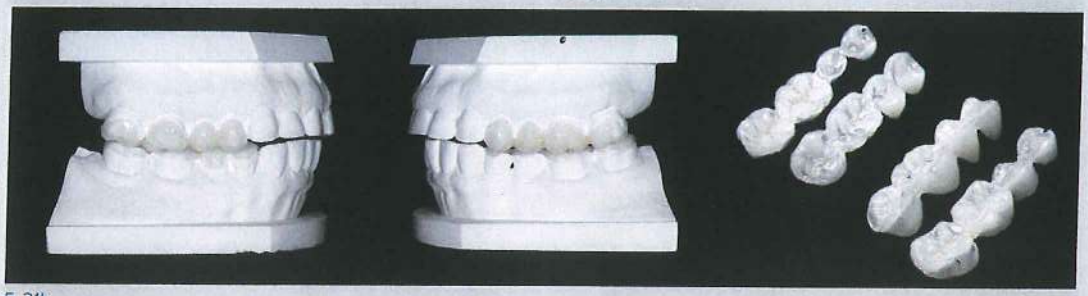

5-21k



5-21l



5-21m



t.me/Dr_Mouayyad_AlbtousH



5-21n



5-21o



5-21p



5-21q

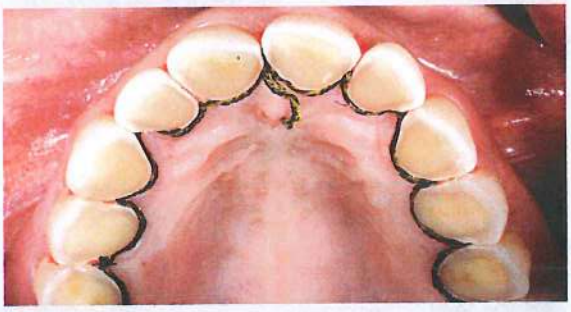

5-21r

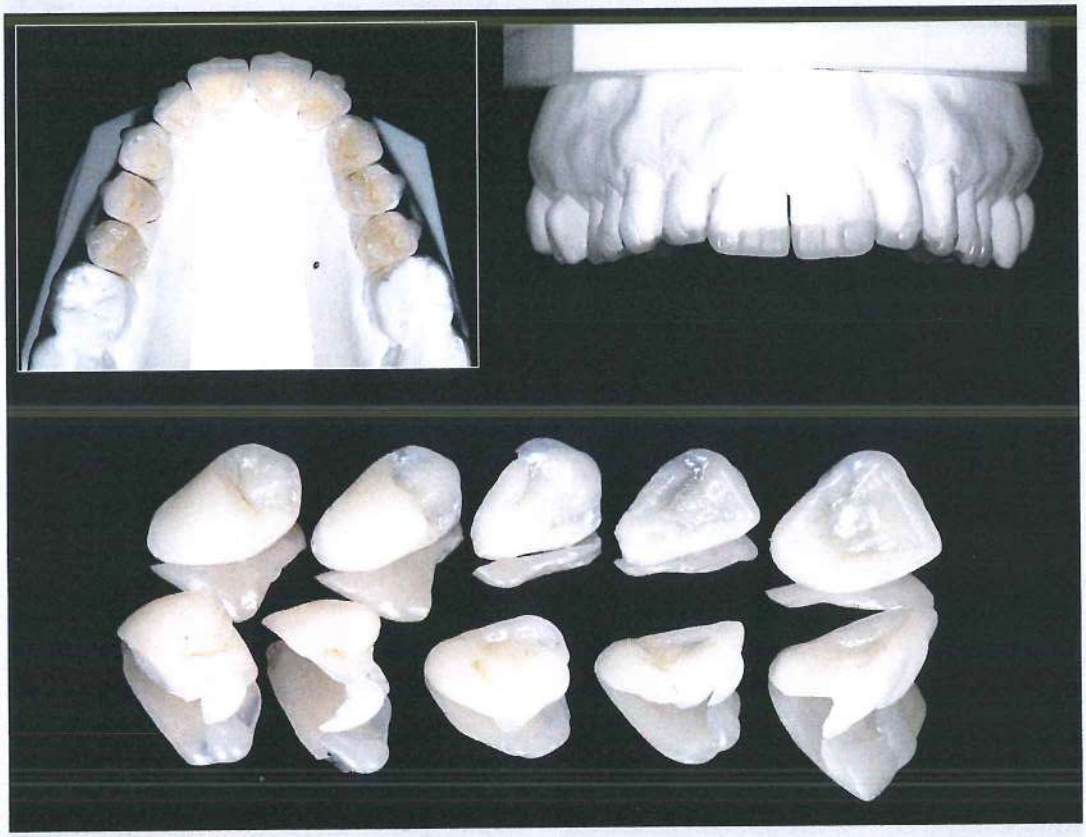

5-21s


t.me/Dr_Mouayyad_AlbtousH



5-21t

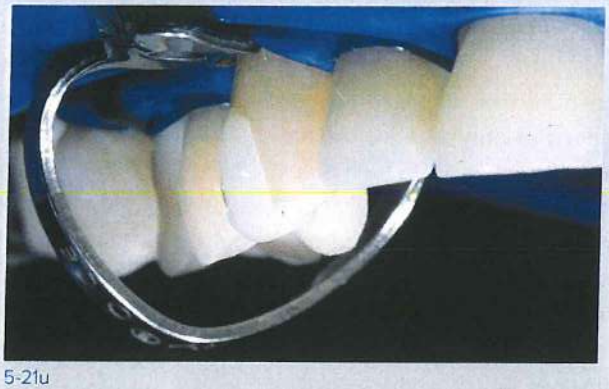

5-21u



5-21v



5-21w



5-21x

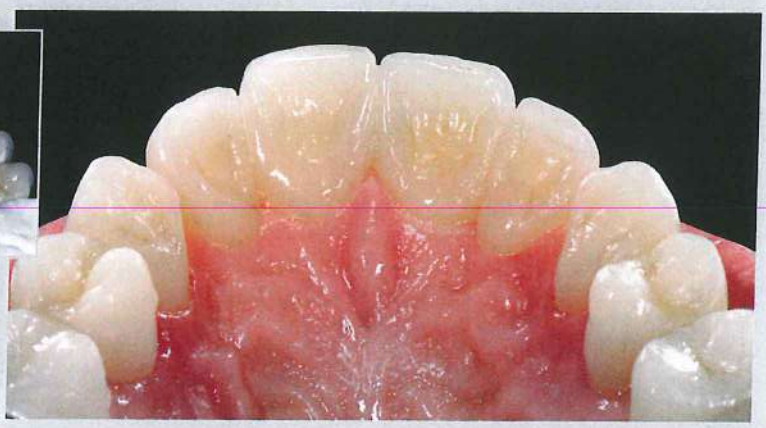






5-21y





t.me/Dr_Mouayyad_AlbtousH

## Extreme applications

Dr Angus Walls in the United Kingdom may have been the first author to suggest extreme applications of nonretentive indirect bonded restorations back in 1995 (see also chapter 6, indications type III, section 6.4).[61,62] Severe cases of wear with total lack of retention and resistance form were treated successfully with nonretentive indirect bonded porcelain up to 15 years. Figure 5-22 depicts a similar patient with severe tissue loss. The case was originally treatment planned by another clinician (4 years earlier) for a classical prosthodontic approach with single crowns on each tooth, requiring multiple periodontal surgeries (with osseous resections), endodontic treatment for post and core restorations, etc. Such a treatment would have been extremely complex, time-consuming, invasive, and costly, and the patient refused treatment. Fortunately, 4 years later, the patient was offered a radically different strategy by Dr Davide Foschi. This adhesive approach was chosen instead, with a 10-mm increase in VDO (at articulator incisal pin). No surgery, no posts, and no root canal therapy were necessary. The treatment cost and timeline could be significantly reduced and simplified. Patient comfort, esthetics, and function were substantially improved through full-arch mock-ups (Figs 5-22l and 5-22m). Each sextant was then restored with single indirect bonded composite resin CAD/CAM restoration using the IDS and even the DME (deep margin elevation) techniques. The anterior restorations were customized with a cutback and an enamel skin (as explained in chapter 4; Figs 4-28 to 4-31). The case stability (mechanics, function, and biology) was confirmed after 6 years of clinical service, pulp vitality was maintained, and only minor repairs were necessary (Figs 5-22w to 5-22y).



5-22b



5-22a



5-22c



5-22d



5-22e



5-22f



t.me/Dr_Mouayyad_AlbtousH



5-22g

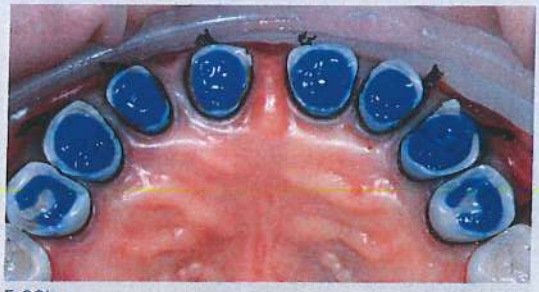

5-22h



5-22i



5-22j



5-22k

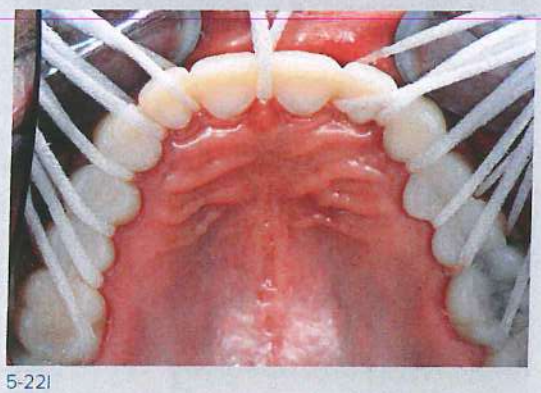

5-22l

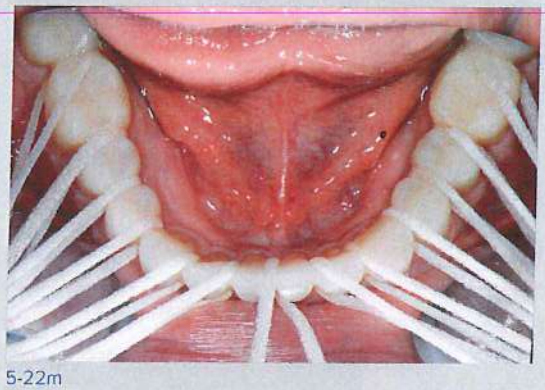

5-22m

**FIG 5-22 Extreme case of full-mouth rehabilitation.** *(a to f)* This patient had previously rejected a classic prosthodontic approach. Biocorrosion and wear are severe and generalized. Clinical evaluation revealed tight lips, collapsed lower third of the face, excellent periodontal status, and no signs or symptoms of temporomandibular joint disorders. The patient consented to a radically conservative approach. Diagnostic casts were mounted at an increased VDO of 8 mm, and full-arch wax-ups were generated by the laboratory. *(g to k)* Because maxillary anterior teeth were the most affected, small adhesive composite resin buildups were fabricated first (note the small "donut-shaped" dentin preparations to increase bonding surfaces). *(l and m)* Those buildups help the stabilization of the first full-arch mock-ups, which were fabricated intraorally in a single appointment (patient instructed for hygiene with Superfloss due to the connections between teeth). The patient confirmed the comfort, esthetics, and functional stability during this first test drive.



t.me/Dr_Mouayyad_AlbtousH



5-22n



5-22o



5-22p



5-22q



5-22r



5-22s



5-22t

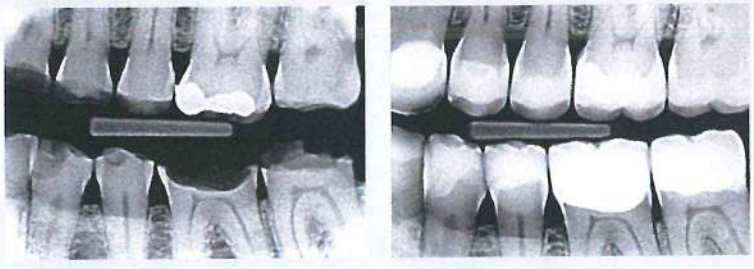

5-22u

**FIG 5-22** *(cont)* The patient was satisfied with the first mock-up, but it was decided that an additional 2 mm would provide better esthetics and clearance for the definitive restoration. Hence, the mock-up was elevated in the posterior teeth by resin additions. *(n)* In the maxillary anterior teeth, the BOPT (biologically oriented preparation technique) was applied through a minimally invasive feather-edge crown preparation design[63] and corresponding laboratory-fabricated provisionals at the new VDO. After another successful assessment, the final restorative phase was completed by the replacement of all mock-ups and provisionals, one sextant at a time. *(o to t)* Indirect CAD/CAM composite resin (Lava Ultimate, 3M) onlays, veneers (mandibular anterior), and crowns (maxillary anterior) were used in conjunction with the IDS (OptiBond FL) and DME techniques. *(u)* Preoperative and postoperative bitewing radiographs reveal the utmost tissue preservation and areas of DME.


t.me/Dr_Mouayyad_AlbtousH




5-22v




5-22w

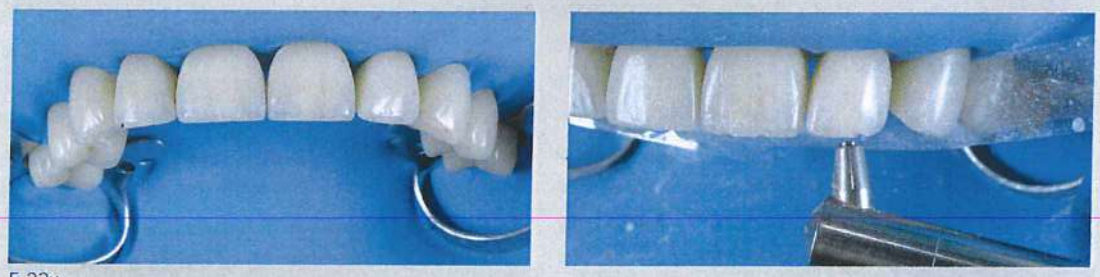

5-22x




5-22y

**FIG 5-22** *(cont) (v)* Postoperative clinical view of the monolithic definitive CAD/CAM composite resin restorations. Only the maxillary crowns were customized by cutback and addition of an enamellike composite resin skin. *(w)* Follow-up views at 6 years of clinical service. The occlusal status (group function) is very stable. The patient wears a protective splint at night (see Fig 5-23, *next page)* and applies remineralizing paste (MI Paste by GC). *(x)* There was only minor chipping of the incisal edges, which was repaired easily (postrepair view in *y*; see technique in chapter 7, Figs 7-4 and 7-5). (Clinical case courtesy of Dr Davide Foschi, Bologna, Italy; laboratory work by Filippo Giacometti; case treated in collaboration with Dr Francesca Vailati and Dr Ignacio Loi.)

t.me/Dr_Mouayyad_AlbtousH



**FIG 5-23 The dental "helmet" for high-risk patients.** Protection of a complex rehabilitation with an occlusal splint will improve the long-term prognosis of the restoration.

### Considerations about restorative materials and wear

When preceded by complete management of the causes of the biocorrosion problem, the treatment of biocorroded teeth with adhesive restorations is well accepted by patients because it is a conservative and esthetic procedure.[64] Preliminary studies seem to indicate that lithium disilicate glass-ceramics and CAD/CAM composite resin materials are both satisfactory candidates for those full-mouth cases.[56-58,65,66] ***Matching antagonistic pairs with similar materials seems to be indicated for wear compatibility. When one arch only is to be restored, the preference will go to composite resins for their better wear compatibility with natural antagonistic enamel (see Fig 4-7).[67] Antagonistic enamel is known to wear significantly more than ceramic.[68]***

In a number of those cases with generalized loss of tooth structure, mandibular anterior teeth are near-intact and do not need to be restored. Hence, composite resin lingual restorations or composite resin veneers on anterior maxillary teeth are preferred as antagonists. In the medium to long-term, wear of composite resins might occur, which was once considered a major concern for posterior restorations. This problem has been substantially reduced by changes in formulation. It is considered today by many to be a solved problem, especially in patients without bruxing and clenching habits.

### Occlusal splint, or the dental "helmet"—Maintenance

For patients with parafunctional behavior, supplemental protection with an occlusal splint (Fig 5-23) is recommended, regardless of the restorative material. Those patients should be monitored carefully because of the increased risk of wear-related failures.[69,70] However, due to the conservative nature of the treatment and successful reparability with composite resin, most chipping and fractures can be easily addressed. ***"Touch-up" treatments by surface roughening (diamond bur cutting and air abrasion with aluminum oxide or by tribochemical silicoating) followed by the use of a bonding resin with silane/MDP provide strong repair bonds.[71]***

## Restorative strategies—Class III occlusion

Some patients may present with a Class III malocclusion along with a presumed collapse of VDO (Figs 5-24 to 5-26). Opening the bite can resolve the Class III (by generating a positive overjet) while providing significant restorative space in the posterior area (Fig 5-24). Deprogramming may be used to provide additional overjet.


t.me/Dr_Mouayyad_AlbtousH

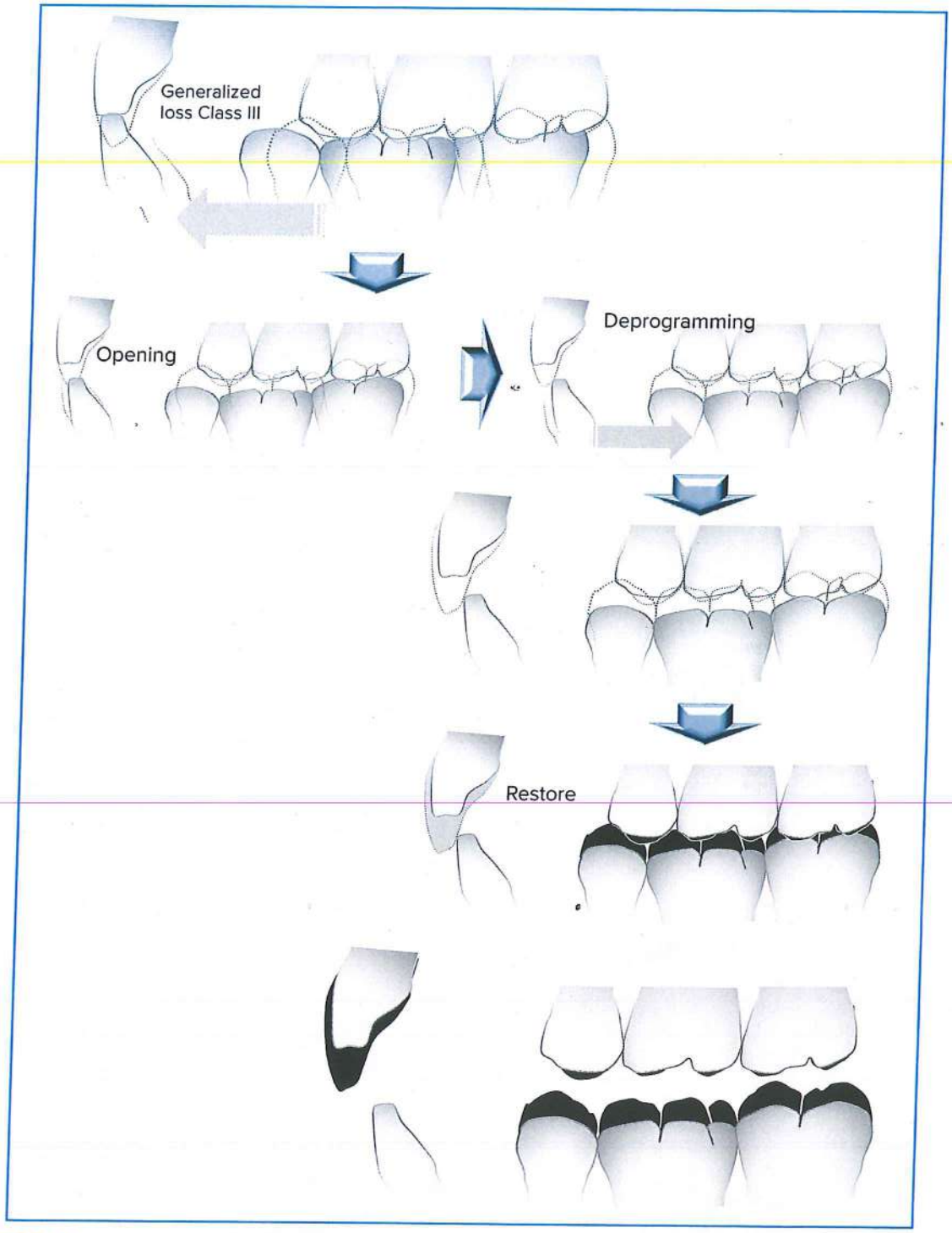


**FIG 5-24 Treatment planning for Class III occlusion.** This figure summarizes the therapeutic approach that was used for the patient in Figs 5-25 and 5-26. Diagnostic casts were mounted in an opened position using a jig. Deprogramming of the bite by the jig provided some additional posterior shifting of the mandible to secure an overjet. The new anterior relationships then allowed for longer maxillary incisors. The bite was kept open at this vertical dimension by a medium-term mock-up while posterior teeth were restored. As explained in Fig 5-18, the posterior restorative space can be allocated mainly to the most severely affected arch (in this case the mandibular teeth) or distributed more evenly, depending also on occlusal plane relationships (compare B1 and B2 in Fig 5-18).


t.me/Dr_Mouayyad_AlbtousH

***For the patient in Figs 5-25 and 5-26, a low-cost approach had to be chosen (due to the patient's financial limitations), using a full anterior maxillary mock-up (canine to canine, buccal and lingual) to keep the bite open while restoring the posterior teeth with direct and semi-indirect composite resin restorations.***

The case was completed by replacing the maxillary anterior mock-up with large direct composite resin restorations using the natural layering technique described in chapter 3 (see Fig 3-48). As a result of the treatment, the patient was placed in a new position called DPR, or deprogrammed, passively retruded position (see also Fig 5-27).



5-25a



5-25b



5-25c



5-25d



5-25e



t.me/Dr_Mouayyad_AlbtousH



5-25f

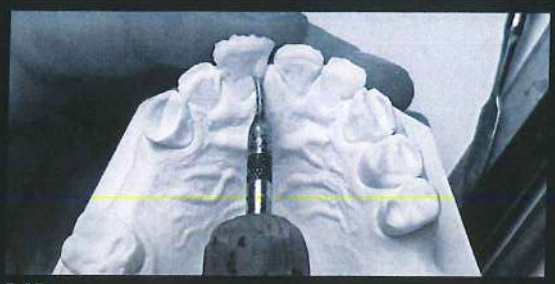

5-25g

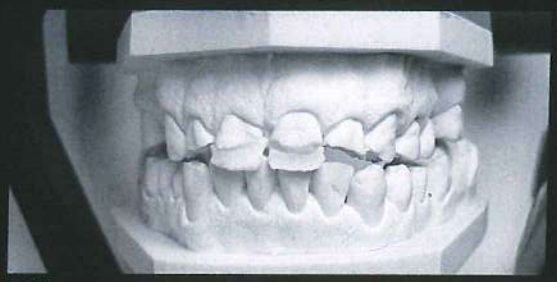

5-25h



5-25i

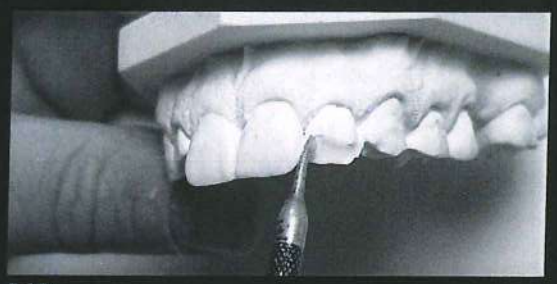

5-25j



5-25k

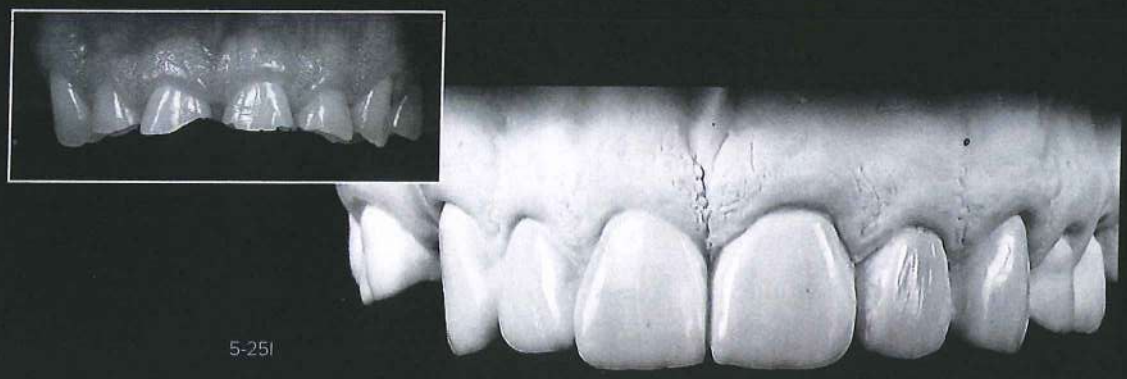

5-25l

**FIG 5-25 Low-cost treatment of severe biocorrosion/wear with Class III occlusion.** *(a to d)* This patient is missing three maxillary teeth and presents with generalized biocorrosive wear similar to that seen in Fig 5-22. The collapse of the bite has generated a Class III malocclusion. Large amalgam restorations are breaking down on mandibular molars *(d)*. The initial goal set with the patient was to stabilize and restore the existing teeth at the most affordable cost to allow future financial planning for implants. *(e)* The first step was to passively deprogram and register the bite at an opening that would provide clearance for a minimum overjet and overbite (with deprogramming jig in place during bite registration). *(f to l)* This attempt proved appropriate to generate a full wax-up (buccal and lingual) with longer maxillary anterior teeth (overlay image in *l* for comparison with preoperative situation). Diagnostic cast fabrication and mounting are detailed in Fig 5-6.



t.me/Dr_Mouayyad_AlbtousH



5-25m



5-25n



5-25o



5-25p



5-25q



5-25r



5-25s



5-25t



5-25u

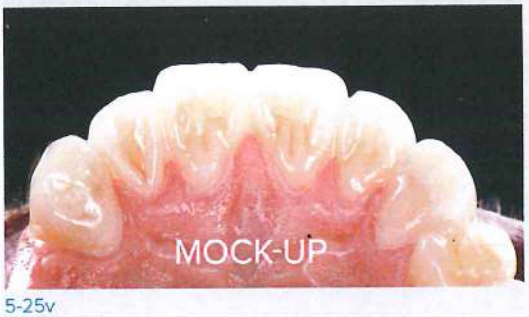


5-25v


t.me/Dr_Mouayyad_AlbtousH



5-25w

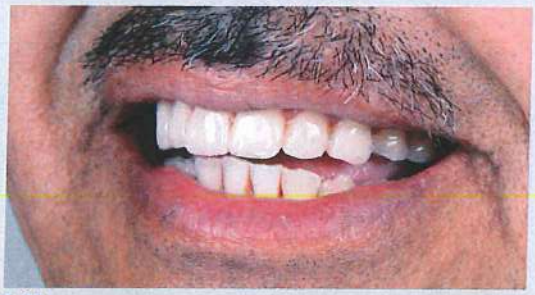

5-25x



5-26a



5-26b



5-26c

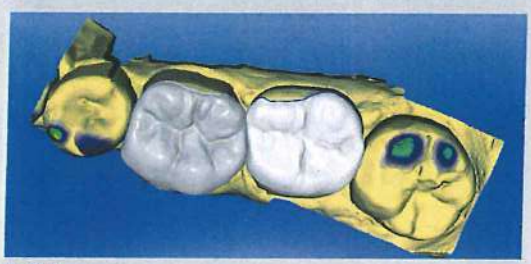

5-26d



5-26e



5-26f

**FIG 5-25** *(cont) (m and n)* Clinical work started with the fabrication of an intraoral mock-up. Silicon indexes revealed missing space in a few locations, mainly lateral incisors, which required some adjustments *(o)*. Because the mock-up would be used for a few months, all exposed dentin surfaces were roughened with a diamond bur *(p)* and sealed with a three-step, total-etch dentin bonding agent *(q and r*, IDS technique). *(s)* The mock-up was secured mainly to labial enamel by spot-etching (IDS surfaces were isolated with petroleum jelly to avoid adherences). *(t to v)* PMMA resin was used with colorants and glazed as previously explained. The patient was instructed to clean the gingival embrasures with Superfloss *(w)* and was thrilled with the recovery of his smile *(x)*.

**FIG 5-26 Definitive restorations for the case shown in Fig 5-25.** No posterior mock-ups were used in this case. *(a to c)* The posterior teeth were brought back into occlusion with freehand composite resin restorations on all premolars and maxillary molars *(see next page)*. *(d to h)* Semi-indirect CAD/CAM composite resin onlays (in combination with IDS and DME techniques) had to be used on the mandibular first and second molars due to the extensive damage of those teeth.



t.me/Dr_Mouayyad_AlbtousH



5-26g





5-26h

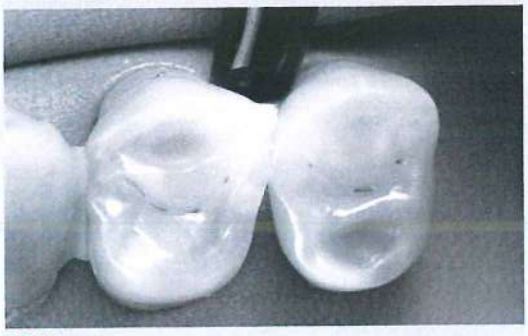

5-26i

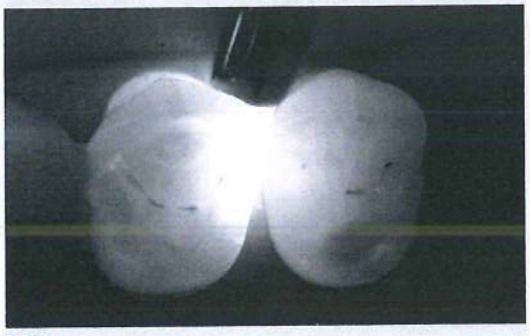

5-26j



5-26k



5-26l



5-26m



5-26n



t.me/Dr_Mouayyad_AlbtousH



5-26o



5-26p



5-26q



5-26r



5-26s



5-26t





5-26u



5-26v

**FIG 5-26** *(cont) (g and h)* Restorative work at the mandibular arch was completed first (overlay image with preoperative view for comparison). *(i to n)* The maxillary posterior teeth received only direct composite resins to restore missing cusp tips and provide appropriate posterior support (see also *u*; all possible occusal contact restored). Note the use of transillumination (Microlux, AdDent) to assess and monitor the depth of interdental lesions often present in these cases *(j)*. *(o to t)* The maxillary anterior mock-up was used during the entire posterior restorative phase and was finally replaced by large direct composite resin restorations (mock-up removed and replaced in three sessions, two teeth at a time). *(u and v)* This first low-cost restorative phase placed this patient in a stable interim situation with a new bite (preoperative overlay image for comparison) while allowing time for financial planning for future implant-supported restorations to replace the missing maxillary teeth. (Case treated in collaboration with Dr Jonathan Dye and Dr Thi Dao.)



t.me/Dr_Mouayyad_AlbtousH

The patient in Fig 5-27 also features a Class III malocclusion but only a moderate generalized loss of tooth structure. A low-cost approach was also requested by the patient, as well as a minimum number of sessions possible due to her job limitations. The same strategy was used as for the patient in Fig 5-26—ie, ***opening and deprogramming of the bite, maxillary anterior wax-up and mock-up at the opened bite. The mock-up was used to maintain the new reference bite while restoring the posterior teeth with small direct composite resins***. In this case, the mock-up was replaced with "taco-shell" (V-shaped, one piece buccal and lingual) semi-indirect composite resin veneers: The mock-up was scanned as a Biocopy reference for monolithic CAD/CAM restorations mimicking exactly the shape of the mock-up. The case required only five main clinical sessions.

## Conclusion

***While the severe loss of enamel constitutes an alteration to the function, mechanics, and esthetics of anterior teeth, it is also an opportunity for additive (unlike subtractive) restoration of the missing hard tissues. Traditional full-crown coverage should be avoided in all cases in favor of noninvasive approaches combining additive bonded composites and ceramic veneers. The combined use of physiologic deprogramming and the Dahl principle will assist in creating adequate anterior restorative clearance in cases with "tight bites" (deep bite or Class III).***

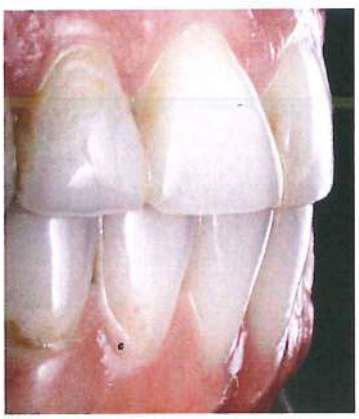

5-27a



5-27b



5-27c



5-27d

**FIG 5-27 Five-step low-cost treatment of moderate biocorrosion/wear with Class III occlusion.** *(a to f)* The patient presents with Class III malocclusion and an inverted smile line, and the biocorrosion/wear is moderate except on the lingual surfaces of maxillary anterior teeth with large dentin exposures. The mandibular teeth are only remotely affected *(f)*. Edge-to-edge relationships *(c)* do not currently allow the necessary increase of incisor length. *(g)* The bite was registered at an opened, ***deprogrammed, and passively retruded (DPR) position***. *(h)* The original bite *(top left)* is significantly changed by the deprogramming, which is now creating a slight opening *(top right and bottom left)* due to two premature retruded contacts in the molar area *(blue arrows, bottom right)*. The retruded posterior contacts, along with the future anterior mock-up, will become the centric stops for the new bite (DPR position).



t.me/Dr_Mouayyad_AlbtousH



5-27e



5-27f

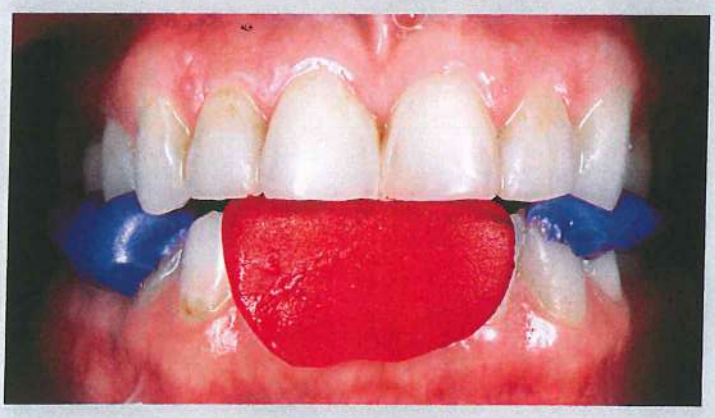

5-27g

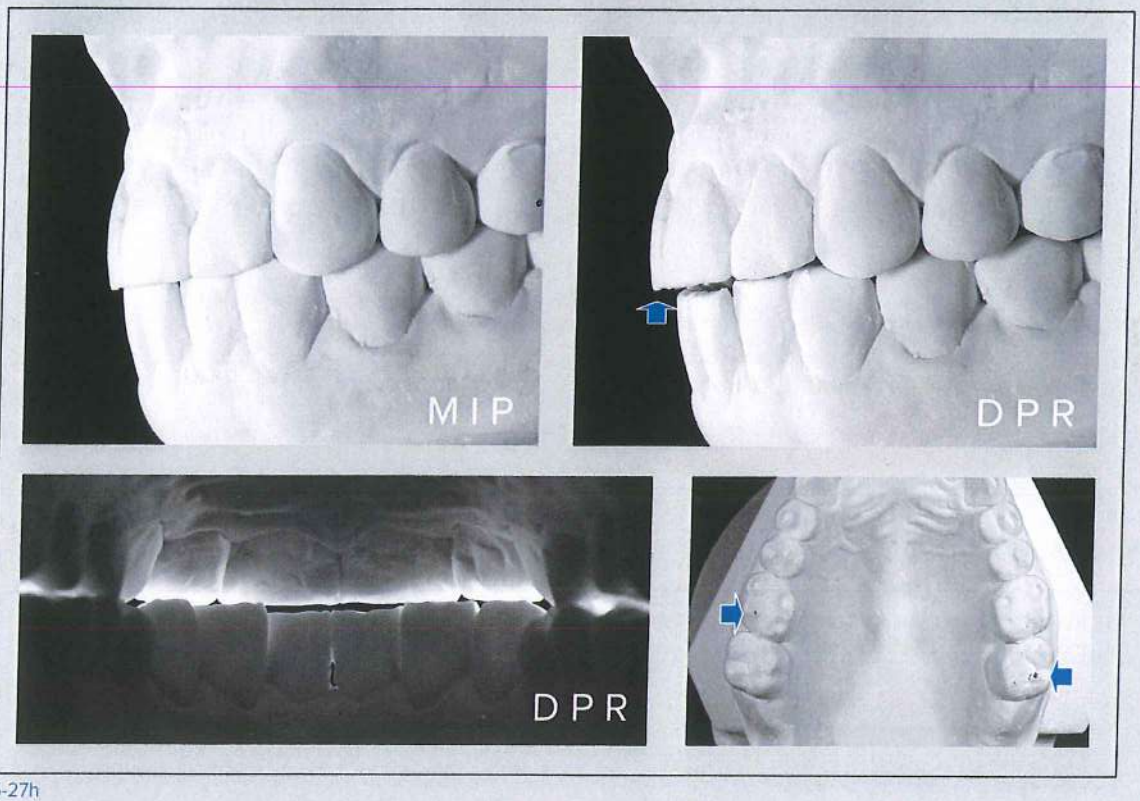


5-27h



t.me/Dr_Mouayyad_AlbtousH

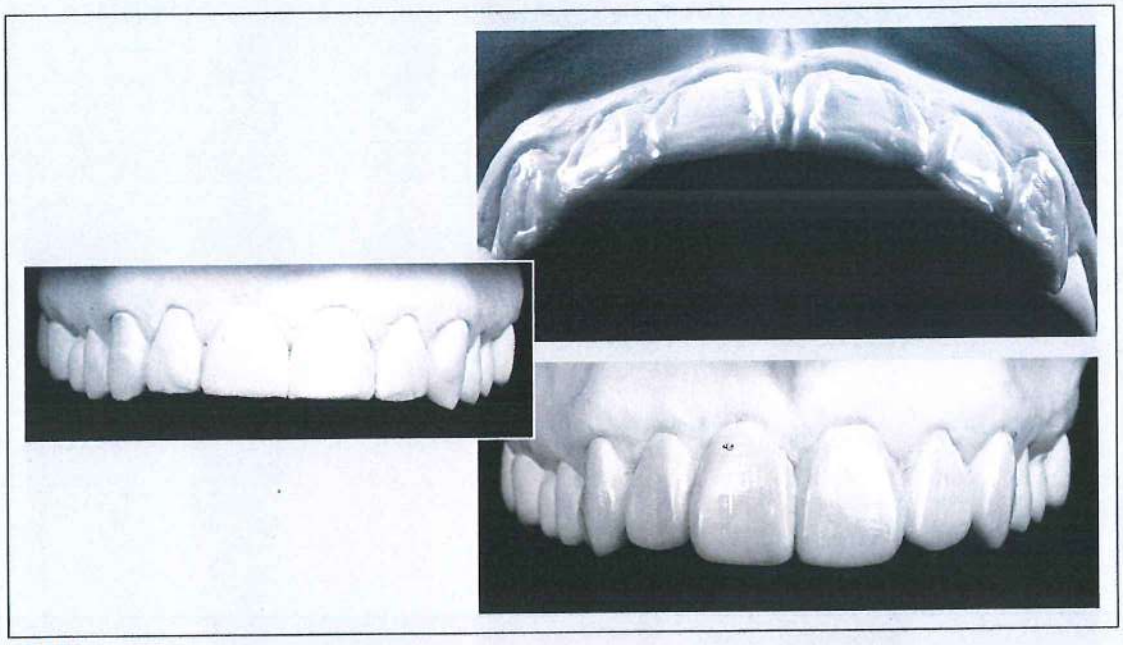

5-27i



5-27j



5-27k



5-27l



5-27m

**FIG 5-27** *(cont) (i)* A full anterior maxillary wax-up was produced at the new reference position (DPR), allowing for longer incisors because of the slight overjet of the passively retruded bite (overlay image with preoperative situation for comparison). *(j)* It is recommended to replace defective composite resin restorations before proceeding with the mock-up. *(k)* A full-coverage silicon index had to be used because the PMMA mock-up is restoring the full buccal and lingual anatomy *(l and m)*. *(n)* The new volumes were approved by the patient (preoperative overlay image for comparison) with only minor modifications. *(o and p)* The repositioned bite is exactly as planned, using the DPR premature contacts as the new MIP contacts *(blue arrows;* compare with *h, bottom right)*. *(q)* Missing cusp tips were restored into occlusion with small direct restorations *(left and center)*; note all the restored contacts as per the post-operative bite registration *(right)*.


t.me/Dr_Mouayyad_AlbtousH





5-27n

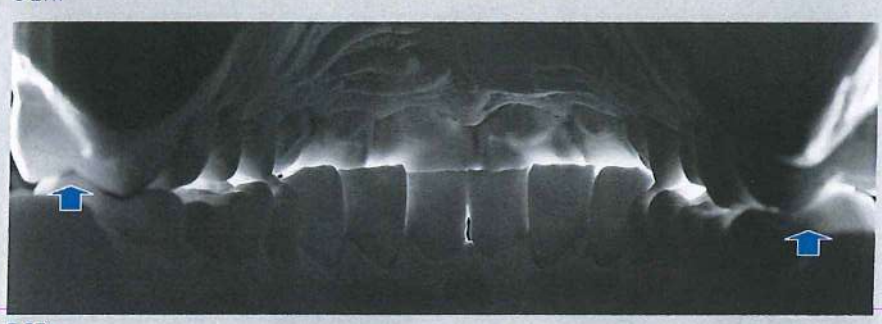

5-27o

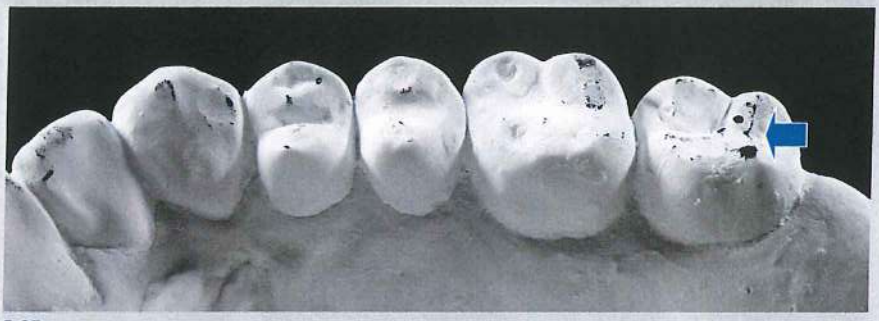

5-27p

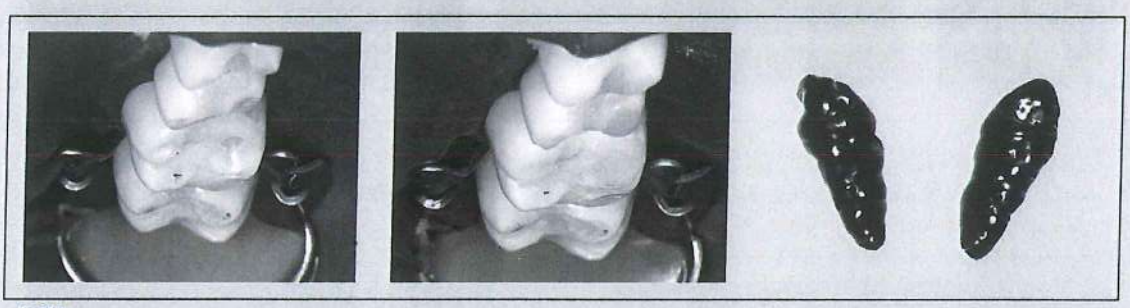

5-27q



t.me/Dr_Mouayyad_AlbtousH

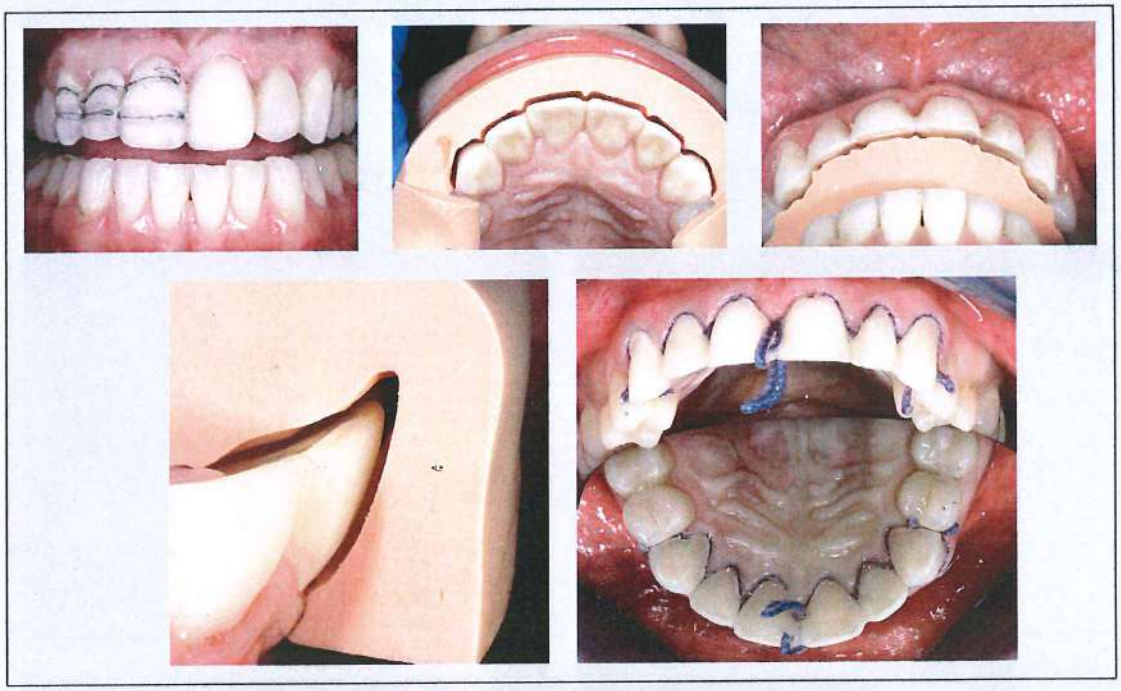

5-27r

## "TACO SHELL" V-SHAPED VENEERS

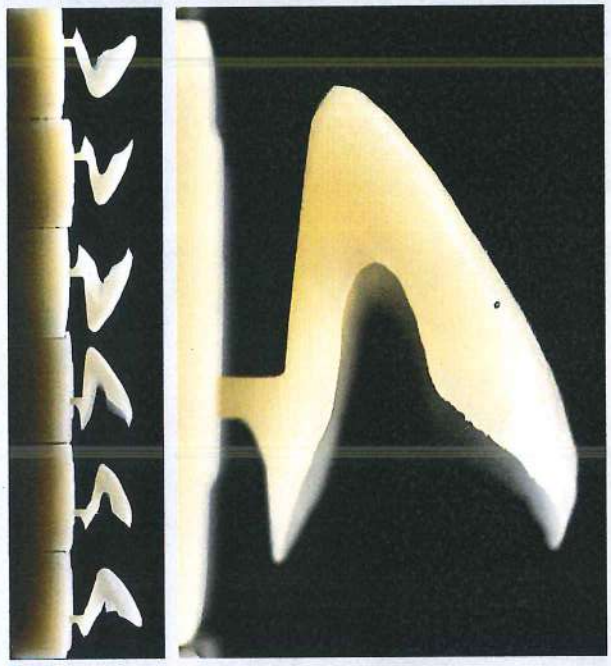

5-27t

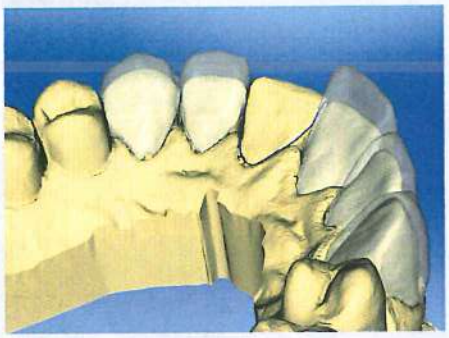

5-27s

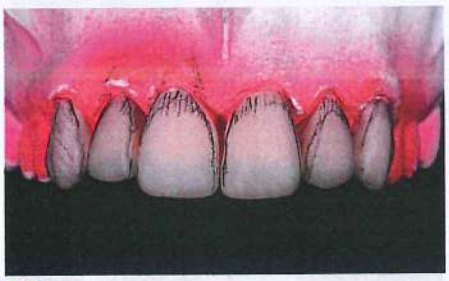

5-27u

**FIG 5-27** *(cont) (r)* Minimally invasive preparations were guided by the mock-up *(top left).* Most of the restorative space was provided by the removal of the mock-up *(top center and right).* The buccolingual cross section of the silicon index reveals uniform clearance for CAD/CAM composite resin V-shaped veneers *(bottom left).* The clinical view just before final impression is shown at bottom right. *(s)* The modified mock-up (with less ovoid shapes as per the patient's request) was replicated using the Biocopy module in the CEREC system. *(t)* Note the ultraconservative design of "taco-shell" veneers, which leaves the interdental tooth surfaces intact. *(u)* Final adjustment and fit is checked on the stone cast.


t.me/Dr_Mouayyad_AlbtousH

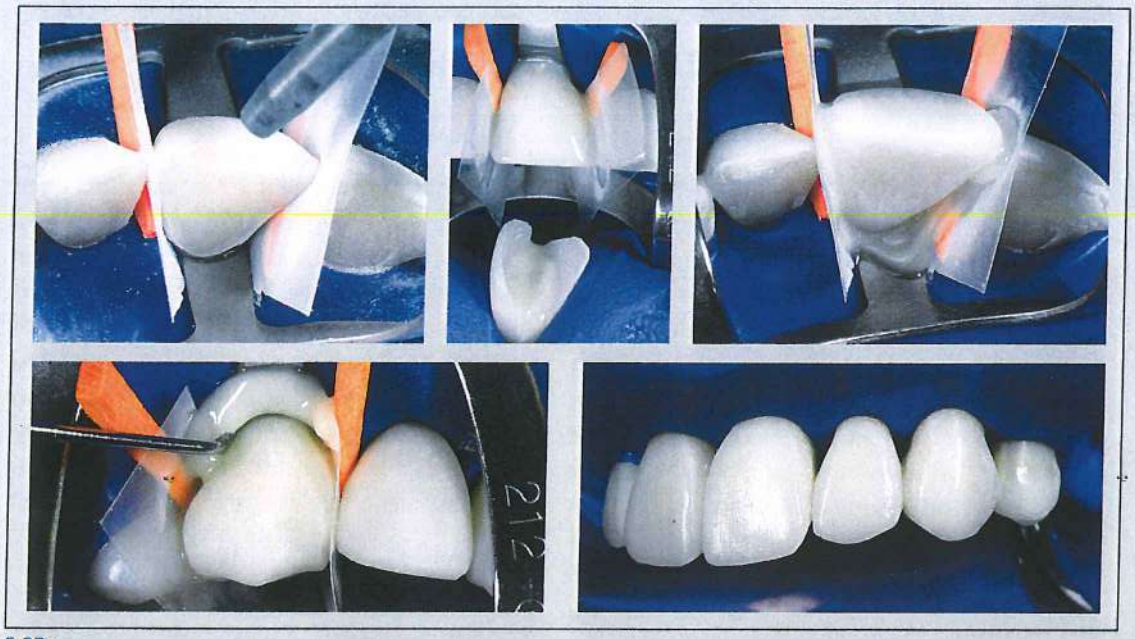

5-27v



5-27w



5-27x





5-27y

**FIG 5-27** *(cont) (v)* The veneers were delivered one by one with a preheated restorative composite resin according to the procedures described in chapter 4, Fig 4-29. Surface texture and polishing were then carried out intraorally as per the procedures described in chapter 3, Fig 3-50. *(w)* Postoperative view of the smile. *(x)* Note the polychromatic behavior of the veneers (cervical aspect showing more saturation due to minimal thickness) despite their uniform structure (no cutback or coloring were applied as per the patient's request). *(y)* Final intraoral view showing satisfying color integration of the monolithic veneers (overlay image of preoperative situation for comparison).



t.me/Dr_Mouayyad_AlbtousH

# 5.9 BASICS OF DIGITAL DENTAL PHOTOGRAPHY

Only a limited number of all the aforementioned objectives would be possible without use of adequate clinical photography equipment. As the saying goes, "A picture is worth a thousand words," and that powerful principle can be used to optimize communication. Ideally, both the operatory and the laboratory should have the same equipment, especially in the case of so-called "teledentistry"—ie, when the laboratory is located in another building, city, state, or country. In this situation, photographs, when taken appropriately (eg, using the eLAB system; see Figs 5-34 to 5-36), will save the patient a number of visits to the laboratory. Today, virtually all digital single lens reflex cameras (DSLRs) are suitable for dental photography, and the same is true for mirrorless interchangeable lens cameras (MILCs). They are used in combination with suitable macro lenses, with focal lengths ranging from 60 to 105 mm and a life-size reproduction ratio (1:1), as well as a suitable ring or lateral flash system for close-up photography (Fig 5-28). Various accessories are available to provide diffuse illumination for reflected photography, to curve the light toward the optical axis to improve lighting effects when taking extreme close-up shots (ie, for posteriors) and to eliminate surface gloss using cross-polarization filters.

## The DSLR/MILC setup

There are many approaches to set up the light exposure mode of DSLR/MILC cameras. For everyday photography, it is recommended to use the "A" mode of exposure with priority to aperture (or f-stop). This will enable manual selection of different apertures generating different depths of field. Intraoral images usually require high f-stops (high depth of field, eg, 32), while portrait photography may benefit from small f-stops (eg, 2.8 with less depth of field for more ambient shots). One important feature is the ability to read flash on the sensor plane of the camera and set the proper flash intensity for correct exposure. This essential feature is called "through the lens" (TTL).

### Film speed or ISO

The ISO is also an essential adjustment to increase the light sensitivity of the sensor. ***Low ISO (eg, 100–300) make the image darker and therefore require longer exposure times (slow speed) but provide improved image quality.*** High ISO (eg, > 1600–3200) make the image brighter and require shorter exposure times (high speed), but images have more noise/grain. Increased ISO may be used to maintain focus depth (higher f-stops) in low-light conditions (indirect views in mirrors, etc) or for video recording in ambient conditions.

### FX/DX

***The first decision that will significantly influence the cost and quality level of the equipment is the choice of the sensor size, which can be 24×16 mm (designated DX) or full frame 36×24 mm (designated FX as it matches the size of previous film photographs). DX cameras, with a 1.5× crop factor, are lighter and much more affordable than FX ones.*** FX cameras require compatible FX lenses, which are also

**FIG 5-28 Basic photographic equipment recommended for esthetic dentistry.** *(a)* FX cameras are recognized by their logo. *(b)* They can also be used with a 1.5× crop factor in DX mode. This feature can be activated when shooting posterior teeth or to obtain higher magnification factors. *(c)* The full-frame system comprises an FX DSLR body (D610, Nikon, CMOS 24.7-million-pixel sensor), a dual-point light (R1 Wireless Close-Up Speedlight System, Nikon, TTL compliant), a 105-mm macrolens (AF-S VR Micro-Nikkor 105mm, Nikon), and various types of reflectors (see Figs 5-29a and 5-30a). A high-end system would call for a 45.7 MPa BSI-CMOS sensor, such as the D850 body (Nikon), allowing for high-resolution images even after cropping or activating the DX mode.





t.me/Dr_Mouayyad_AlbtousH




5-28a




5-28b

## FULL-FRAME SYSTEM



a. FX CAMERA

b. 105-mm LENS

c. TWIN LIGHT

d. REFLECTOR SYSTEMS

5-28c



t.me/Dr_Mouayyad_AlbtousH

more expensive but produce more "light gathering" area, higher sensitivity, and less noise (Fig 5-28). FX cameras can be used with DX crop mode, which is a useful feature for images taken in a mirror or for higher magnification effect (eg, posterior teeth; Fig 5-29).

## The lens

An adequate focal length for anterior clinical dentistry seems to be 105 mm, which allows for an optimal working distance and minimum image distortion when using an FX camera. A low-cost alternative with a 60- to 85-mm focal length and a DX camera would produce images with a similar format as the 105-mm/FX combination. The lens must offer a 1:1 magnification ratio, which can be easily increased to 1:1.5 with an additional close-up lens. Maximum depth of field is obtained by selecting a large f-stop of f22–f32.

***A 2× teleconverter can be attached to obtain a 1:2 reproduction ratio (Fig 5-29); in this case, more light is needed, hence the ISO must be increased and/or the f-stop must be decreased (eg, to f16), inducing a possible reduction in depth of field.***

The 105-mm lens can be used alone (ie, without additional lenses) for patient portraits; for this specific situation, an aperture between f2.8–f5.6 is selected, giving a soft ambience (blurred background because of the reduced depth of focus), enabling the use of indirect lighting (eg, flash directed toward white ceiling and/or or a light disc) in spite of the increased working distance. The use of automatic focusing (AF) is highly recommended for portrait photography, with the focus point on the smile.

## LOW-COST SYSTEM




5-28d

**FIG 5-28** *(cont) (d)* This DX system is much more affordable compared to that in *c* and consists of a DX DSLR body (D7200, Nikon, CMOS 24-million-pixel sensor), the same twin light system, and an 85-mm macrolens (AF-S Micro-Nikkor 85mm, Nikon).

**FIG 5-29 Configuration of equipment recommended for posterior indirect photographs (with mirrors).** For occlusal intraoral photography, the DX mode is recommended because the crop factor compensates for the increased distance when using an intraoral mirror. The R1 flash includes close-up reflectors *(* in a)* to improve light penetration in the back of the mouth by moving the light nearer to the lens. Quadrant photography can be easily obtained without accessories in FX mode *(b)*, but higher levels of magnification will require DX mode *(c)* and possibly a 2× teleconverter (eg, Series 1, Vivitar) to double the focal length *(d)*. This optical component is inserted between the lens and the body and converts the focal length from 105 to 210 mm. Posterior indirect photography often requires the ISO to be increased and/or the f-stop to be decreased (eg, to f16) in order to obtain proper illumination.



t.me/Dr_Mouayyad_AlbtousH




DX MODE

a. 105-mm LENS ×1:1
b. Close-up lens ×1:1.5
c. 2× converter ×1:3

TWIN LIGHT
+ * Close-up reflectors

5-29a

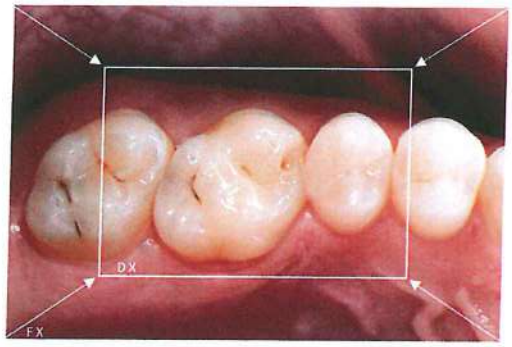


5-29b

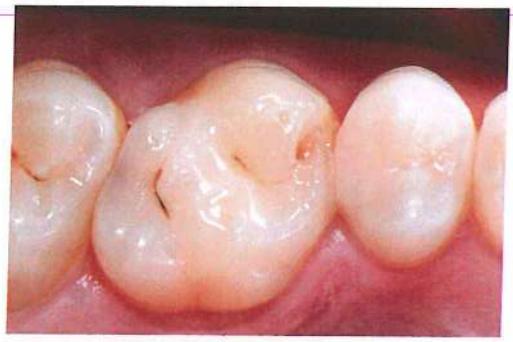

5-29c



5-29d






+ 2X CONVERTER



t.me/Dr_Mouayyad_AlbtousH

## The flash system

Twin light systems represent an ideal compromise to simultaneously provide adequate distribution of light yet allow fine 3D reproduction of tooth volumes (Fig 5-30).

The flash must be compliant with the TTL system, which controls exposure. Typical lighting for macrophotography includes either twin light or ring light. These two light sources present fundamental differences and are used for two different purposes. The following general principles must be known (Fig 5-30c):

- The twin light is a 3D light that generates shadows, optimally revealing texture, shape, and contour; it is best used for anterior intraoral views, smile views, facial views, and images of casts (including laboratory work).
- The ring light generates a directional and shadowless light that hides no part of the subject; it is best used for surgery, posterior intraoral mirror photographs, and pathology photography.

Electronic flash systems have a color temperature around 5600K (5560K seems to be a good setting for the system presented in Fig 5-30).

## Future trends

Mobile devices and smartphones are equipped with cameras of increasing quality. They can be very useful for communication with the patient and the dental laboratory when combined with a dual accessory LED light source (eg, Smile Lite MDP by Smile Line) and the corresponding diffusers and cross-polarization filters.[72] Cross-polarization filters are an essential tool when it comes to shade analysis and selection and exist also for DSLR (polar_eyes by Emulation; see Fig 5-34a).




5-30a

**FIG 5-30 Configuration of equipment recommended for anterior direct photographs.** For anterior intraoral photography, the FX mode is recommended (especially when using a 105-mm lens). Accessory diffusers *(* in a)* will help generate larger reflective surfaces to reveal the 3D nature of the tooth by outlining the mesial transition line angles *(dotted areas in b)* while providing adequate perception of enamel surface texture *(dotted ovals in b)* and even gingival texture. *(c)* Comparative views were made using a ring light: Note the flatness of images produced with ring light *(right side)* compared to that generated by twin light *(left side*, close-up twin flash; eg, EM-140 DG, Sigma).



t.me/Dr_Mouayyad_AlbtousH



5-30b

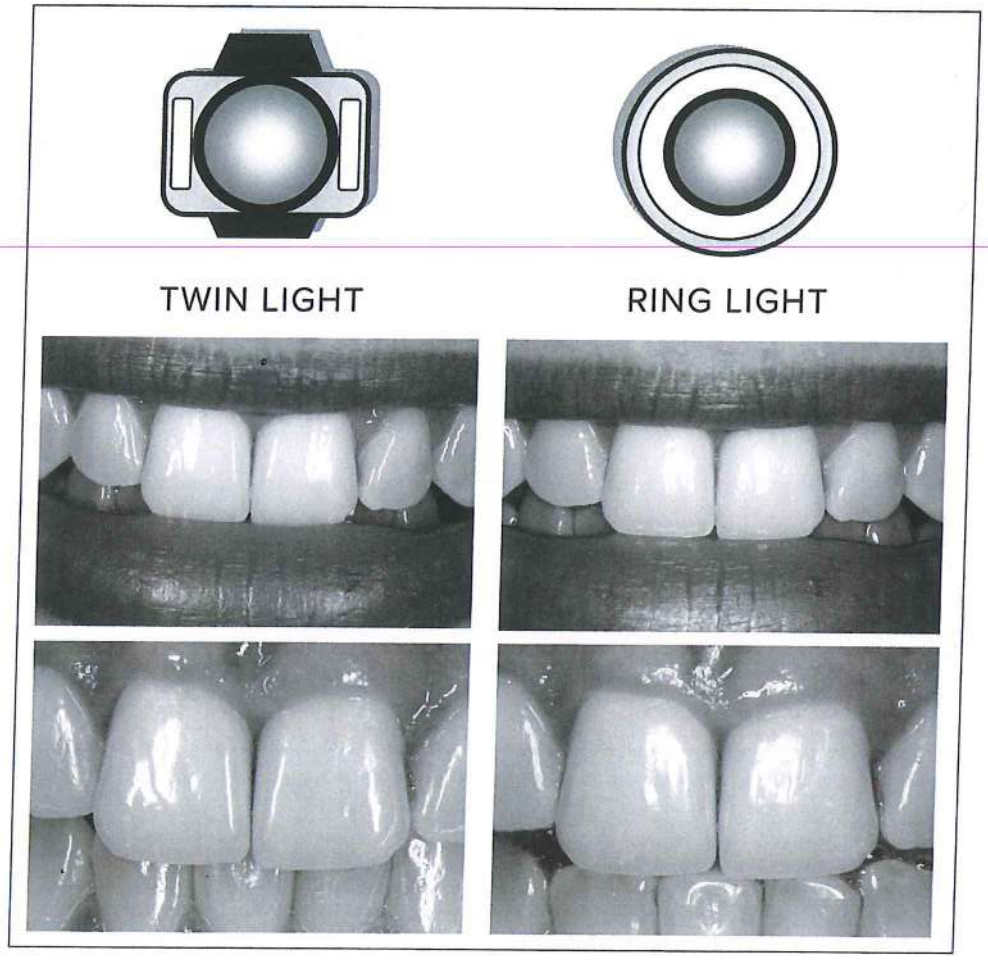


5-30c



t.me/Dr_Mouayyad_AlbtousH

# 5.10 SHADE DOCUMENTATION/COMMUNICATION

It is not the aim of the present section to cover the extensive topic of color in dentistry but simply to provide the reader with some principles that may generate significant improvements.

First, all dental laboratories should include a workplace that can be used for the documentation of shade (Fig 5-31). Both the dentist and the dental technician should be involved; although it seems primarily necessary for the dental laboratory (see Table 5-1), some cases can be solved when adequate shade documentation has been performed by the dentist alone (yet complemented by a ceramist/patient virtual meeting), especially when the dental laboratory is in another city, state, or country.

For decades, color selection has remained a subjective process. As discussed in chapter 2, color is not the major element of esthetic success in a restoration, unless dealing only with a single central incisor. Such cases are ideal for the objective eLAB protocol discussed at the end of this section (see Figs 5-35 and 5-36). The future surely lies in this automation of shade selection through multifunctional innovative tools, including digital cameras, special filters, and software. The tools may evolve, but some basic principles will remain unchanged. These principles have been integrated in a rational approach using readily available tools: *(1)* digital photographs, *(2)* shade tabs, and *(3)* a shade-mapping sheet.

## Principle 1: Using multiple light sources

***For each patient, the operator (either clinician or technician) should try to understand and document color (tooth-light interactions), rather than select the shade.*** This ideally implies using various lighting conditions (Fig 5-32), for example daylight, artificial light, and flash from intraoral photographs. There are fundamental differences in the photopic behavior of diffusely scattering media. Various tooth-light interactions, however, will reveal much more than just shade, also including surface texture, gloss, etc.

**FIG 5-31 Shade documentation workplace in a dental laboratory.** This "patient's place" includes a disinfecting device, a commercial shade guide, a shade selection sheet and custom shade tabs, an artificial ring light, and examination gloves (depicted here: Oral Design Center, Montreux, Switzerland, 1993).

**FIG 5-32 First principle for shade documentation.** Dynamic optical behavior implies that ceramics and teeth can match under one light condition but not under another. Because of this, shade selection must be performed with more than one light source. Natural daylight seems ideal but varies according to atmospheric conditions. Artificial lights are stable and consistent, especially for digital photographs that exclude the intrinsic variability of prior film processing.



t.me/Dr_Mouayyad_AlbtousH




5-31

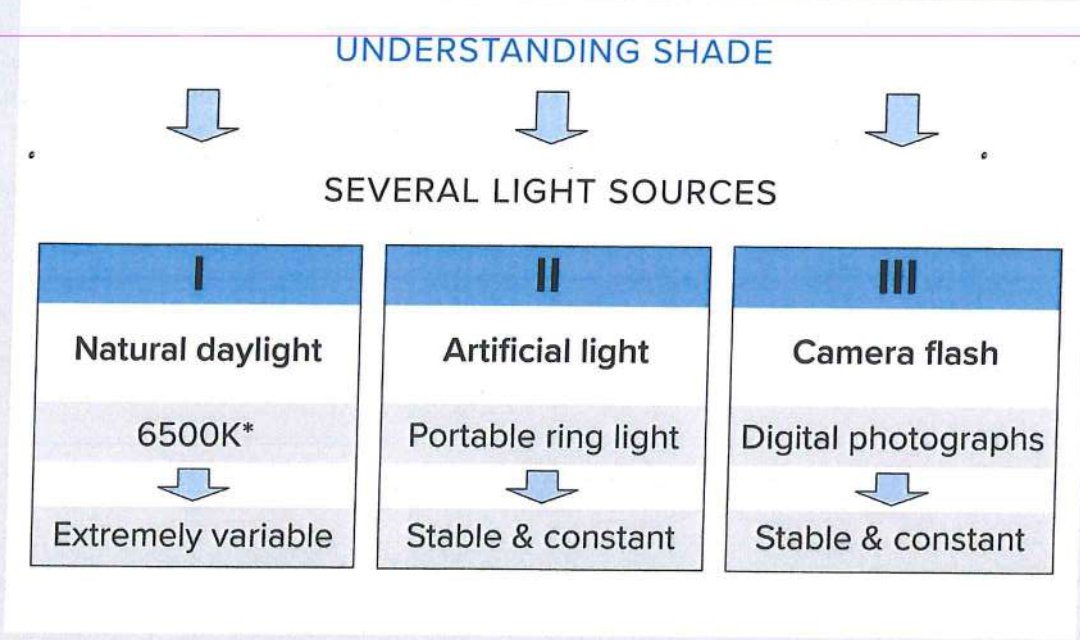


5-32

*Natural daylight itself is variable, ranging from about 1850K (sunrise/sunset) to 5000K (horizon daylight) to 5600K (vertical daylight, similar to electronic flash) and up to >6500K (overcast daylight).


t.me/Dr_Mouayyad_AlbtousH

## Principle 2: Acquiring experience with a single shade guide and porcelain system

The goal of the current section is not to provide a recipe for shade selection with a specific technique and system but rather to point at the major elements. Among these, the shade guide system might be the least important in shade selection. Interestingly, the Vita Lumin Vacuum shade guide, which is still universally recognized and has been faithfully and successfully referred to by most porcelain brands, seems to present major inadequacies. For instance, within the same hue (A, B, C, or D), there is a simultaneous and nonlinear variation of the two other color dimensions (chroma and value). As for many other choices in high-end dental technology, the following reality must be emphasized:

> The experience acquired with a given porcelain system and shade guide is more important than the real choice and characteristics of the system itself. Experience may surpass innovation.

## Principle 3: Using a reference tooth and generating functional shade documents accordingly

Shade documents must provide not only general data on the basic tooth shade (eg, data from the shade guide) but also more detailed information that shows individual characteristics of an intact reference tooth, usually the contralateral or antagonistic tooth (Fig 5-33).

Skilled operators can routinely gather the above-mentioned information by doing the following:

- Taking photographs while selected tabs of the commercial shade guide are held edge-to-edge with reference teeth.
- Elaborating a shade-mapping sheet with reference to custom shade tabs for specific porcelain masses. ***Digital photographs with cross-polarization will facilitate this step. Simple presentation software (see chapter 3, Fig 3-47g) or the more sophisticated eLAB protocol (see next pages) can then be used to electronically determine the reference shade.***

Above all, shade documents must conform to the stratification technique and porcelain system used so that they can be continuously referred to during the ceramic work.

**FIG 5-33 Shade documents and positioning of shade tabs.** *(a to h)* General and detailed shade information can be recorded with photographs (slides or digital files). *(a)* This patient requires a porcelain veneer on the right central incisor. *(b and c)* The logical reference tooth is the intact left central incisor, which displays numerous characteristics. Intraoral photographs of shade tabs must include general views *(d)* and closer shots *(e and f)*. Above all, shade tabs must be positioned to receive the same amount of light as reference teeth during the photograph. As such, avoid placing shade tabs side by side with natural teeth (because of the frontal shift between teeth and shade guide); only the edge-to-edge position is recommended because teeth and shade tabs are on the same plane, parallel to the plane of the camera body and film and at the same distance from the camera flash system *(g)*. The cervical parts of shade tabs are often more saturated and must be omitted; they should never be juxtaposed against the incisal edge of the reference tooth.



t.me/Dr_Mouayyad_AlbtousH



5-33a



5-33b



5-33c




5-33d




5-33e



5-33f



5-33g

SHADE TABS AND TEETH
EDGE-TO-EDGE



t.me/Dr_Mouayyad_AlbtousH

The same documentation must be repeated at the try-in stage when adjustments are required. When bonded ceramic restorations will be placed on discolored teeth, it is recommended that shade documentation follows tooth preparation but while teeth are still wet; the discolored tooth substrate must be quantified in order to place the correct amount of masking shade into the ceramic buildup (selective intrinsic masking; see chapter 6, Fig 6-70).[73]

**Important: Watch dehydration!** Shade documentation should never be done at the end of a regular clinical session. Tooth dehydration commonly occurs after less than 2 minutes[74] due to tooth isolation for dental treatments and will generate brighter shades. Similarly, during shade documentation itself, photographs must be taken intermittently to allow constant rehydration of teeth by the patient's saliva.

## Advanced shade communication with eLAB and cross-polarization

Among the recent advances in digital dentistry is the eLAB system, which allows clinicians and dental ceramists to communicate tooth shade objectively simply from a calibrated digital image.[75] The availability of digital cameras has stimulated interest in their use in a wide range of colorimetric applications, and the process is well understood today.[76,77] The use of digital cameras makes it possible to carry out colorimetric measurements on objects with complicated shapes or patterns, a task that would be very tedious with photospectrometers.[75] Moreover, natural teeth present heavy light scatters. If it is attempted to measure their color with an instrument that has a small measurement window, a considerable fraction of the light entering the tooth is lost because it emerges at the surface outside of the window of measurement and is thus excluded from quantification. This phenomenon is known as "edge loss."[78] Measurement of the true visual color of natural teeth is hence best carried out at a distance, so that measurement does not interfere with illumination or with such edge loss.[79–81] Moreover, the use of digital cameras in a clinical setting is convenient and widely used in modern dental practice today.[82]

The eLAB system is an affordable photographic protocol that is centered around commonly available photographic equipment suitable for dental photography (DSLR/MILC camera body, a suitable macro lens with focal lengths ranging from 60–105 mm, as well as a dedicated macro flash system like a ring flash or lateral flash assembly).

**FIG 5-33** *(cont) (h)* The camera was tilted cervically to prevent flash reflections at the level of the incisal edge. The resulting high-magnification view of the reference tooth constitutes a map for the application of specific porcelain masses such as opalescent enamels, incisals, and stains; this picture is worth thousands of words. *(i)* A print of this image (instant digital shot) can be used to generate a shade-mapping sheet that specifies the corresponding porcelain masses (overlay).



t.me/Dr_Mouayyad_AlbtousH

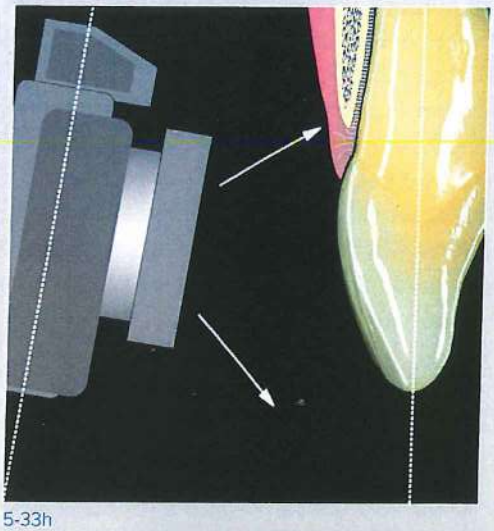

5-33h

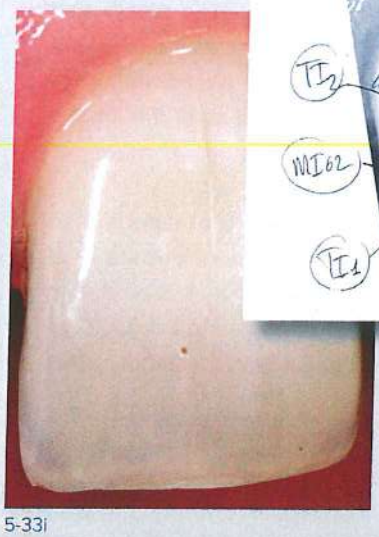

5-33i




5-34a

**FIG 5-34 Basic tools for eLAB protocol.** In order to measure tooth color from an image and for better analysis of intrinsic details and characteristics, cross-polarization is essential to eliminate the obstruction originating from specular reflections of the tooth's shiny surface. *(a)* The polar_eyes filter system exists for the most popular macro flash brands.



t.me/Dr_Mouayyad_AlbtousH

***In order to measure tooth color from an image and for better analysis of intrinsic details and characteristics, cross-polarization (polar_eyes) is essential to eliminate the obstruction originating from specular reflections of the tooth's shiny surface (Fig 5-34a).***

For the particular purpose of colorimetric measurement, a neutral gray reference card (white_balance by Emulation) needs to be placed just below the incisal edge during image acquisition following a rigid protocol for standardized dental photography (Figs 5-34b to 5-34d). For this purpose, images need to be obtained using the camera manual mode with the aperture and exposure set to fixed values of f22 and 1/125-second exposure time, respectively. The ISO sensitivity should be set to a value between 100 and 200 depending on the camera type and model, while the image quality needs to be set to RAW instead of JPEG (Fig 5-34e) to allow for synchronization of images derived from different camera models.[76]

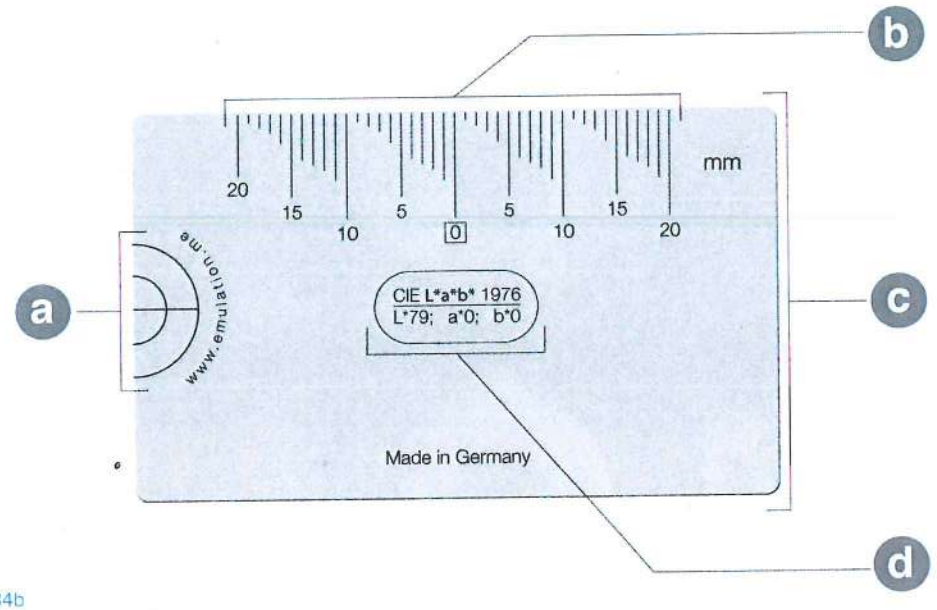


5-34b

**FIG 5-34** *(cont) (b)* White balancing is usually carried out with the help of an achromatic object like a gray reference card with the following features: a, hairline cross reticle aiming to assist with vertical alignment and distance calibration. The small circle should match with that of the viewfinder grid of most common APS-C sensor type cameras, whereas the larger one should match that of full-frame cameras. b, a millimeter scale for assessment of proportions. c, width that is equal to the average intercanine distance of white adults to assist in cases where a particular DSLR model may not have any viewfinder grid at all. d, defined color coordinates using the L*a*b* system with low manufacturing tolerance (± 0.5). *(c and d)* The white_balance gray reference card needs to be placed just below the incisal edge during image acquisition, and the optical axis should be perpendicular to the vertical plane of the gray reference card. *(e)* In order to mitigate the influence of ambient light and to ensure flash synchronization, the shutter speed should be set to 1/125 second with an aperture of f22 for suitable depth of field acquisition. (Reproduced with permission from Hein et al.[75])



t.me/Dr_Mouayyad_AlbtousH



5-34c

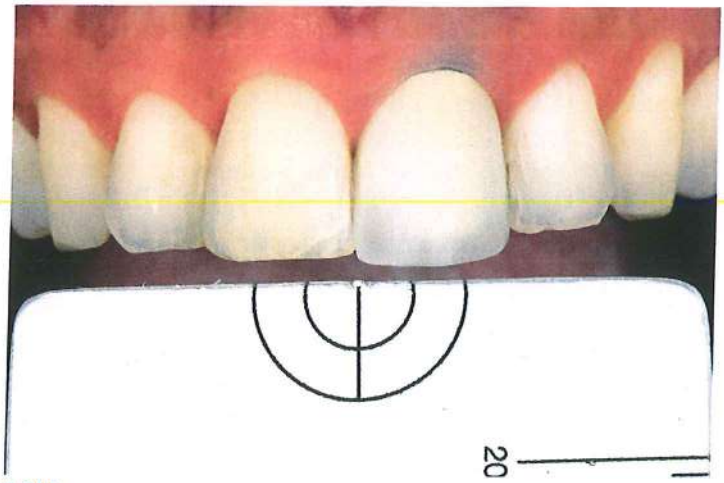


5-34d

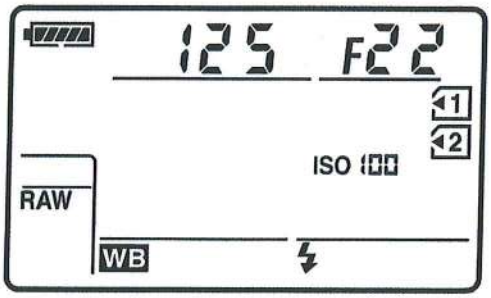


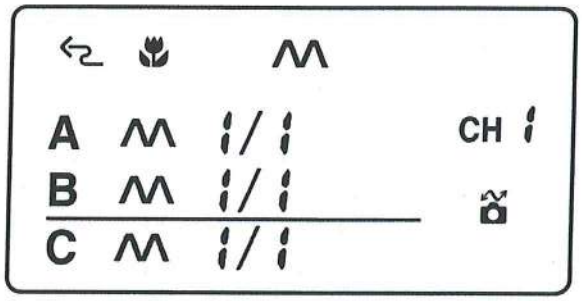


5-34e

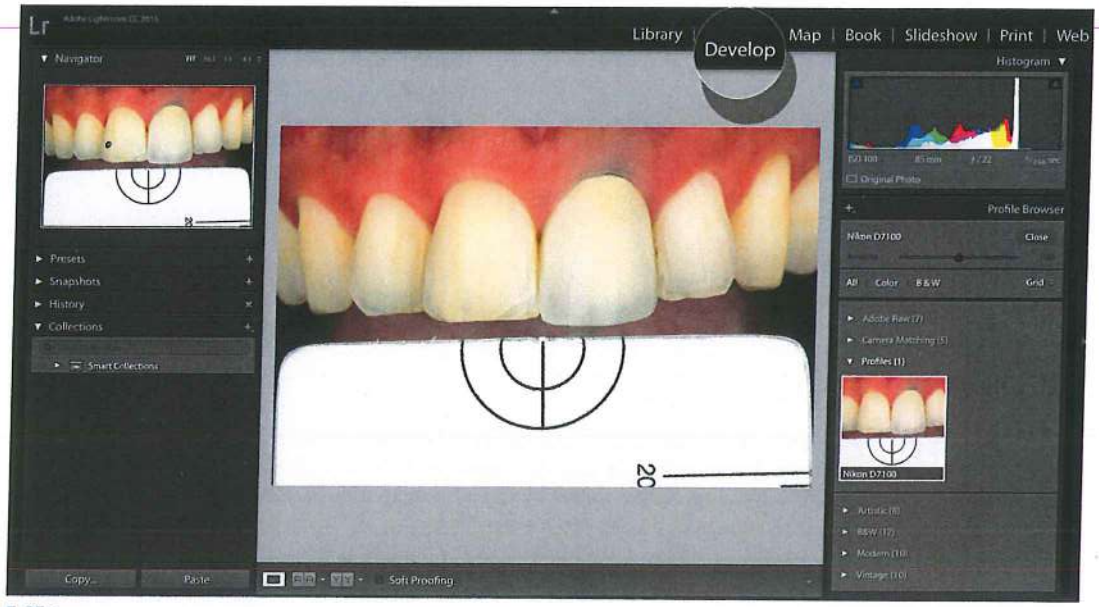


5-35a

**FIG 5-35 eLAB image processing.** Upon import of the clinical RAW file into Adobe Lightroom Classic CC, it is first necessary to choose the correct DSLR camera profile from the camera calibration drop-down menu in the Develop mode. (Reproduced with permission from Hein et al.[75])



t.me/Dr_Mouayyad_AlbtousH

Images are then transferred to the dental laboratory to be processed with a standardized calibration protocol using Adobe Lightroom Classic CC (Figs 5-35a to 5-35e). Once the images have been calibrated, tooth color can be measured with associated software (eLAB_pilot by Emulation) using the CIELAB color appearance model, which expresses tooth color through three separate coordinates. They include a luminosity axis L* to express relative brightness and chroma coordinates a* and b* to express the amounts of red/magenta (a*) and yellow (b*) for a given tooth color.

***The aforementioned process can be simplified by using the eLAB_prime software (Emulation). Artificial intelligence algorithms not only automatically analyze the shade distribution but also provide a patient-specific shade-mixing recipe for the dental ceramist and for the most commonly available ceramic systems (Fig 5-35e). Once the restoration is nearing completion, just prior to glazing, a digital try-in can be carried out using Adobe Photoshop CC software or eLAB_prime by superimposing the calibrated clinical image with the calibrated laboratory bench image on top of each other (Fig 5-36).***

This simple process provides the ability not only to quantify the difference between the target tooth color and the restoration objectively but also to analyze qualitatively via comparison of intrinsic effects and incisal characteristics. Such a digital try-in can be carried out with cross-polarized images if quantification is desired or with normally reflected images for comparison of gonio-apparent features like surface texture and luster/albedo.

The eLAB system thus provides an inexpensive and reliable tool for objective shade communication between the dental office and the dental laboratory for increased predictability and accuracy.

Compared to traditional and implant crowns (the color of which is independent of the substrate color), thin bonded restorations require some additional steps in order to facilitate the digital try-in: A tooth-colored die must be generated to mimic the tooth preparation (Fig 5-37). Acrylic resin or waxes can be used to replicate the stone dies during the digital try-in. The eLAB protocol can be used to generate accurate tooth-colored dies. Glycerin is used to obtain continuity between the veneer and the custom die during the digital try-in.

**FIG 5-35** *(cont) (b)* Selecting the White Balance Selector tool in the shape of a pipette and clicking on any of the four gray segments in the image carries out white balance correction. *(c)* In order to carry out exposure balance, it is first necessary to click on the three zeros next to the exposure slider to activate this function. When moving the cursor over any of the four gray segments, it turns into a magnifying glass. *(d)* While keeping the magnifying glass steadily in its position, measured L*a*b* values are displayed below the histogram. Operating the arrow with up or down keys on the keyboard will adjust image exposure respectively until the known luminosity value (L*79) of the gray reference card has been replicated (ie, ev –0,12). *(e)* Once the images have been calibrated, tooth color can be measured with associated software (eLAB_prime) using the CIELAB color appearance model, which expresses tooth color through three separate coordinates. They include a luminosity axis L* to express relative brightness and chroma coordinates a* and b* to express the amounts of red/magenta (a*) and yellow (b*) for a given tooth color. (Reproduced with permission from Hein et al.[75])



t.me/Dr_Mouayyad_AlbtousH

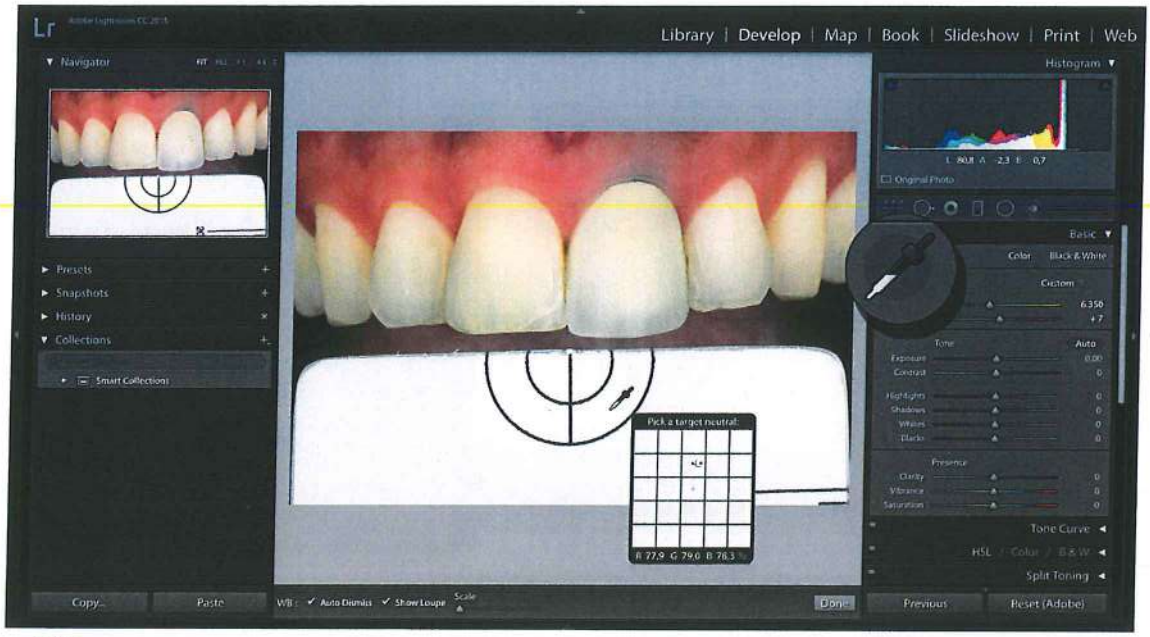


5-35b

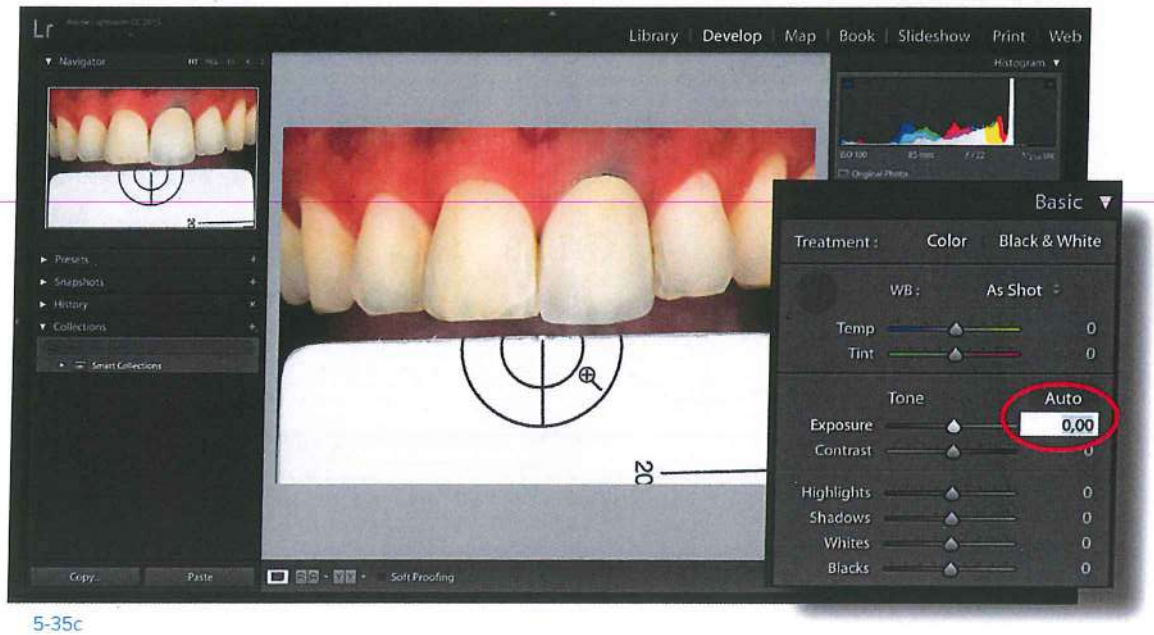


5-35c



t.me/Dr_Mouayyad_AlbtousH

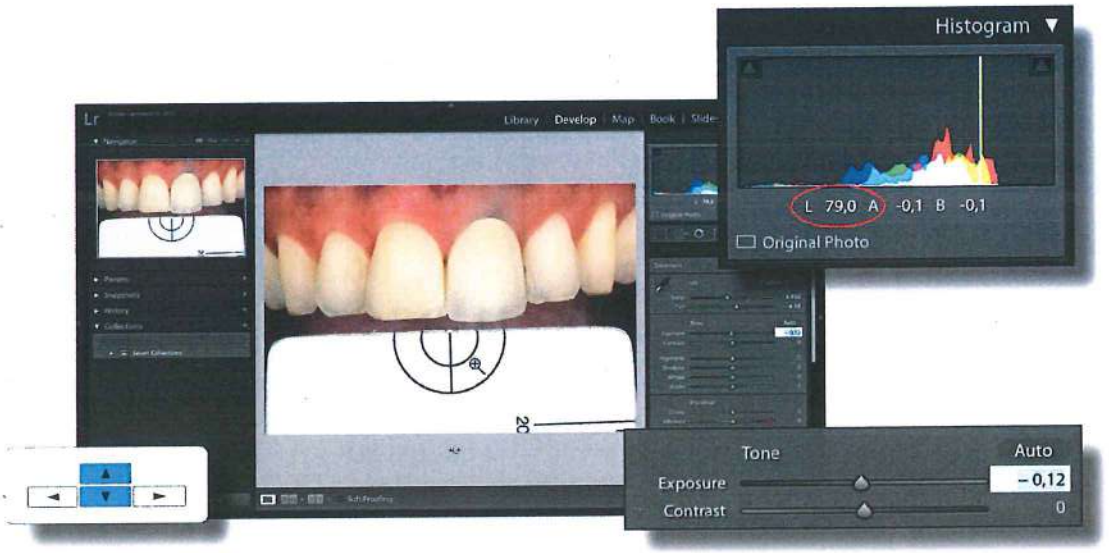


5-35d

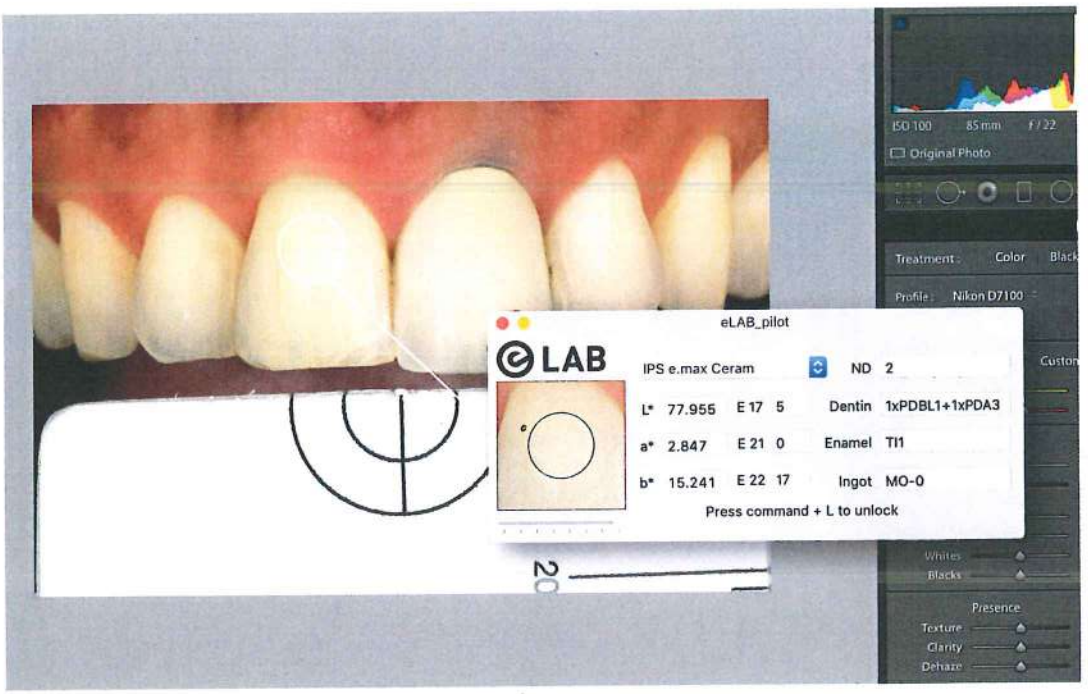


5-35e

**FIG 5-36 Digital try-in and clinical outcome.** Incisal characteristics and other details can be checked via visual and numerical comparison using the digital try-in. *(a)* For this purpose, the digital image of the restoration on the master model can be superimposed onto the clinical image obtained from the dental surgery, using either Adobe Photoshop CC, Apple Keynote, or more conveniently inside eLAB_prime software. *(b and c)* Reflected and polarized images of the final restoration placed in situ demonstrate good agreement between the digital try-in and clinical outcome. (Reproduced with permission from Hein et al.[75])



t.me/Dr_Mouayyad_AlbtousH

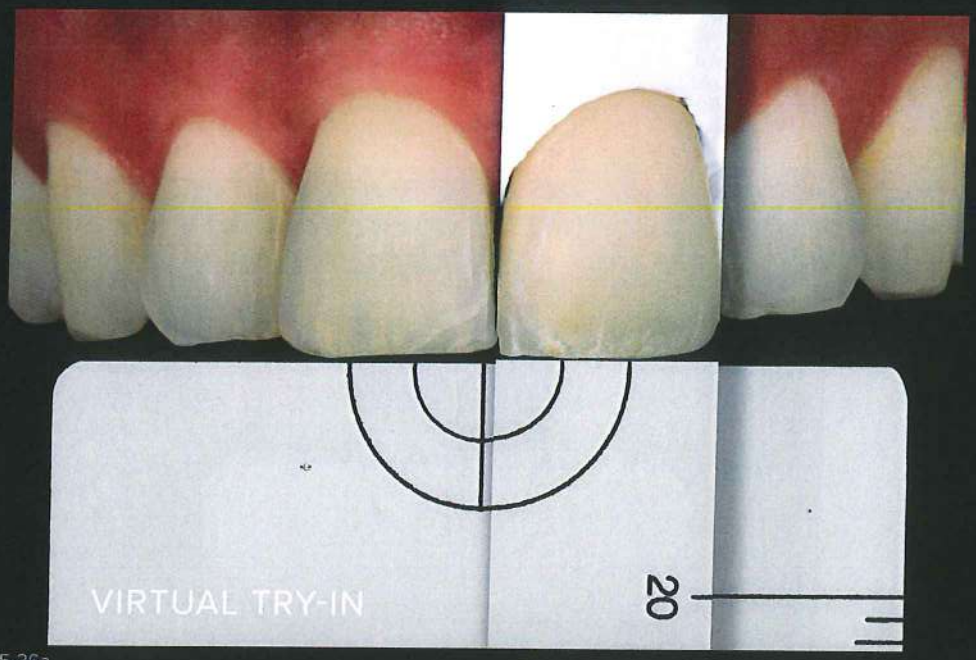


5-36a



5-36b



5-36c



t.me/Dr_Mouayyad_AlbtousH

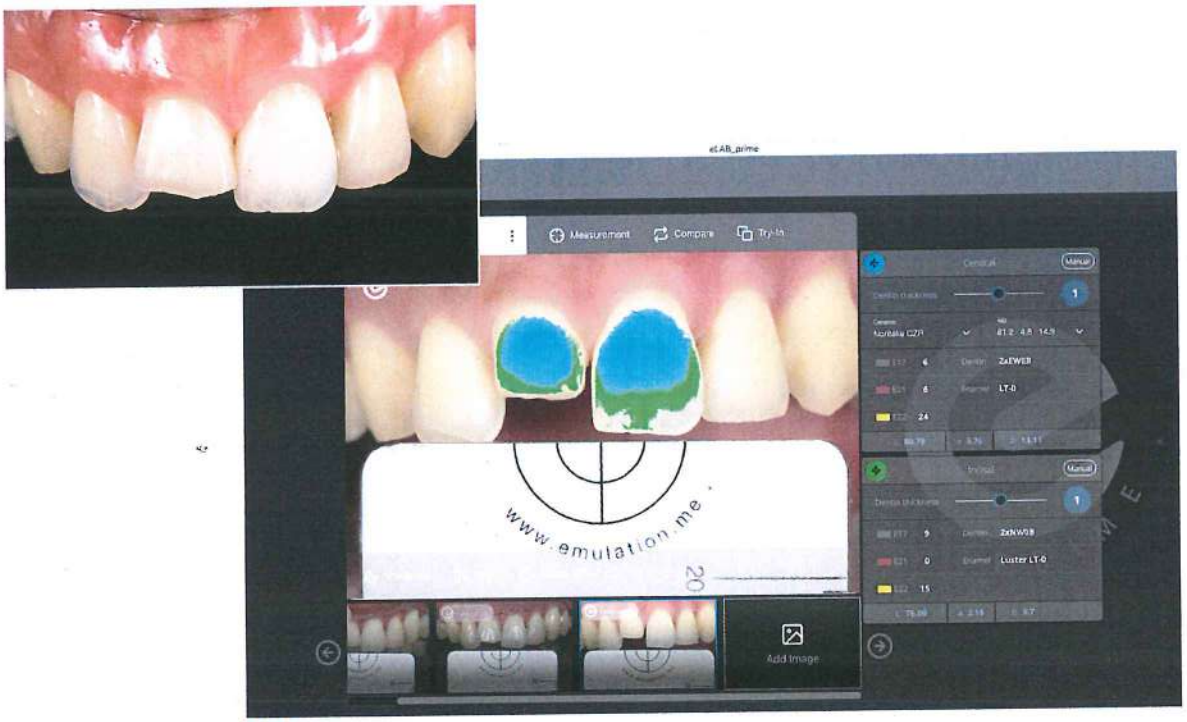


5-37a



5-37b

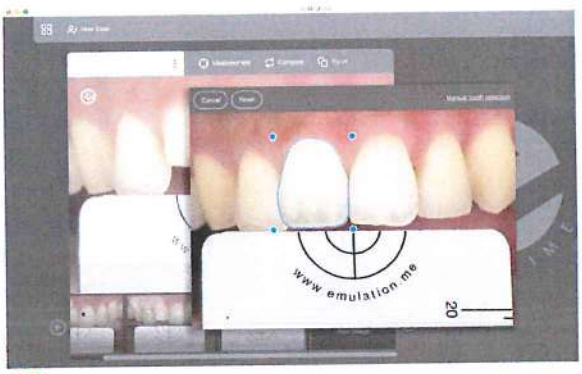


5-37c

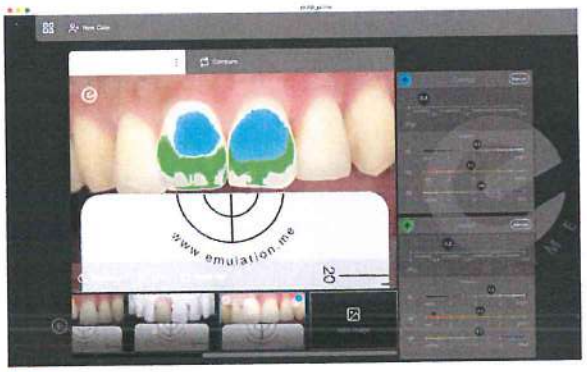


5-37d



t.me/Dr_Mouayyad_AlbtousH







**FIG 5-37 eLAB prime applied to single bonded porcelain restoration digital try-in and clinical outcome.** This extended fracture was restored with a minimally invasive bonded porcelain restoration. *(a)* Following tooth preparation, the eLAB protocol was first applied to determine the preparation color (preoperative view in overlay image). *(b)* A tooth-colored die (wax or acrylic) was used for the digital try-in. *(c and d)* The perfect color match was confirmed with eLAB_prime software. *(e and f)* The final result is stunning (insertion and postoperative, respectively). (Case courtesy of Leo Liao, MDT; clinical work by Dr John Chu; overlay image in part *a* and part *e* reproduced with permission from Liao.[83])



t.me/Dr_Mouayyad_AlbtousH

## Acknowledgments

*Special thanks to Sascha Hein (Freiburg, Germany) and Dr Panaghiotis Bazos (Aigio, Greece) for their contributions in the section related to the eLAB system and to Dr Ivan Contreras Molina (Morelia, Mexico) for the subsection about digital wax-ups.*

# REFERENCES

1. Magne P, Magne M, Belser U. The diagnostic template: A key element to the comprehensive esthetic treatment concept. Int J Periodontics Restorative Dent 1996;16:560–569.
2. Magne P, Belser UC. Novel porcelain laminate preparation approach driven by a diagnostic mock-up. J Esthet Restor Dent 2004;16:7–16.
3. Magne P, Magne M. Use of additive waxup and direct intraoral mock-up for enamel preservation with porcelain laminate veneers. Eur J Esthet Dent 2006;1:10–19.
4. Reshad M, Cascione D, Magne P. Diagnostic mock-ups as an objective tool for predictable outcomes with porcelain laminate veneers in esthetically demanding patients: A clinical report. J Prosthet Dent 2008;99:333–339.
5. Simon H, Magne P. Clinically based diagnostic wax-up for optimal esthetics: The diagnostic mock-up. J Calif Dent Assoc 2008;36:355–362.
6. Magne P, Hanna J, Magne M. The case for moderate "guided prep" indirect porcelain veneers in the anterior dentition. The pendulum of porcelain veneer preparations: From almost no-prep to over-prep to no-prep. Eur J Esthet Dent 2013;8:376–388.
7. Rieder CE. The role of operatory and laboratory personnel in patient esthetic consultations. Dent Clin North Am 1989;33:275–284.
8. Magne P, Magne M, Belser U. Restauration des dents antérieures. Rev Mens Suisse Odontostomatol 1993;103: 318–324.
9. Coachman C, Calamita M. Digital smile design: A tool for treatment planning and communication in esthetic dentistry. Quint Dent Technol 2012;35:103–111.
10. McLaren EA, Garber DA, Figueira J. The Photoshop Smile Design technique (part 1): Digital dental photography. Compend Contin Educ Dent 2013;34:772,774.
11. McLaren EA, Goldstein RE. The Photoshop Smile Design technique. Compend Contin Educ Dent 2018;39:e17–e20.
12. Kurbad A, Kurbad S. Cerec Smile Design—A software tool for the enhancement of restorations in the esthetic zone. Int J Comput Dent 2013;16:255–269.
13. Zimmermann M, Mehl A. Virtual smile design systems: A current review. Int J Comput Dent 2015;18:303–317.
14. Daher R, Ardu S, Vjero O, Krejci I. 3D Digital Smile Design with a mobile phone and intraoral optical scanner. Compend Contin Educ Dent 2018;39:e5–e8.
15. Raetzke PB. Covering localized areas of root exposure employing the "envelope" technique. J Periodontol 1985; 56:397–402.
16. Bruno JF. Connective tissue graft technique assuring wide root coverage. Int J Periodontics Restorative Dent 1994;14:127–137.
17. Buonocore MG. A simple method of increasing the adhesion of acrylic filling materials to enamel surfaces. J Dent Res 1955;34:849–853.
18. Fradeani M. Six-year follow-up with Empress veneers. Int J Periodontics Restorative Dent 1998;18:216–225.
19. Peumans M, Van Meerbeek B, Lambrechts P, Vuylsteke-Wauters M, Vanherle G. Five-year clinical performance of porcelain veneers. Quintessence Int 1998;29:211–221.
20. Friedman MJ. A 15-year review of porcelain veneer failure—A clinician's observations. Compend Contin Educ Dent 1998;19:625–636.
21. Dumfahrt H. Porcelain laminate veneers. A retrospective evaluation after 1 to 10 years of service: Part II—Clinical results. Int J Prosthodont 2000;13:9–18.
22. Lin CP, Douglas WH. Structure-property relations and crack resistance at the bovine dentin-enamel junction. J Dent Res 1994;73:1072–1078.
23. Garber D. Porcelain laminate veneers: Ten years later. Part I: Tooth preparation. J Esthet Dent 1993;5:56–62.
24. Nattress BR, Youngson CC, Patterson CJ, Martin DM, Ralph JP. An in vitro assessment of tooth preparation for porcelain veneer restorations. J Dent 1995;23:165–170.
25. Magne M, Douglas WH. Porcelain veneers: Dentin bonding optimization and biomimetic recovery of the crown. J Prosthodont 1999;12;111–121.
26. Magne P, Douglas WH. Additive contour of porcelain veneers: A key-element in enamel preservation, adhesion and esthetic for the aging dentition. J Adhes Dent 1999;1:81–91.
27. Stanley M, Paz AG, Miguel I, Coachman C. Fully digital workflow, integrating dental scan, smile design and CAD-CAM: Case report. BMC Oral Health 2018;18:134.
28. Margossian P, Laborde G, Koubi S, Couderc G, Mariani P. Use of the ditramax system to communicate esthetic specifications to the laboratory. Eur J Esthet Dent. 2011;6:188–196.
29. Margossian P, Laborde G, Koubi S, Tardivo D, Magne P. Determination of facial references for esthetic restorative treatment. Int J Periodontics Restorative Dent 2021;41:113–119.
30. Demarin V, Bedeković MR, Puretić MB, Pašić MB. Arts, brain and cognition. Psychiatr Danub. 2016;28:343–348.
31. Michalakis KX, Stratos A, Hirayama H, Pissiotis AL, Touloumi F. Delayed setting and hygroscopic linear expansion of three gypsum products used for cast articulation. J Prosthet Dent. 2009;102:313–318.
32. Magne P, Magne M, Belser U. Natural and restorative oral esthetics. Part I: Rationale and basic strategies for successful esthetic rehabilitations. J Esthet Dent 1993; 5:161–173.
33. Rieder CE. Use of provisional restorations to develop and achieve esthetic expectations. Int J Periodont Rest Dent 1989;9:122–139.
34. Magne M, Magne P. Schlüsselelemente eines umfassenden ästhetischen Behandlungskonzeptes. Dental Labor 1999;XLVII:545–555.
35. Magne P, Douglas WH. Rationalization of esthetic restorative dentistry based on biomimetics. J Esthet Dent 1999;11:5–15.
36. Belser UC, Magne P, Magne M. Ceramic laminate veneers: Continuous evolution of indications. J Esthet Dent 1997;9:197–207.
37. Deery C, Wagner ML, Longbottom C, Simon R, Nugent ZJ. The prevalence of dental erosion in a United States and a United Kingdom sample of adolescents. Pediatr Dent 2000;22:505–510.



t.me/Dr_Mouayyad_AlbtousH

38. Azzopardi A, Bartlett DW, Watson TF, Sherriff M. The surface effects of erosion and abrasion on dentine with and without a protective layer. Br Dent J 2004;196:351–354.
39. Cardoso ACC, Canabarro S, Myers SL. Dental erosion: Diagnostic-based noninvasive treatment. Pract Periodont Aesthet Dent 2000;12:223–228.
40. Jaeggi T, Gruninger A, Lussi A. Restorative therapy of erosion. Monogr Oral Sci 2006;20:200–214.
41. Magne P, Magne M, Belser UC. Adhesive restorations, centric relation, and the Dahl principle: Minimally invasive approaches to localized anterior tooth erosion. Eur J Esthet Dent 2007;2:260–273.
42. King PA. Tooth surface loss. Adhesive techniques. Br Dent J 1998;186:371–376.
43. Magne P. Noninvasive bilaminar CAD/CAM composite resin veneers: A semi-(in)direct approach. Int J Esthet Dent 2017;12:134–154.
44. Dahl BL, Krogstad O. An alternative treatment in cases with advance localized attrition. J Oral Rehab 1975;2:209–214.
45. Edelhoff D, Sorensen JA. Tooth structure removal associated with various preparation designs for anterior teeth. J Prosthet Dent 2002;87:503–509.
46. Edelhoff D, Sorensen JA. Tooth structure removal associated with various preparation designs for posterior teeth. Int J Periodontics Restorative Dent 2002;22:241–249.
47. Pippin DJ, Mixson JM, Soldan-Els AP. Clinical evaluation of restored maxillary incisors: Veneers vs. PFM crowns. J Am Dent Assoc 1995;126:1523–1529.
48. Lucia VO. A technique for recording centric relation. J Prosthet Dent 1964;14:492–505.
49. Lucia VO. Modern Gnathological Concepts. Chicago: Quintessence, 1983.
50. Dahl BL, Krogstad O. The effect of a partial bite raising splint on the occlusal face height. An x-ray cephalometric study in human adults. Acta Odontol Scand 1982;40:17–24.
51. Mizrahi B. A technique for simple treatment of anterior toothwear. Dent Update 2004;31:109–114.
52. Mizrahi B. The Dahl principle: Creating space and improving the biomechanical prognosis of anterior crowns. Quintessence Int 2006;37:245–251.
53. Vailati F, Belser UC. Full-mouth adhesive rehabilitation of a severely eroded dentition: The three-step technique. Part 1. Eur J Esthet Dent 2008;3:30–44.
54. Vailati F, Belser UC. Full-mouth adhesive rehabilitation of a severely eroded dentition: The three-step technique. Part 2. Eur J Esthet Dent 2008;3:128–146.
55. Vailati F, Belser UC. Full-mouth adhesive rehabilitation of a severely eroded dentition: The three-step technique. Part 3. Eur J Esthet Dent 2008;3:236–257.
56. Schlichting LH, Resende TH, Reis KR, Magne P. Simplified treatment of severe dental erosion with ultrathin CAD-CAM composite occlusal veneers and anterior bilaminar veneers. J Prosthet Dent 2016;116:474–482.
57. Resende TH, Reis KR, Schlichting LH, Magne P. Ultrathin CAD-CAM ceramic occlusal veneers and anterior bilaminar veneers for the treatment of moderate dental biocorrosion: A 1.5-year follow-up. Oper Dent 2018;43:337–346.
58. Magne P, Schlichting LH, Maia HP, Baratieri LN. In vitro fatigue resistance of CAD/CAM composite resin and ceramic posterior occlusal veneers. J Prosthet Dent 2010;104:149–157.
59. Ernst O, Müller P, Özcan M. Load bearing capacity of minimal invasive direct and indirect veneers bonded to maxillary incisors with severe wear: Effect of preparation design and material type. J Adhes Sci Technol 2018;32:1151–1164.
60. Zimmerli B, De Munck J, Lussi A, Lambrechts P, Van Meerbeek B. Long-term bonding to eroded dentin requires superficial bur preparation. Clin Oral Investig 2012;16:1451–1461.
61. Walls AW. The use of adhesively retained all-porcelain veneers during the management of fractured and worn anterior teeth: Part 1. Clinical technique. Br Dent J 1995;178:333–336.
62. Walls AW. The use of adhesively retained all-porcelain veneers during the management of fractured and worn anterior teeth: Part 2. Clinical results after 5 years of follow-up. Br Dent J 1995;178:337–340.
63. Loi I, Di Felice A. Biologically oriented preparation technique (BOPT): A new approach for prosthetic restoration of periodontically healthy teeth. Eur J Esthet Dent 2013;8:10–23.
64. Reis A, Higashi C, Loguercio AD. Re-anatomization of anterior eroded teeth by stratification with direct composite resin. J Esthet Restor Dent 2009;21:304–316.
65. Schlichting LH, Maia HP, Baratieri LN, Magne P. Novel-design ultra-thin CAD/CAM composite resin and ceramic occlusal veneers for the treatment of severe dental erosion. J Prosthet Dent 2011;105:217–226.
66. Magne P, Stanley K, Schlichting LH. Modeling of ultrathin occlusal veneers. Dent Mater 2012;28:777–782.
67. Kunzelmann KH, Jelen B, Mehl A, Hickel R. Wear evaluation of MZ100 compared to ceramic CAD/CAM materials. Int J Comput Dent 2001;4:171–184.
68. Krämer N, Kunzelmann KH, Taschner M, Mehl A, Garcia-Godoy F, Frankenberger R. Antagonist enamel wears more than ceramic inlays. J Dent Res 2006;85:1097–1100.
69. Pallesen U, Qvist V. Composite resin fillings and inlays: An 11-year evaluation. Clin Oral Invest 2003;7:71–79.
70. Van Dijken JW. Direct resin composite inlays/onlays: An 11 year follow-up. J Dent 2000;28:299–306.
71. Arpa C, Ceballos L, Fuentes MV, Perdigão J. Repair bond strength and nanoleakage of artificially aged CAD-CAM composite resin. J Prosthet Dent 2019;121:523–530.
72. Hardan L. Protocols for Mobile Dental Photography with Auxiliary Lighting. Chicago: Quintessence, 2020.
73. Magne M, Magne I, Bazos P, Paranhos MP. The parallel stratification masking technique: An analytical approach to predictably mask discolored dental substrate. Eur J Esthet Dent 2010;5:330–339.
74. Ruiz-López J, Pulgar R, Lucena C, et al. Impact of short-term dental dehydration on in-vivo dental color and whiteness. J Dent 2021;105:103560.
75. Hein S, Tapia J, Bazos P. eLABor_aid: A new approach to digital shade management. Int J Esthet Dent 2017;2:186–202.
76. Hunt RWG, Pointer MR. Colorimetry with digital cameras. In: Measuring Color, ed 4. Hoboken, NJ: Wiley, 2011.
77. Berns RS. Digital cameras. In: Billmeyer and Salzman's Principles of Color Theory, ed 4. Hoboken, NJ: Wiley, 2019.
78. Bosch JJ, Coops JC. Tooth color and reflectance as related to light scattering and enamel hardness. J Dent Res 1995;74:374–380.
79. MacEntee M, Lakowski R. Instrumental color measurement of vital and extracted human teeth. J Oral Rehabil 1981;8:203–208.
80. Ishiwata T. A study of color in prosthodontics examination using spectroradiometry. J Jpn Prosthodont Soc 1986;30:652–664.
81. Kobayashi I. A study of the esthetic coloring of teeth by spectroradiometry—Concerning the maxillary anterior teeth of the middle and old aged people. J Jpn Prosthodont Soc 1988;32:439–448.
82. Desai V, Bumb D. Digital dental photography: A contemporary revolution. Int J Clin Pediatr Dent 2013;6:193–196.
83. Liao L. The balance between art and science. Quint Dent Technol (Japan) 2020;45:3–12.




t.me/Dr_Mouayyad_AlbtousH



t.me/Dr_Mouayyad_AlbtousH

# ANTERIOR INDIRECT BONDED PORCELAIN RESTORATIONS

As explained in chapter 1, the great potential of bonded restorations can be understood with respect to the scientific and clinically relevant parameters related to biology, function, and mechanics. Indirect bonded porcelain restorations (BPRs) provide the operator with a powerful modality regarding esthetics in the long term. Even when esthetics is not the primary objective, it still requires special consideration. Modification of form, position, and color of anterior teeth generates significant effects on the smile, which in turn can enhance the patient's self-esteem and social life. Initially used to treat various kinds of discoloration, porcelain laminates (the original BPRs) have been increasingly substituted by more conservative therapeutic modalities such as chemical bleaching, micro- and megabrasion, and direct and semi-(in)direct composite resin restorations (see chapters 3 and 4). However, this evolution has not reduced the indications for BPRs, as new ones have been developed and are illustrated in this chapter. The diagnostic approach follows the principles described in chapter 5. Elaborate and precise porcelain workpieces can be fabricated using the refractory die technique provided that appropriate tooth preparation techniques are followed (mock-up–driven approach). Step-by-step delivery procedures are also covered in this chapter. Anterior indirect BPRs may represent the most biomimetic type of restorations due to the synergetic combination of ceramic (enamellike) and composite resin (dentinlike). However, they are also the costliest among bonded restorations because the esthetic outcome relies on the specialized skills of a master dental ceramist—ie, a "champion" artisan who is capable of transforming the anorganic ceramic powder into a beautiful organic piece of art.



t.me/Dr_Mouayyad_AlbtousH

# 6.1 HISTORY AND CLASSIFICATION OF INDICATIONS

In the 1930s, Dr Charles Pincus was presumably the first to use thin veneers temporarily attached to actors' teeth to enhance their close-up shots in the movie industry.[1] Bonded pellicular ceramic coverage of anterior teeth was only described in the early 1980s,[2,3] integrating the adhesion principles developed earlier by Buonocore and Bowen. But it is Rochette in France who, in 1975, first proposed the use of bonded ceramic restorations in the anterior dentition.[4] He described a technique for making porcelain restorations for fractured incisors without operative interference. The ceramic block was baked in the laboratory on a 24-karat-gold matrix cast. A resin was bonded to the silane-treated porcelain block and etched enamel. In view of current techniques, it is obvious that Rochette's approach was visionary. Porcelain veneers bonded to etched enamel evolved from this technique and became popular in Europe through the works of Touati et al.[5–7] In North America, essential developments (eg, for improving adhesion) were carried out by Horn, Calamia, Simonsen, Christensen, Garber, Goldstein, and Friedman.[2,3,8–13] Surprisingly, the method has not evolved too much since 1980, although the potential of bonded ceramics is well known today due to their ability to largely fulfill the biomimetic principle (see chapter 1, section 1.8).

> The success of porcelain laminates is not born from the use of so-called "high technology" or advanced materials but simply by associating two traditional materials—microhybrid/nanohybrid composite resins and porcelain.

Such accomplishment lies directly in the fact that only the specific advantages of these two materials are used (Table 6-1): adhesion and economy of tooth substrate for the composite resins, and esthetics and durability for the porcelain. The respective disadvantages (ie, shrinkage stresses and thermal expansion for composites, brittleness for porcelains) are avoided by using limited volumes of the former and appropriate thickness of the latter. Once ideally bonded to the tooth, porcelain should no longer show problems related to its inherent fragility.

Ultimately, the configuration of the ceramic workpiece increasingly allows clinicians to keep more and more tooth substance intact, especially the palatal surface, which represents the most sophisticated element of the intact tooth crown (see chapter 1, Fig 1-8b).

Even though Rochette[4] had already proposed to use bonded ceramics to treat fractured teeth, the real potential of porcelain laminates had been underestimated until the late 1990s. Understanding of different configuration factors and geometry has allowed a revival of BPRs.

***The evolution of anterior BPRs shows a trend toward the possibility to replace increased amounts of tooth substance in a crescendo of indications, from type I to type V (Fig 6-1 and Box 6-1).***

Many situations in type I and II indications correspond to the original spectrum and most traditional indications for porcelain laminates.[2,3,8–10] On the other hand, some type II and type III indications (and especially type IIIA) have been added in the 1990s.[14–25] At the same time, Burke coined the term "dentin-bonded crown" (see also section 6.6), which represents perfectly the new type IV indication of the present classification. Type III and type IVA indications are somewhat similar but differ by the design of the restoration, while type IVB are essentially cases of existing full-coverage crown replacement. Type V indications (endocrown BPRs) have been prospectively added and will require more clinical data to confirm this no-post no-core approach for the restoration of compromised or severely broken-down endodontically treated anterior teeth without ferrule effect (see available data in Fig 6-17h).


t.me/Dr_Mouayyad_AlbtousH

**TABLE 6-1** Clinical characteristics of composite resins and porcelain

| | Main advantages | Main disadvantages |
|---|---|---|
| Composite resins | **Bonding** | Polymerization contraction |
| | **Economy of tooth substrate** | Thermal expansion |
| | **Dentinlike flexibility** | |
| Porcelain | **Durability and esthetics** | Brittleness |
| | **Enamellike stiffness** | Wear properties |

**BOX 6-1** Classification of indications for BPRs

## TYPE I
### Teeth resistant to bleaching

| | |
|---|---|
| Type IA | Tetracycline discoloration of degrees III and IV |
| Type IB | Lack of response to external or internal bleaching |

## TYPE II
### Major morphologic modifications

| | |
|---|---|
| Type IIA | Conoid teeth |
| Type IIB | Interdental triangles and diastemata to be closed |
| Type IIC | Augmentation of incisal length and prominence |

## TYPE III
### Extensive restorations in adults

| | |
|---|---|
| Type IIIA | Extended coronal fractures |
| Type IIIB | Extended loss of enamel by biocorrosion and wear |
| Type IIIC | Generalized congenital and acquired malformations |

## TYPE IV
### Full-coverage crowns

| | |
|---|---|
| Type IVA | Dentin-bonded crowns (indications similar to type III) |
| Type IVB | Replacement of existing full-coverage crowns |

## TYPE V
### Endocrowns

| | |
|---|---|
| Prospective type | Restoration of severely broken-down endodontically treated teeth |


t.me/Dr_Mouayyad_AlbtousH

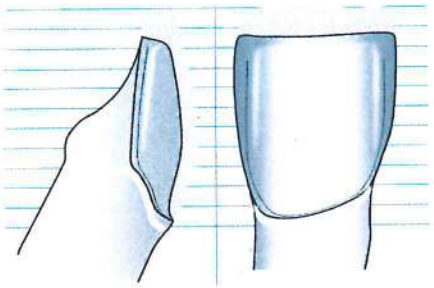

## TYPE I

ORIGINAL DESIGN FROM 1980s
"FINGERNAIL TYPE" VENEER

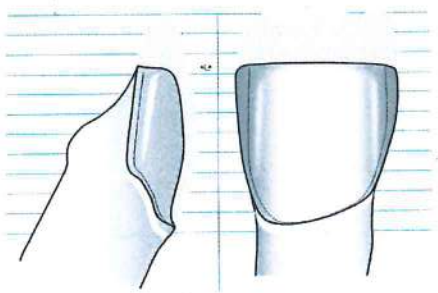

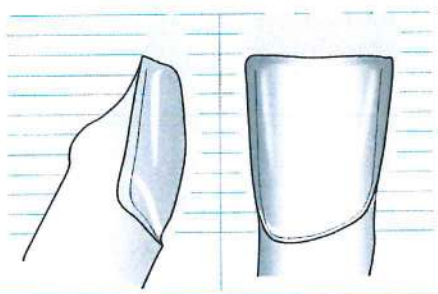

## TYPE II

INCREASED INCISAL LENGTH

INCREASED INTERDENTAL
WRAPPING TO INCLUDE MINIWINGS

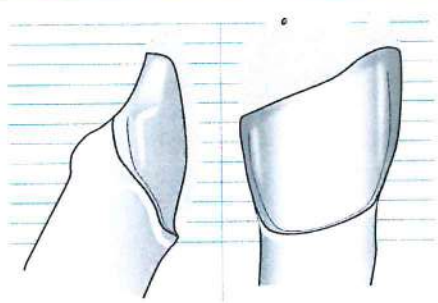

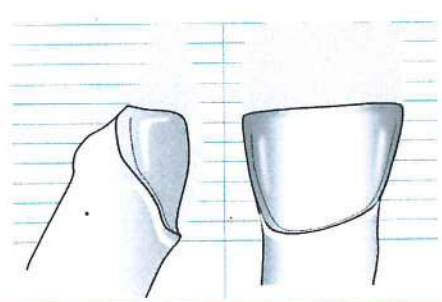

## TYPE III

EXTENSIVE INCISAL EDGE LENGTH

EXTENSIVE COVERAGE



t.me/Dr_Mouayyad_AlbtousH

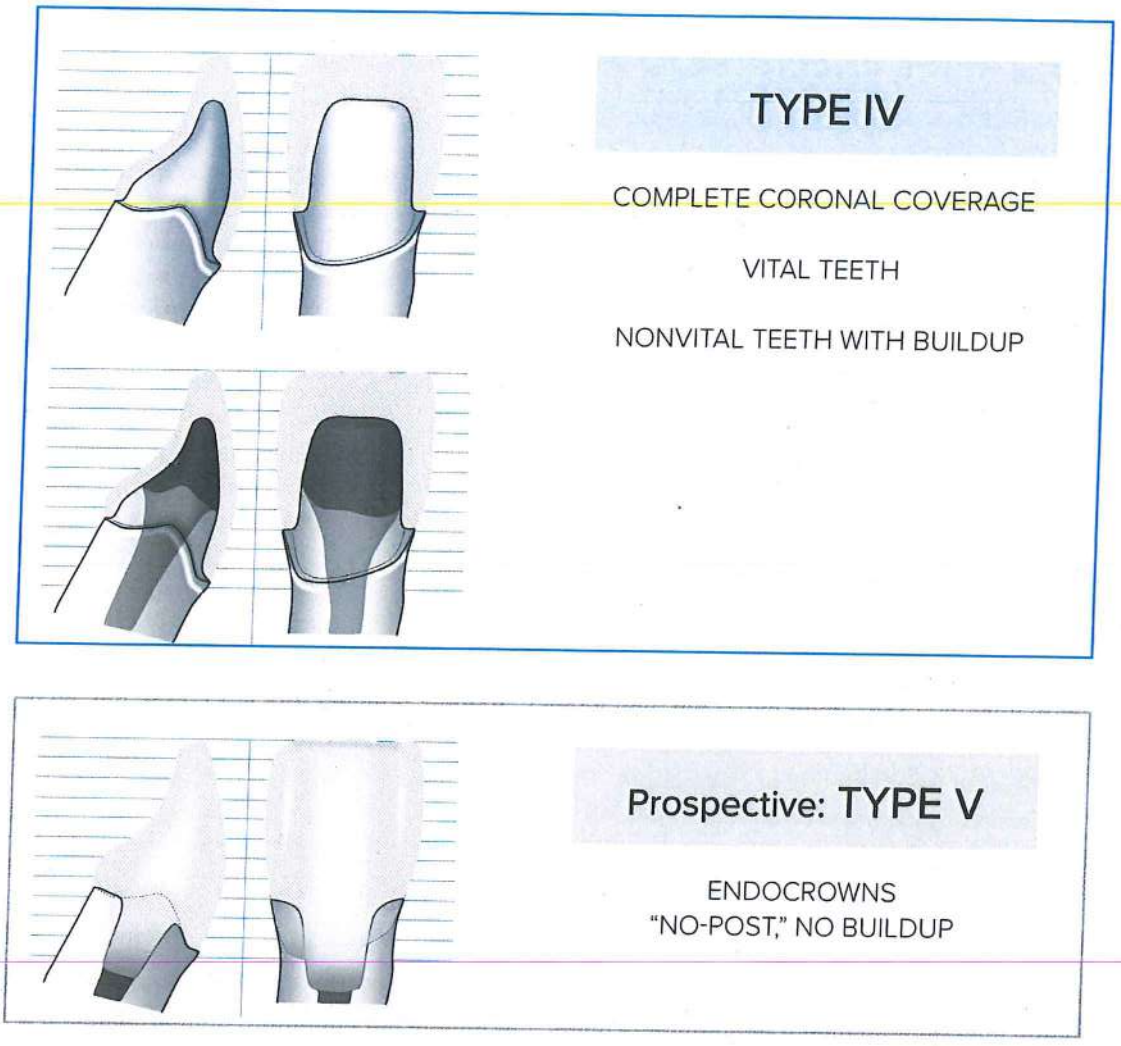


**FIG 6-1 Evolution of the bonded porcelain workpiece configuration.** Due to the development of bleaching and minimally invasive restorative dentistry, the original indications of porcelain laminates (type I) have been narrowed. Other indications, however, have been added (type II and type III), which correspond to more compromised situations with the possibility of extending incisal edge coverage and proximal wrapping. Type IV is represented by the dentin-bonded full-coverage crown (see also section 6.6 and Fig 6-17) and type V by the endocrown, still a prospective indication (see Fig 6-17h).

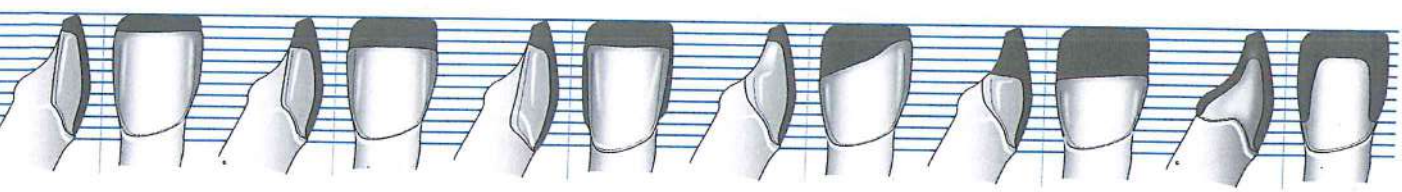


t.me/Dr_Mouayyad_AlbtousH

# 6.2 TYPE I: TEETH RESISTANT TO BLEACHING

***Examples of type I indications still include discolored teeth due to tetracycline therapy (degrees III and IV according to Jordan and Boksman[26]; type IA, Fig 6-2) and anterior teeth that present worn incisal edges that subsequently lead to an infiltration of the exposed dentin (type IB, Fig 6-3).***

## Type IA: Tetracycline discolorations

The occurrence of type IA indications should be reduced due to nightguard vital bleaching and the possibility to extend the chemical treatment over 6-month periods.[27] These patients can even be treated by bleaching beneath existing porcelain veneers.[28] ***Type I situations, which often require minimal tooth preparation, are the most difficult to treat in terms of color depth. The ceramist has to ensure an effective masking of the underlying discoloration and simultaneously create the illusion of a natural intensity in tooth shade.***

In aged teeth, the inclusion of distinct and characteristic features such as intense coloration, spots, and crack lines may facilitate the final integration of the veneers, despite the lack of thickness of the restorative material (Fig 6-3).[20] Some aspects of the laboratory procedures related to the specific problem of masking are presented in Fig 6-70.

Even in these difficult cases, it is still suggested to bleach first to lighten the base color of the tooth and make the future restorations more lifelike. Due to the ever-improving performance of dentin adhesives and the immediate dentin sealing (IDS) technique, other approaches may also include deeper preparations involving dentin, thus facilitating the work of the dental technician.



6-2a



6-2b

**FIG 6-2 Worn and tetracycline-stained teeth.** *(a)* From the perspective of color, this case of tetracycline-stained teeth could be resolved with up to 4 to 6 months of nightguard vital bleaching. *(b)* Porcelain veneers were used instead due to the existing wear and because a full-mouth rehabilitation with opening of the vertical dimension of occlusion was planned.

**FIG 6-3 Aged teeth resisting nightguard vital bleaching.** Discoloration is supposedly due to incisal wear and subsequent infiltration of the exposed dentin. *(a)* Several weeks of nightguard bleaching with carbamide peroxide had no effect on tooth shade, and the patient lost motivation to continue wearing the trays. He insisted on using veneers instead. Despite conservative tooth preparation *(b)*, the two laminate veneers integrate well with the opposing teeth due to the inclusion of illusive effects such as crack lines and other intensive stains *(c and d)*. Note the lack of interdental extension of the preparation at the mesial aspect of the central incisors, which did not allow the ceramist to close the black interdental triangle (see Fig 6-6 for proper design). The traditional full-coverage crown on the left lateral incisor was replaced.



t.me/Dr_Mouayyad_AlbtousH

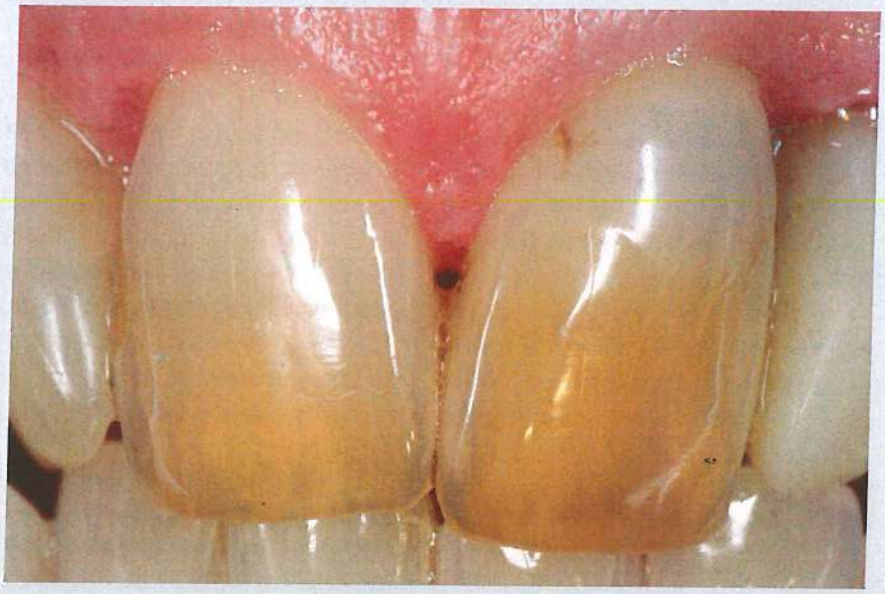

6-3a

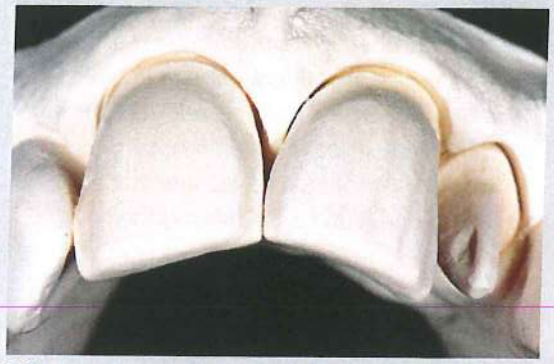

6-3b

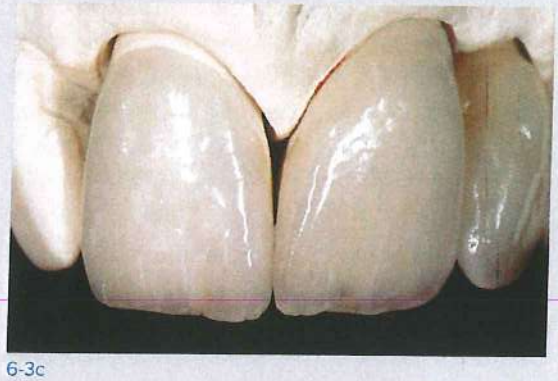

6-3c

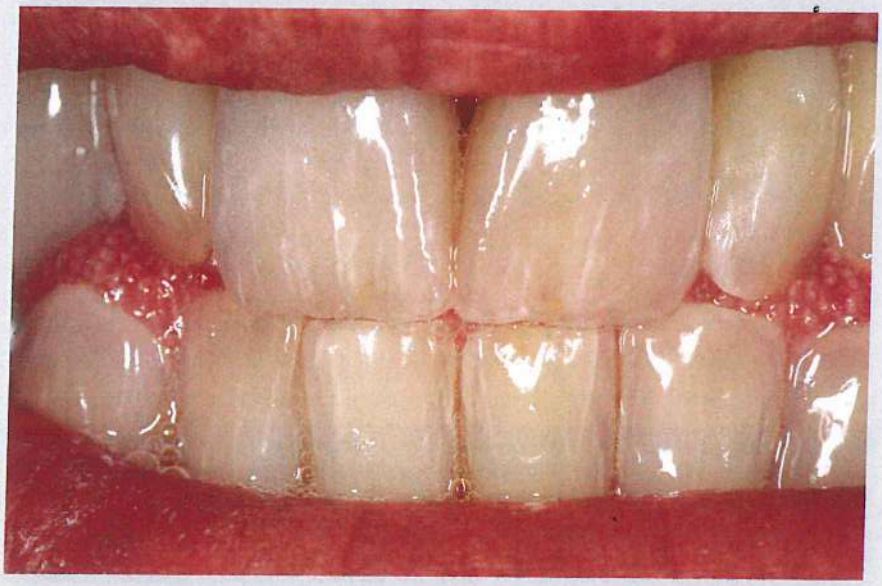

6-3d



t.me/Dr_Mouayyad_AlbtousH

## Type IB: Lack of response to external or internal bleaching

***Situations that show limited response to external or internal bleaching procedures may include vital worn teeth with a dentin-exposed incisal edge (see Fig 6-3) as well as pulpless teeth (Fig 6-4).***

Porcelain veneering and endodontic procedures are compatible. Veneered teeth are characterized by their "natural" behavior; for instance, veneered incisors demonstrate a stress distribution that cannot be differentiated from that within intact incisors under load[29] (see chapter 1, Fig 1-15d). This is the essence of biomimetics[30]—when restorations behave functionally as natural teeth regarding strain and stress transfer. On the other hand, it is generally assumed that porcelain laminates are not indicated in pulpless teeth even though scientific evidence seems to prove the opposite. In an in vitro trial, pulpless veneered incisors behaved like natural endodontically treated teeth.[31] In a prospective clinical trial, Gresnigt et al demonstrated that endodontic treatment does not affect the survival of ceramic laminate veneers.[32] When pulpless teeth are treated with traditional prosthodontic procedures (instead of the more conservative veneering techniques), various types of posts and cores are commonly recommended. This, in turn, may generate numerous complications, such as cracks and root fractures. It is now established that both the biomechanical properties and the moisture content of nonvital teeth do not significantly differ from those of vital teeth.[33,34] The loss of tooth structure thus becomes the primary cause of failure, not the effect of pulp removal per se.

Except perhaps in cases of endodontically treated teeth with severe breakdown of tooth substance, there is currently no evidence that contraindicates veneering nonvital teeth. After all, ***porcelain laminates may substantially increase the mechanical coronal resistance[14,15,31] and restore the original tooth stiffness,[29] especially when the ceramic is thick enough to reproduce the original crown volume and length[21]*** (see additive contour explained in chapter 5, Fig 5-5). It appears reasonable to assume that a similar effect can be found on a pulpless tooth.

**FIG 6-4 Teeth with limited response to the walking bleach technique.** *(a and b)* The right central and lateral incisors are nonvital and do not show further response to internal bleaching. *(c)* Deep internal residual discoloration becomes more evident after tooth preparation. The left central incisor was included to simultaneously allow for redefinition of crown shape and incisal length of both central incisors (see also next section related to type II indications). *(d)* The postoperative views demonstrate the optimized tooth shape and recovered shade and smile line. (Case realized in collaboration with Drs Olivier Duc and Raymond Perroud and Prof Ivo Krejci, University of Geneva.)



t.me/Dr_Mouayyad_AlbtousH



6-4a



6-4b



6-4c



6-4d



t.me/Dr_Mouayyad_AlbtousH

# 6.3 TYPE II: MAJOR MORPHOLOGIC MODIFICATIONS

This group of indications consists of patients with very high expectations and, as a consequence, developed senses for esthetics. These clinical situations could also be addressed with direct composite resin restorations, especially in children. Interim composite resin restorations should be the first choice in young patients, while BPRs are ideally placed in adulthood. There are three subcategories (IIA, IIB, and IIC).

## Type IIA: Conoid teeth

Due to their "retracted" shape, conoid teeth naturally present an ideal configuration for the use of porcelain veneers (Fig 6-5).[16,17,20] The required tooth preparation is minimal; only a light marginal chamfer is needed for the dental technician to fabricate an accurate ceramic piece. It would be theoretically possible to proceed without tooth preparation. Doing so, however, would generate a delicate and fragile feather-edge ceramic margin, which increases the risk of fracture during peripheral adaptation (laboratory procedures) and clinical placement.

*A porcelain laminate would not necessarily be indicated for a single, isolated, malformed lateral incisor such as presented in chapter 3, Fig 3-39.* ***Such a problem can be easily addressed by freehand application of composite resins***, especially when the restorative material is supported by intact underlying enamel and the tooth is not subjected to significant functional loads.



6-5a



6-5b

**FIG 6-5 Type IIA indication for conoid teeth.** *(a)* The patient presents with conoid lateral incisors, and the right central incisor is restored with an old resin crown. *(b and c)* Tooth preparations are controlled with two distinct silicon guides derived from the diagnostic wax-up (incisal and axial views, respectively). *(d to g)* Final aspect after adhesive placement of a full-coverage crown on the central incisor and two porcelain laminates on the lateral incisors. Tooth preparation was minimal for both the traditional coverage and the laminate restoration. Provisionalization of lateral incisors was not required except for diagnostic purposes. (Parts *a*, *b*, and *d* reproduced with permission from Belser et al.[20])



t.me/Dr_Mouayyad_AlbtousH



6-5c

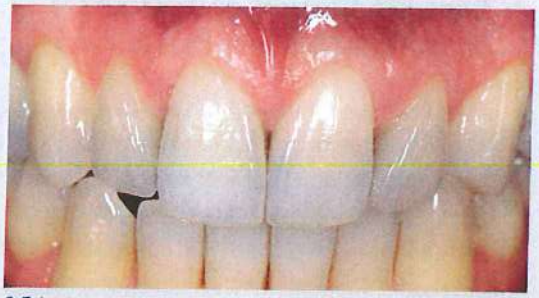

6-5d



6-5e



6-5f



6-5g



t.me/Dr_Mouayyad_AlbtousH

## Type IIB: Closure of interdental black triangles and diastemata

As is the case for malformed teeth, a single and isolated problem can be easily handled using free-hand application of composite resins. However, in the case of multiple diastemata, direct application of composite is a tedious procedure and may not permit adequate and simultaneous control of form, emergence profile, cervical adaptation, and shade. On the other hand, indirect porcelain laminates can overcome these problems, provided that specific tooth preparation is performed.[20] ***Sufficient penetration of the interdental space (Fig 6-6) and meticulous choice of the insertion path of the laminates are imperative in this regard (see Fig 6-43).*** Careful examination of Figs 6-3b to 6-3d reveals insufficient interdental preparation. As a consequence, the interdental space remains open even after the placement of the laminates. One must keep in mind that interdental black triangles constitute a common sequel of *(1)* orthodontic alignment of crowded incisors[35] and *(2)* periodontal disease (Fig 6-7).

Opened cervical embrasures feature the same dilemma as diastemata and have captured the interest of numerous periodontists who developed various sophisticated surgical procedures for the reconstruction of interdental papillae.[36] It appears that the presence of interdental bone is certainly a major prerequisite for the long-term success of such procedures.

***However, interdental black triangles may also be corrected with the rational, nonsurgical approach using the concept of interdental "miniwings."***[37]

Porcelain veneers may reasonably compensate for interdental deficiencies in the soft tissues. However, the natural convex proximal surface of the tooth must be modified. To accomplish this, a slight interdental extension is made, respecting the emergence profile of the crown. The interdental contact point becomes an interdental contact line or ridge (Fig 6-6a; see also Fig 6-43).

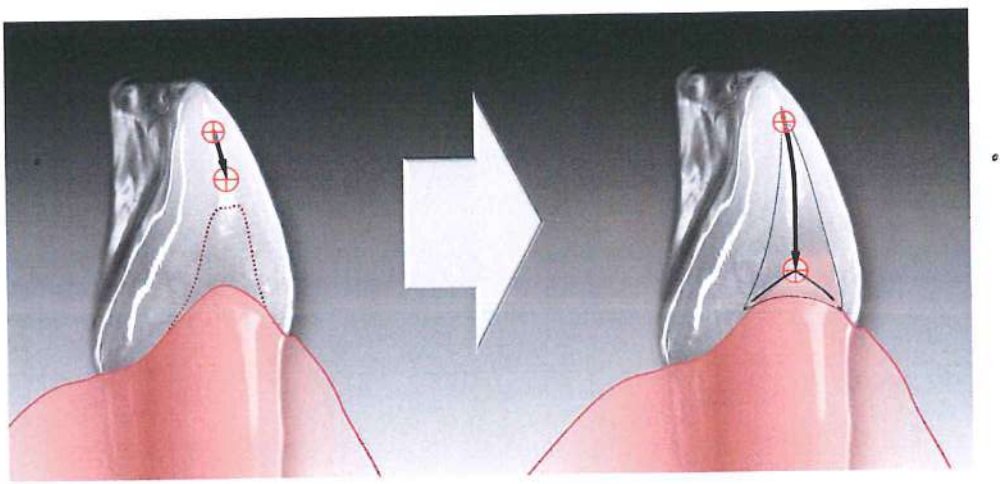

6-6a

**FIG 6-6 Dilemma of missing papillae solved with pyramidal "miniwing."** *(a)* When the interdental papilla is missing, the natural morphology of the tooth must be modified to elongate the contact near the gingiva. *(b and c)* When applying this principle with porcelain veneers, the preparation must extend interdentally toward the lingual aspect to include the modified surface *(yellow arrows)*. Intrasulcular preparation is necessary for the contact ridge to emerge naturally *(pink arrow)*. Note also the increased saturation of the gingival aspect of the miniwing *(pink area in b)*. *(d)* The patient is instructed to floss underneath the contact and wrap the tooth to reach the margin. *(e and f)* Preoperative and postoperative views of the same case with two veneers on the lateral incisors (the same case is presented in chapter 1, Fig 1-28).



t.me/Dr_Mouayyad_AlbtousH

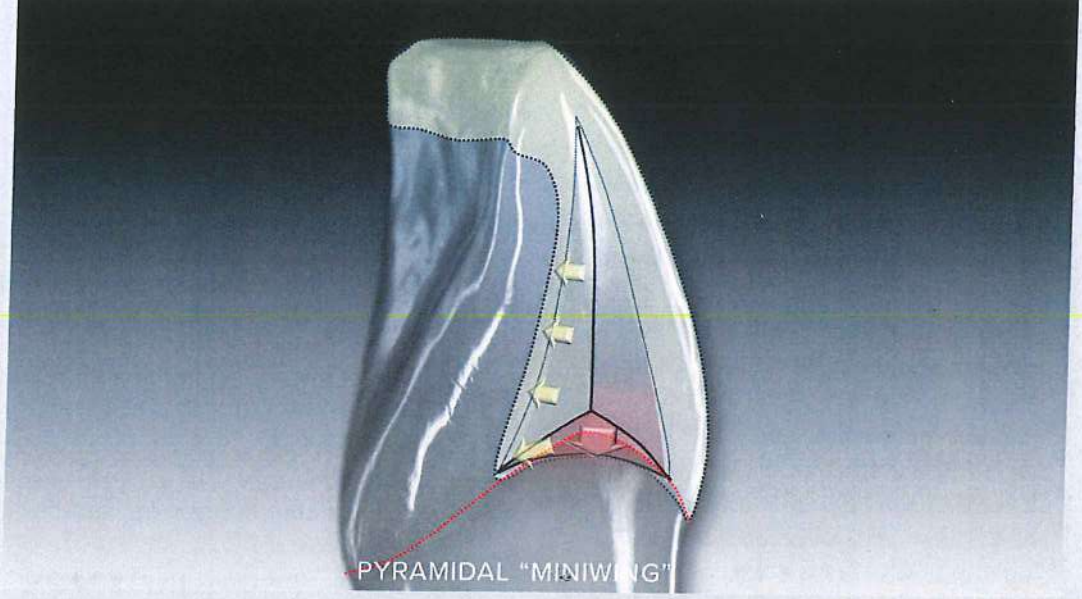


6-6b



6-6c



6-6d



6-6e



6-6f



t.me/Dr_Mouayyad_AlbtousH

*The principle of interdental closure using the miniwing concept is even more significant when dealing with implant-supported restorations and is described in chapter 1 (see Figs 1-30 and 1-31).*

From the tooth preparation perspective, the margins should be extended to include a maximum of the interdental surface to correctly design the miniwing, which may conflict with the insertion axis, especially with tapered teeth. ***A frontal insertion path must be chosen for a more conservative preparation design (Fig 6-7h; see explanation in Fig 6-43).***

A special master cast (ie, soft tissue cast), providing the ceramist with the complete morphology of the gingiva, is imperative (see cast in Fig 6-62). It is important to mention that a dentinlike ceramic of a higher chroma must be used in the interdental area (see Fig 6-7m) in order to approximate the chroma of the gingiva. Dental technicians may also include pink pigments in this area. These combined morphologic (contact line) and optical (saturation) effects are unique to the interdental miniwing concept. With the color and saturation of the interdental extension contrasting from the remainder of the crown, the natural slightly tapered shape of the anatomical crown can be "optically" preserved despite the apparent "excess" of interdental volume. Absolute closure of the interdental space requires intrasulcular preparation margins (see Fig 6-6b; see also explanation in Fig 6-44). The gingival fiber apparatus is not affected by such modification of the interdental design,[38] and a long-term esthetic success can be established.

***Essentials for miniwings* (see also Figs 6-43 and 6-44):**

**Preparation:**

- Intrasulcular margin for optimal emergence
- Maximum extension of the interdental margin toward the palatal to design the miniwing
- Frontal insertion path for maximum tissue conservation

**Restoration miniwing:**

- Pyramidal shape (see Figs 6-6a and 6-6b) with one of the vertices serving as a long interdental contact line to close the gap toward the gingiva
- Opaque dentin base to block the background of the oral cavity
- Higher chroma to optically separate the miniwing from the anatomical shape, possibility to include pink/red pigments to remind of the papilla

**FIG 6-7 Type IIB indication: Comprehensive treatment of severe sequelae following rapidly evolving periodontitis.** The patient was addressed by the periodontist (Dr Bertrand Dubrez, Lausanne, Switzerland) after treatment for rapidly evolving periodontitis. *(a and b)* The situation was stable, but severe loss of soft tissue combined with tooth migrations, diastemata, and excessively long clinical crowns (unrealistic crown width/height ratios) was compromising the esthetic outcome. After adequate diagnostic steps including an orthodontic setup *(c and d)*, redistribution of spaces was established *(e)*. (Orthodontic treatment by Prof Ali Darendeliler, University of Sydney.) The patient refused orthodontic treatment of the anterior mandibular teeth. *(f)* The postorthodontic phase was followed by diagnostic steps (including wax-up) and tooth preparation. *(g and h)* Maximum penetration of the interdental space was required. *(i)* Facial reduction must be carefully controlled using a horizontally sectioned silicon index derived from a wax-up. A horizontal path of insertion with a palatal butt margin had to be chosen to avoid excessive loss of intact tooth substance and allow for maximum preservation of enamel *(h;* see schematic design in Fig 6-43b*)*. *(j)* The porcelain laminate veneers present a specific architecture comprising interdental miniwings that compensate for the loss of the papillae. *(k)* Despite the excessive thickness of the remaining incisal edges, the incisal edge of the veneers can be kept thin and delicate by augmenting the facial curvature and by slightly undercontouring the palatal margin. *(l)* Following luting procedures, the excess enamel was removed with fine diamond burs, and the teeth were polished with silicon rubber points; a stabilization wire was then immediately bonded to the palatal surfaces (see *s*). *(m and n)* The postoperative view still shows slight interdental openings, but they are limited by the long proximal contact lines. Note the sophisticated layering effects of the porcelain (veneers fully layered on refractory dies), which reproduces the different shades and translucency of the antagonistic teeth *(o)* and the harmonious relationship of incisal edges with the lower lip contour *(p and q)*. *(r to t)* The outcome is stable after 6 years of clinical service, and those veneers remained in service for at least 18 years. The thin and delicate periodontium shows excellent tolerance for the restorations. (Parts *f* and *m* reproduced with permission from Belser et al.[20])



t.me/Dr_Mouayyad_AlbtousH



6-7a



6-7b

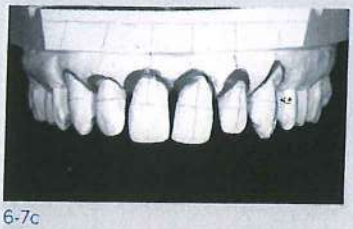

6-7c

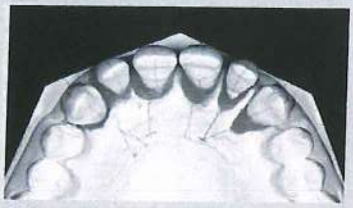

6-7d



6-7e



6-7f



6-7g



6-7h



6-7i

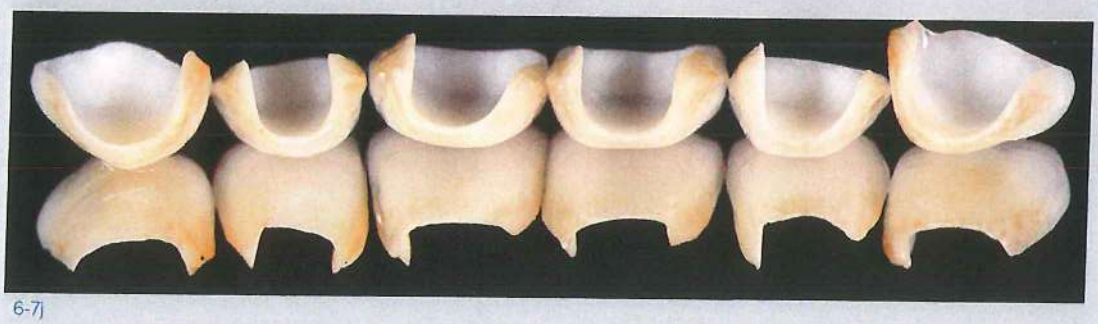

6-7j



t.me/Dr_Mouayyad_AlbtousH



6-7k

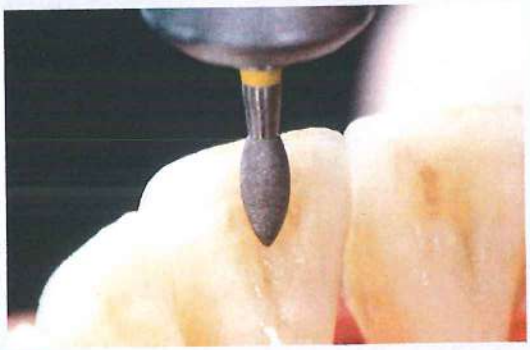

6-7l



6-7m



6-7n



6-7o



t.me/Dr_Mouayyad_AlbtousH



6-7p



6-7q




6-7r

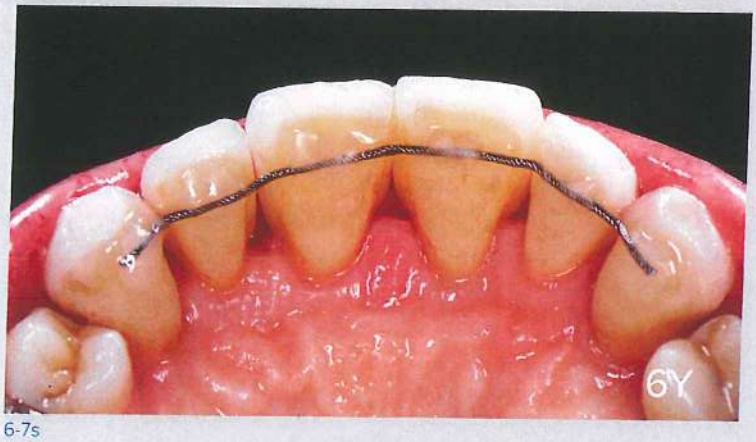


6-7s




6-7t



t.me/Dr_Mouayyad_AlbtousH

## Type IIC: Augmentation of incisal length and prominence

As explained in chapter 2, accelerated aging tends to reverse the so-called "cohesive forces" of the smile (see Fig 2-13). By this token, it is not uncommon to treat patients wishing to recover incisor prominence, especially those who are influenced by younger models in fashion magazines. It is easy to understand this trend toward younger and whiter smiles that logically fulfills the principle of dominance described by Lombardi[39] (dominance of the mouth within the face, dominance of central incisors within the smile).

To achieve that goal, direct restorative materials can be applied, knowing that composite resins may present signs of fatigue (wear and chipping-type fractures) especially at the incisal edge (Fig 6-8).[40,41] A perfect result cannot be guaranteed in the long term using direct composite additions[42] due to slight alterations of clinical crowns (loss of anatomical form) progressively developing as a result of labioincisal wear. When informed properly, many patients, however, will still accept those shortcomings due to the conservative and socioeconomic advantages of direct composite resins.

When the entire smile of the patient is to be reconsidered, the previously mentioned limitations of direct techniques are combined with the difficulty of simultaneously mastering both general form and length of the teeth involved. Consequently, many clinicians prefer porcelain veneers to ensure a more predictable result, especially in the long term (Figs 6-5 to 6-8).[18–20,24,43,44] ***The patient should be informed of the reasons for the moderate sacrifice of sound tooth structure, the costs involved, and the need for a master ceramist to ensure the esthetic result.*** Restoration of incisal length and prominence is not only an esthetic matter; the recovery of crown stiffness is also ensured through the restoration of the initial volume of the tooth (simulation of the original enamel thickness by the porcelain).[21,23,29,45,46] A usual concern is the modification of the anterior guidance. As there seems to be an association between the absence of anterior guidance (ie, open bite) and temporomandibular disorders,[47] a key element in the development of harmonious occlusion is therefore the incisal guidance,[48,49] the steepness of which appears to be unimportant for neuromuscular harmony.[48] ***Whenever the envelope of function of a patient is modified, the best practice is to test the new design over a few days or weeks using the most important diagnostic tool, the mock-up.***

**FIG 6-8 Recovery of esthetics and function in anterior teeth of a demanding patient.** *(a to d)* The patient repeatedly complained about anterior tooth shape, especially insufficient length (crown width/height ratio > 90%) and unstable anterior guidance. Composite resin restorations were originally placed by another clinician to restore the incisal edges of the maxillary anterior teeth *(c)*. The diagnostic approach included a laboratory-made acrylic mock-up (see chapter 5, Fig 5-13). Significant improvements occurred after the veneering procedure (incisal ceramic coverage of about 3 mm), including harmony of incisal edges with the lower lip line *(e)*, improved width/height ratio (now about 84%) of the clinical crowns *(f)*, and improved function *(g)*. *(h)* An obvious and frequent sign of improved patient self-confidence is a change in hair styling. The specific changes related to the incisal edge line are detailed in *i* and *j*. (Parts *b*, *e*, *i*, and *j* reproduced with permission from Magne and Douglas.[30])



t.me/Dr_Mouayyad_AlbtousH



6-8a



6-8b



6-8c



6-8d



6-8e



6-8f



6-8g



6-8h



t.me/Dr_Mouayyad_AlbtousH

To minimize stresses during tooth-guided protrusive movements, some clinicians reduce the length of esthetically correct teeth. This inadequate approach results in a reverse smile line and may age the patient significantly.[49] As proven clinically,[24] there should be no fear to rejuvenate the patient's smile by increasing central incisor prominence and length because ideal occlusion refers to both an esthetic and physiologic ideal.[48,50]

Another reason not to systematically distribute the anterior guidance over a maximum number of teeth is the favorable mechanical behavior of BPRs.

***In other words, the functional features of teeth restored by BPRs can be considered identical to those of intact natural teeth.*** Particular emphasis must be given, however, to the maintenance or reestablishment of an adequate and functional anterior guidance regardless of whether this guidance involves the new restorations or not.

There is no scientific evidence indicating that this ideal occlusal status is not applicable to previously worn dentitions and patients with occlusal parafunctions. In fact, BPRs placed in worn, fractured teeth in the early 1990s (at a time when dentin bonding was clearly suboptimal) and followed over 5 years fared favorably compared with traditional porcelain veneers and inlays.[19] This favorable success rate is empowered by the minimally invasive approach, which should always be first choice for patients with worn dentitions.

> Whether restored or not, those higher-risk patients (predicted to overload their dentition) should be equipped with a dental "helmet"—ie, an appropriate occlusal splint to wear at night.

In any case, but especially for indication types IIC and IIIA (see next section), the comfort, functional, and esthetic outcome should be anticipated by a specially developed diagnostic strategy[21,51–56] (wax-up/mock-up, described in detail in chapter 5, sections 5.5 to 5.8) to reversibly redefine an adequate smile line that also matches the unique and individual character and personality of the patient (Figs 6-8i and 6-8j). In most cases, recovery of anterior tooth prominence occurs through the important social and personal impact ultimately reported by the patient (compare Figs 6-8a and 6-8h).[24]

**FIG 6-8** *(cont)* The lower lip line proved extremely important in guiding the new incisal edge configuration (see chapter 2, Fig 2-13). *(i)* Originally, the lower lip line and incisal edge line did not complement each other, producing visual tension. *(j)* About 2 mm had to be added to the central incisors to achieve a more harmonious situation. In some specific situations, the lower lip has been modeled by inadequate preexisting restorations. Under such circumstances, it is highly recommended to "deprogram" the lip using the acrylic mock-up for 1 to 2 weeks (see example of lip remodeling by the mock-up in chapter 5, Fig 5-11).[21]



t.me/Dr_Mouayyad_AlbtousH



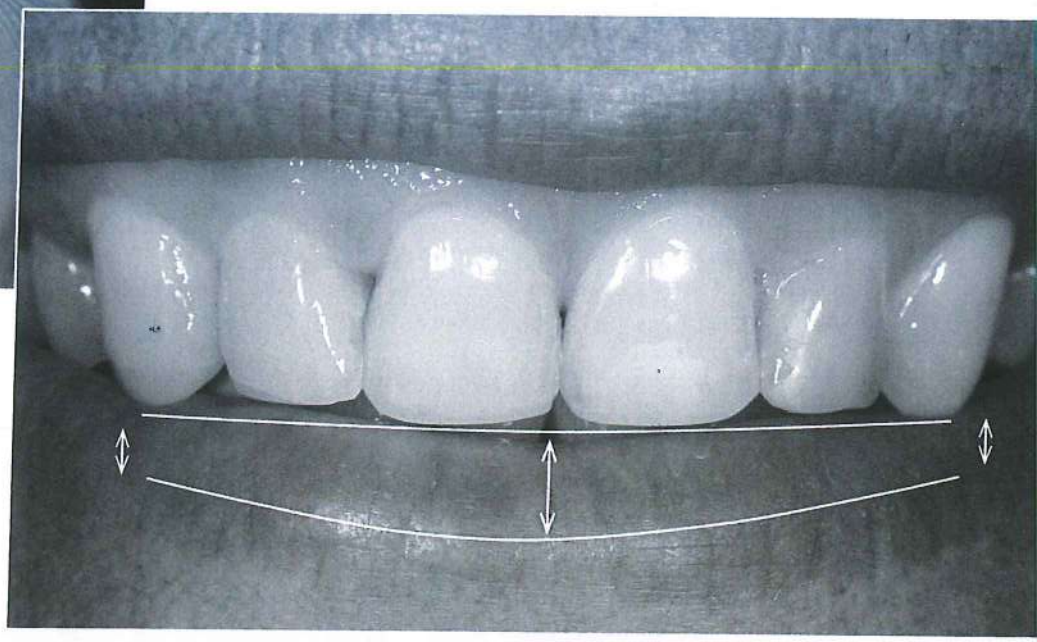

6-8i



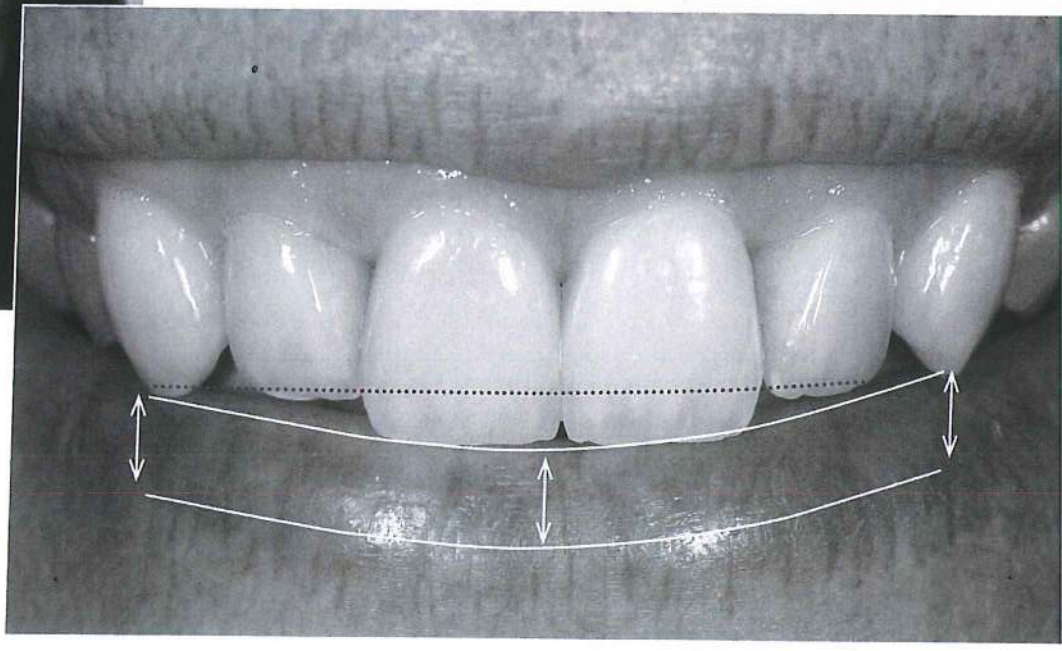

6-8j



t.me/Dr_Mouayyad_AlbtousH

***As was said for type I indications, there are no reasons for not veneering nonvital teeth with type II indications (Fig 6-9), perhaps even in the case of severe breakdown of tooth substance, which is discussed in section 6.6.***

Generally, it is not recommended to overlap the endodontic access cavity with the veneer, nor are posts recommended. Use of a traditional glass-ionomer cement (GIC) as a dentin replacement in the endodontic access will provide higher color stability (see chapter 3, Figs 3-19 and 3-20). All these precautions allow an easy reentry to the original pulp chamber and permit eventual rebleaching when required.

There is some evidence that the type of incisal finish line to be recommended is a function of the type and amount of incisal coverage. The palatal minichamfer, which is routinely used, should be replaced by a simpler finish line like a butt margin,[23,57] especially in the presence of worn incisors. These options are scientifically explained later in this chapter in view of functional stress distribution during protrusive movements of the mandible (see Figs 6-32 to 6-37).



6-9a



6-9b

**FIG 6-9 Recovery of central incisor prominence in an aging smile.** *(a and b)* The patient's main complaint was the lack of volume and length of both central incisors. *(c)* The left central incisor is nonvital and discolored. *(d)* Preparatory steps included internal bleaching of that tooth and replacement of preexisting interdental composites. The endodontic access preparation was partially filled with GIC, then covered with a layer of composite resin (see chapter 3, Figs 3-19 to 3-21). *(e to g)* Porcelain veneering allowed substantial recovery of the facial coronal volume and length. The lower lip has "remodeled" itself to perfectly conform to the newly defined incisal edges *(f)*. *(h)* Intraoral view after more than 4 years of clinical service. The intact teeth have aged and darkened, while the veneered teeth and related periodontium remain unchanged.



t.me/Dr_Mouayyad_AlbtousH

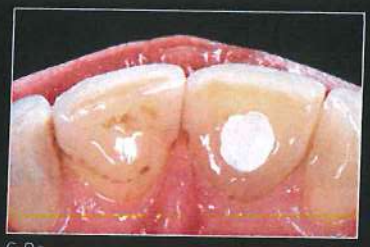

6-9c

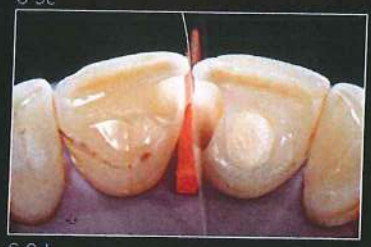

6-9d

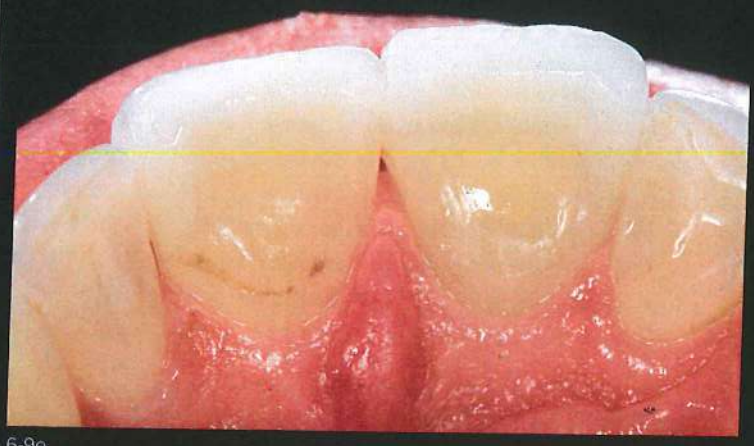

6-9e



6-9f



6-9g



4Y

6-9h



t.me/Dr_Mouayyad_AlbtousH

## 6.4 TYPE III: EXTENSIVE RESTORATIONS IN ADULTS

Extensive rehabilitations of compromised anterior dentitions in adults include severe coronal fractures (type IIIA, Fig 6-10), extensive loss of enamel (type IIIB), and malformations (type IIIC).

These challenging types of damaged dentitions usually involve a majority of the coronal volume or the tooth surface.

***In children, such defects should be treated with composite resin materials (direct or semidirect techniques) until the dentition reaches eruptive and functional stability.***

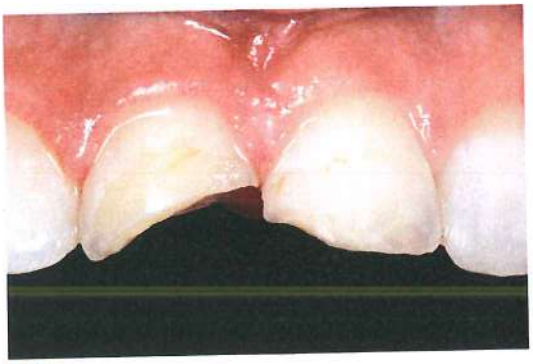

6-10a

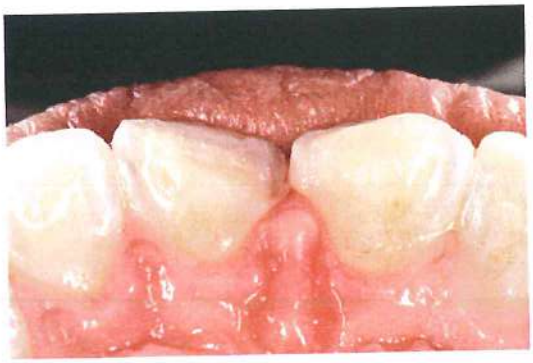

6-10b



6-10c

**FIG 6-10 Conservative treatment of severe crown fractures.** *(a)* Facial preoperative view. *(b)* Due to previous trauma, significant volume of central incisors has been lost (palatal view). The fracture line ends paragingivally at the mesial aspect of the right central incisor. *(c)* Hard tissue loss estimated at more than 5 mm in height is evident (silicon index from wax-up). (Part *a* reproduced with permission from Magne and Magne.[58])



t.me/Dr_Mouayyad_AlbtousH

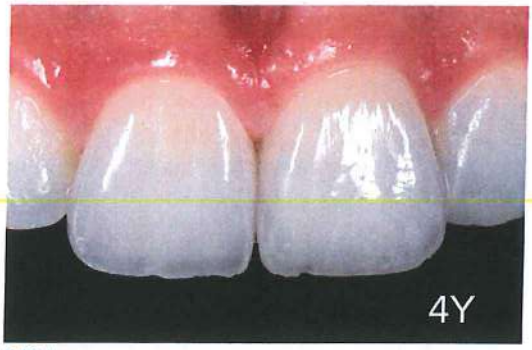


6-10d

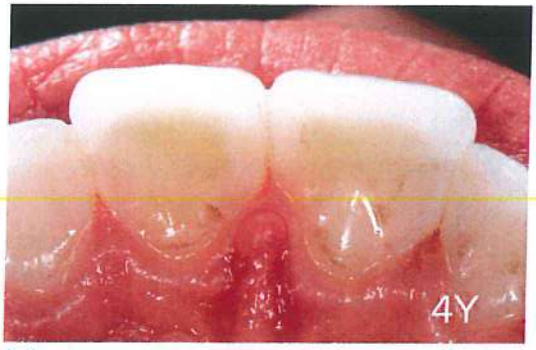


6-10e




6-10f




6-10g




6-10h

**FIG 6-10** *(cont) (d to g)* Final type IIIA BPRs (bonded only to enamel because dentin bonding was still under development at the time of placement) 4 years later. *(e)* Light enamel stains are detected on the palatal aspect, but clinical marginal adaptation and seal are not altered. *(f and g)* Additional clinical view after 4 years. *(h)* No porcelain failures are recorded even after 8 years of clinical service despite obvious function and marked anterior guidance. Note the optimal esthetic integration with the lips, which was established through specific diagnostic steps. The details of ceramic layering for this specific case are shown in Figs 6-66 and 6-67. Similar type IIIA cases with 10 and 27 years of follow-up are presented in Fig 6-21 and chapter 7, Fig 7-1, respectively. (Part *h* reproduced with permission from Magne and Magne.[25])



t.me/Dr_Mouayyad_AlbtousH

## Type IIIA: Extensive coronal fractures

Porcelain veneers allow the tooth vitality to be maintained despite the considerable coronal breakdown. As previously mentioned, in children, such teeth would be preferably treated with direct composite resins as medium-term transient restorations, rather than porcelain restorations, which should be used in the adult. Extensive incisal edge spans of ceramic material had been investigated already in the 1990s[23] and applied clinically with success (see Fig 6-10; see also Fig 6-21).[24] For severely fractured incisors, ***the extreme design of the restorations suggests that terminology may need to be changed: Can we still call these restorations "laminates" or "veneers"? Hence the term*** **bonded porcelain restorations.**[24]

Only a limited number of scientific studies have explored this new field of indications. Wall et al[43] demonstrated that up to 2 mm of incisal edge span of ceramics could be created on mandibular incisors without affecting the ultimate coronal strength, but Andreasen et al[15] may have been the first authors to study the treatment of crown-fractured incisors with laminate-type BPRs in the early 1990s. Their in vitro investigation surprisingly claimed ultimate coronal strengths of restored teeth far exceeding those of intact teeth (Fig 6-11a). This conclusion is even more affirmative today considering the progress of dentin bonding (IDS) and luting procedures (use of preheated highly filled composite resins instead of resin cements). However, dentin adhesion might not be as critical as initially thought for this type of indication. It was clearly demonstrated that the potential of the concept lies in the design of the restoration, which is explained through favorable load configuration, geometry, and tissue arrangement of maxillary incisors (Figs 6-11b and 6-11c).[23,45] As a consequence, coronal strength proves to be sufficient even when using BPRs with extensive incisal edge spans of ceramics. In a clinical evaluation, no problems were detected when up to 5.5 mm of average free-standing feldspathic material was used.[24]

BPR-restored crowns featuring extensive incisal edge spans of ceramics are characterized by their "low-stress" design and increased crown stiffness when compared to intact teeth.[59] As mentioned in chapter 1, however, flexibility proves to be an essential quality in any structure. Otherwise it would be unable to absorb the energy of a traumatic blow. Up to a point, the more resilient a structure, the better.[59,60]

**FIG 6-11 Strength of intact and fractured incisors restored with different treatment modalities.** *(a)* The results of several studies by Andreasen et al[14,15,66] have been combined in this graph. Ceramic restorations consisted of traditional facial laminates (no incisal coverage) except for the last group (fractured tooth + bulk veneer), which featured the highest average strength and corresponded to teeth for which the veneers included the missing part of the incisal edge as well the facial surface. Groups that were not statistically different are linked by vertical lines on the left. When supplemented with a porcelain veneer, both the fragment reattachment and the composite resin buildup behaved similarly to the natural intact tooth (*), suggesting the most biomimetic behavior. Note the extreme standard deviations inherent to catastrophic failure testing. Facial loading was applied *(light gray arrowheads)*.



t.me/Dr_Mouayyad_AlbtousH

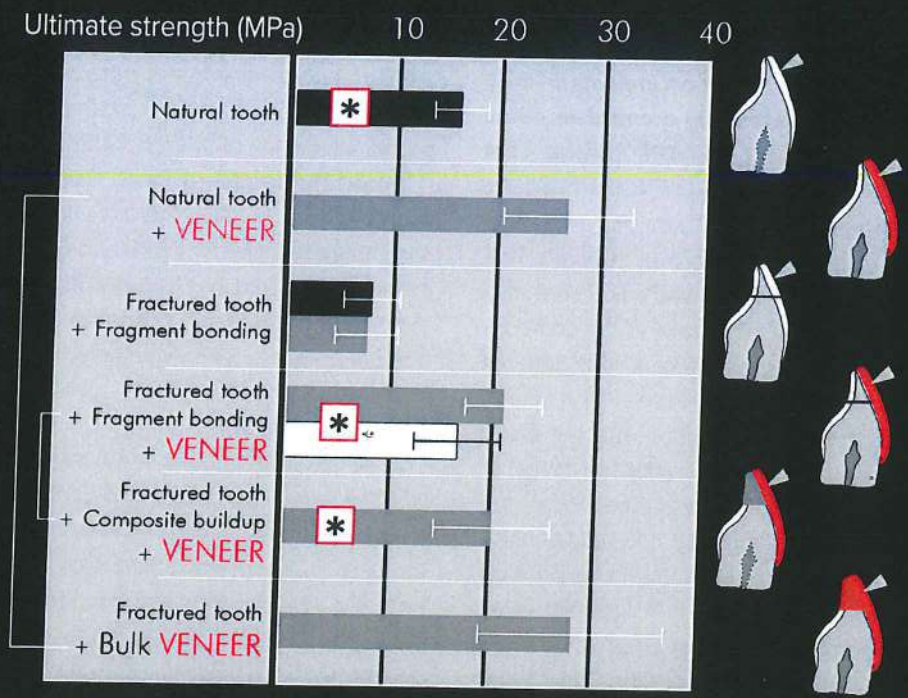


6-11a

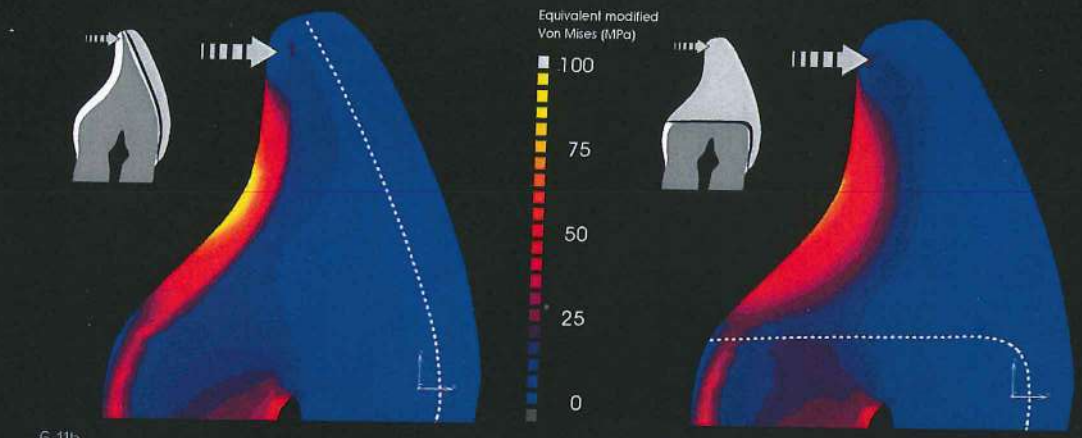


6-11b

6-11c

**FIG 6-11** *(cont) (b and c)* Modified Von Mises stress distribution throughout the buccolingual sections of restored incisors (finite element analysis). The *thick dotted arrow* shows the location and direction of the 50 N load. The *white dotted line* represents the luting composite. Despite extreme differences in the design of the restoration, the tooth restoration interface and the restoration itself are not subjected to elevated stresses for both the minimum veneer *(b)* and the extreme veneer restoring the fractured tooth *(c)*. In both cases, the interface does not cross the palatal concavity. Stresses in the remaining palatal enamel are even higher in *b* compared to stresses at the same location in the concavity of the ceramic piece in *c*. The two incisors are restored with the same feldspathic ceramic. See also Figs 6-32b and 6-33 for other types of designs and related stress distributions.



t.me/Dr_Mouayyad_AlbtousH

***Further research is required to determine whether modulated strength through higher compliance designs might be indicated—that is, by including underlying composite resin buildups and using a type I BPR instead.*** This modality was included in the load-to-failure study by Andreasen et al[15] (see Fig 6-11a) and yielded favorable ultimate crown strength. The related stress distribution was calculated in a finite element study.[23] Presence of the composite provides a significant effect, simultaneously allowing the decrease of stresses in the palatal concavity (stress redistribution into the more "flexible" composite) and relocating the margin of the veneer into the "safe" incisal area. Underlying composite buildups must be carefully considered with regard to the high thermal expansion of some composite resins.[61–64] Gresnigt et al, however, demonstrated that ceramic veneers bonded to teeth with large existing Class 3 and Class 4 restorations provided favorable results.[65] Additional considerations about this topic are presented in Fig 6-36.

Rebonding of the fractured tooth fragment,[66,67] when possible, is also indicated because it has been proven to give good results when supplemented with a veneer (see Fig 6-11a).[14] In fact, this treatment modality seems ideal prior to placement of a porcelain veneer because of uniform thermal expansion and the absence of hygroscopic expansion of the rebonded fragment.

When the fractured tooth fragment is not available, the simplified "ceramic only" design is recommended (see Figs 6-10 and 6-12) because it is straightforward and features optimal esthetic results, provided that the ceramist uses specific porcelains to reproduce the anatomy and optical characteristics of the missing dentin core (see Figs 6-65 and 6-66).

Fractured mandibular teeth can be treated with the same approach (Fig 6-12). Even though functional stresses can generate tensile forces at the facial surface of mandibular incisors (see chapter 1, Fig 1-7), this does not constitute a contraindication for BPRs. Due to the favorable facial geometry of mandibular incisors, the morphology of which displays flat or soft convex contours, such facial tensile stresses remain moderate. The loading configuration of mandibular teeth (ie, facial load) was reproduced in studies by Wall et al[43] and Andreasen et al[14,15] and yielded favorable results compared to intact teeth.

**FIG 6-12 Long-term follow-up of type IIIA BPRs.** *(a)* This case features combined indications for BPRs: recovery of incisal prominence in the maxilla and definitive restoration of right central and lateral mandibular incisors previously restored with composites. *(b)* Marked anterior guidance ensures adequate function, and the situation remains stable as illustrated by this general view after 3 years of clinical service (including BPRs on the maxillary central incisors and left lateral incisor and canine). *(c and d)* Detailed views at the time of tooth preparation of the mandibular left central and lateral incisors and after placement of the BPRs, respectively. *(e and f)* The patient was reexamined during the 19th year of clinical service, and clinical photographs show a perfect stability of all the BPRs. Additional views of this case as well as diagnostic procedures are presented in chapter 5 (Fig 5-11).



t.me/Dr_Mouayyad_AlbtousH



6-12a




6-12b



6-12c



6-12d




6-12e




6-12f



t.me/Dr_Mouayyad_AlbtousH

## Type IIIA: Application to implant abutments

Adhesive restorative principles appear to be extremely valuable also in the implant realm. Figure 6-13 illustrates the translational application of type IIIA veneers used to restore a dental implant with limited interdental and labial clearance.[68] The patient was missing his mandibular right lateral incisor due to trauma. The residual interdental space had partially collapsed and was narrower than the width of the central incisor. In spite of the reduced space and thin osseous ridge, the implant was successfully placed and osseointegrated (including guided bone regenerative procedure). A screw-retained provisional crown was used to shape and condition the peri-implant soft tissues. For the definitive restoration, ***a screw-retained custom porcelain-fused-to-metal (PFM) abutment was fabricated first with the porcelain simulating a preparation for a type III BPR. The corresponding BPR was then obtained by full-thickness layering of feldspathic porcelain over a refractory die replica of the abutment.*** Fabrication of a classic abutment and a crown was not possible due to the lack of interdental restorative space. The novel design was also justified by the subgingival implant shoulder and presence of the screw access channel through the center of the incisal edge. Hence, the traditional principles of retention and resistance form of the abutment were substituted by the strong and reliable porcelain-to-resin-to-porcelain adhesive approach.



6-13a

**FIG 6-13 Long-term follow-up of a type IIIA feldspathic BPR bonded to a custom PFM implant abutment.** *(a)* Those two elements (type IIIA BPR and PFM abutment) are layered with the same feldspathic porcelain. *(b)* Preoperative view of anterior teeth with missing mandibular right lateral incisor and narrowed mesiodistal space. *(c and d)* Occlusal and labial views just before transfer impression for the fabrication of a provisional restoration. Note the position of the screw at the center of the incisal edge. *(e to g)* In order to provide the illusion that the tooth is wider than the space, concavities *(arrow,* inverted miniwings) were made at the mesial and distal surface of the screw-retained provisional crown. *(h)* Intraoral view of the polymethyl methacrylate (PMMA) provisional restoration. (Parts *b* and *c* reproduced with permission from Magne et al.[68])



t.me/Dr_Mouayyad_AlbtousH



6-13b



6-13c



6-13d



6-13e

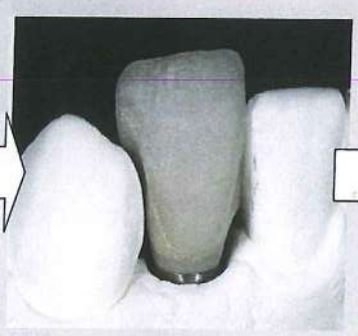

6-13f

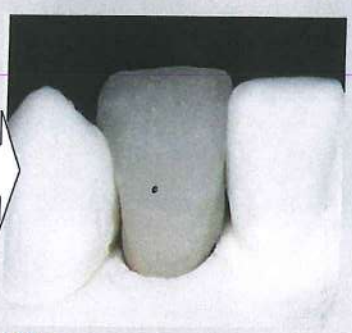

6-13g



6-13h



t.me/Dr_Mouayyad_AlbtousH

This concept opened the door to further research to validate its feasibility with other types of abutment (zirconia, metal-zirconia, and metal-polymer),[69–72] as well as the development of histoanatomical bilaminar assemblies (see chapter 1, Fig 1-32b).[73]

With the use of specific material-dependent primers and adhesive protocols, the bond of the nonretentive restoration was strong enough to induce abutment fractures rather than debonding (under fatigue loading).[69] ***Nonretentive metal-composite resin abutments constitute an interesting alternative to zirconia due to their flexibility and ability to simulate the damping behavior of the natural tooth.***[71,74] Further clinical research should be conducted to validate these new concepts.

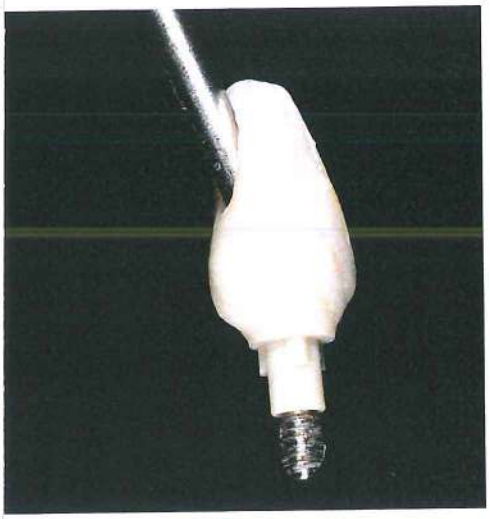

6-13i

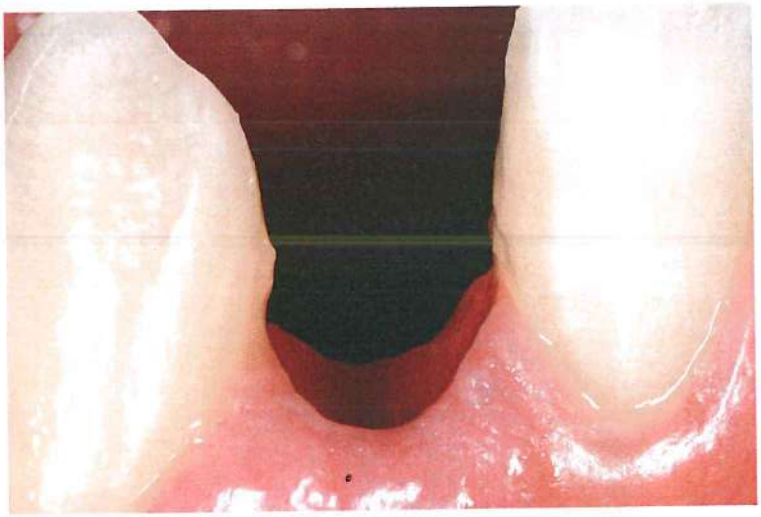

6-13j

**FIG 6-13** *(cont) (i)* Note the unfavorable angulated access of the screwdriver for the provisional restoration. *(j)* The soft tissues were conditioned appropriately by the PMMA crown, and a harmonious gingival scalloping was obtained. *(k)* The final restoration had to be designed in two parts, perfectly fitting to each other; note the interdental concavity of the BPR, similar to that of the provisional restoration *(arrow)*. The PFM abutment was etched, cleaned, and silanated extraorally before careful delivery under rubber dam *(l)*, and the BPR was similarly etched, cleaned, and silanated before bonding using a preheated restorative composite resin *(m)*. Teflon tape was placed over the abutment screw before bonding the restoration. Note the beautiful clinical integration *(n)* and excellent stability during the 8th year of clinical service *(o)*. (Parts *k* to *n* reproduced with permission from Magne et al.[68])



t.me/Dr_Mouayyad_AlbtousH



6-13k

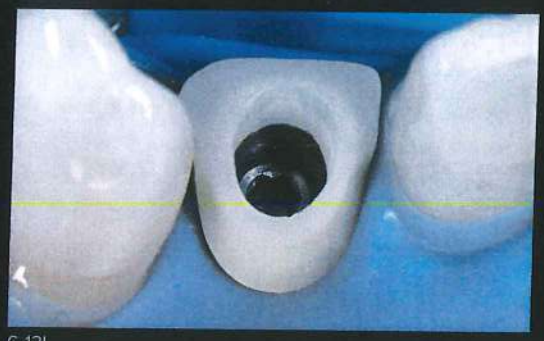

6-13l



6-13m



6-13n




6-13o



t.me/Dr_Mouayyad_AlbtousH

## Type IIIB: Severe loss of enamel

Extensive tooth attrition/abrasion is logically found in people of older age groups because of the longer exposure to function; of the maxillary teeth, the anterior ones are often worn more, and concomitant biocorrosion is not uncommon (Fig 6-14). Erosive tooth wear (ETW), however, is also an expanding problem in younger individuals across the globe[75–77] due to dietary (especially soft drinks and possibly vegan diets) and gastric acids (gastroesophageal reflux disease [GERD] and eating disorders)[78]; bulimia, consumption of acidic foods, acid reflux, and chlorine consumption (from swimming) constitute typical etiologic factors in the young patient. Tooth biocorrosion, particularly in young people, presents a considerable challenge to restorative dentists.

***Identifying associated factors of enamel loss and controlling them is the main tenet in the treatment of ETW. In all cases, preventive and conservative strategies are essential.*** Use of neutralizing mouth rinse (eg, bicarbonate solution) and topical application of desensitizing agents and neutral fluoridated gels are recommended. Because the effect of fluoride on ETW is less prominent than for caries (due to the higher pH of bacterial acids), additional fluoride sources, preferably containing stannous fluoride ($SnF_2$), should be used (toothpaste or rinse).[78]

From a restorative perspective, conservative adhesive dentistry should be used whenever possible rather than traditional prosthodontic approaches. Resin coating of the tooth surfaces (preferably with a filled light-cured dentin bonding agent) and small composite resin restorations should be the first choice.[79] For more extensive cases, large composite resin restorations are still indicated (direct or CAD/CAM) due to their cost-effectiveness and minimally invasive approach and are presented in chapter 5, Figs 5-25 to 5-27.

Other examples of severe biocorrosion cases treated with type IIIB porcelain veneers are presented in Figs 6-80 and 6-83.



6-14a



6-14b



6-14c

**FIG 6-14 Enamel biocorrosion of maxillary anterior teeth.** *(a to c)* The patient presented with severe facial wear of the maxillary anterior teeth and infiltrated Class 3 composite resin restorations. Note the definite dentin exposures on the facial surface of both central incisors *(b)*. Treatment planning included replacement of the preexisting restorations, and the teeth were prepared according to a diagnostic template (wax-up and mock-up). *(d)* Note the proximal margins extending within the new interdental restorations (especially between the central and lateral incisors) to minimize the volume of remaining composite restorative material. *(e to g)* The final porcelain restorations feature minor changes of tooth form and length but substantial recovery of the facial volume.



t.me/Dr_Mouayyad_AlbtousH



6-14d



6-14e



6-14f





6-14g



t.me/Dr_Mouayyad_AlbtousH

***Bonding to the biocorroded dentin requires special attention. Systematic use of coarse diamonds for dentin preparation is recommended prior to dentin bonding,[80,81] and even more so when bonding to eroded dentin.[82]*** Because coarse diamonds generate a thick smear layer, use of a total-etch three-step dentin bonding system is preferable. Pretreatment with $SnF_2$ does not seem to impede the resin-dentin bond to the eroded dentin.[83]

Extensive enamel loss in more demanding patients can also be treated with semi-(in)direct techniques and indirect BPRs. Tight bites sometime require the restoration of posterior teeth (increase of vertical dimension of occlusion [VDO]) or the use of deprogramming and occlusal therapy (explained in chapter 5, Fig 5-21). Type IIIB indications can appear somewhat similar to type IIC, but the former features a more generalized nature (often more than four teeth to treat) compared to the latter (which often relates only two teeth). Other type IIIB patients are featured in Figs 6-45 and 6-57. Depending on the case, ***innovative bilaminar restorative designs conjoining lingual composite resin restorations and labial indirect BPRs, in combination with VDO increase, anterior deprogramming procedures, and the Dahl principle still allow a very conservative approach of the most severe cases (see chapter 5, Figs 5-18m to 5-21).***

It goes without saying that IDS is a key element in the process and prognosis of type IIIB BPRs in patients with large dentin exposures caused by ETW. No matter the amount of exposed dentin, it should not be a justification to use full-coverage crowns. The prognosis and strength of BPRs is excellent when using IDS (Fig 6-14i).[32,84]



**FIG 6-14** *(cont) (h and i)* Anterior intraoral views immediately after placement of the six BPRs (preoperative situation in overlay image) and in the 5th year of clinical service, respectively. Note the color stability and stability of the supporting tissues.



t.me/Dr_Mouayyad_AlbtousH



6-14h




6-14i



t.me/Dr_Mouayyad_AlbtousH

## Type IIIC: Generalized congenital and acquired malformations

***A number of localized malformations of the coronal surface can be treated rather conservatively by combining chemical treatments, abrasion, and resin infiltration techniques with freehand composite resin restorations (see chapter 3, Table 3-1).***[85,86] Generalized enamel dysplasia (Fig 6-15), however, requires a more global approach and may be treated successfully and conservatively by means of BPRs, especially when the dentinoenamel junction has not been altered.[30] Type I hypoplastic amelogenesis imperfecta may also be treated successfully with BPRs.[87] As was said for type IIIA indications, direct composite resin restorations can be used as interim restorations in the child prior to the final porcelain bondings, which are preferably used in the adult. Premature placement of porcelain restorations (before age 16 or 18 years) may not be appropriate because of the significant changes that still take place within the dentition (eg, passive eruption and residual alveolar crest growth).

Generalized enamel dysplasia must be distinguished from hypomaturation and hypocalcified amelogenesis imperfecta (types II and III). The latter require particular prudence because the enamel is compromised for bonding[88]; most frequently, a traditional prosthetic procedure remains the treatment of choice,[89] but ***more recent data suggest that amelogenesis imperfecta types II and III may be treated successfully with less invasive bonded ceramic restorations.***[90]



6-15a

**FIG 6-15 Comprehensive treatment approach for generalized enamel dysplasia.** *(a)* The maxillary teeth were previously treated using PFM crowns, which significantly altered the patient's self-confidence and displayed a strong "umbrella effect" on the surrounding gingiva (note the grayish gingiva; see umbrella effect explanation in Fig 6-19). *(b)* The mandibular teeth still exhibit the original surface defects. *(c)* The mandibular situation is additionally complicated by marked crowding. *(d)* The preprosthetic phase included provisionalization of maxillary teeth and extraction of a mandibular incisor followed by orthodontic therapy. (Part *b* reproduced with permission from Magne and Magne.[58])



t.me/Dr_Mouayyad_AlbtousH



6-15b

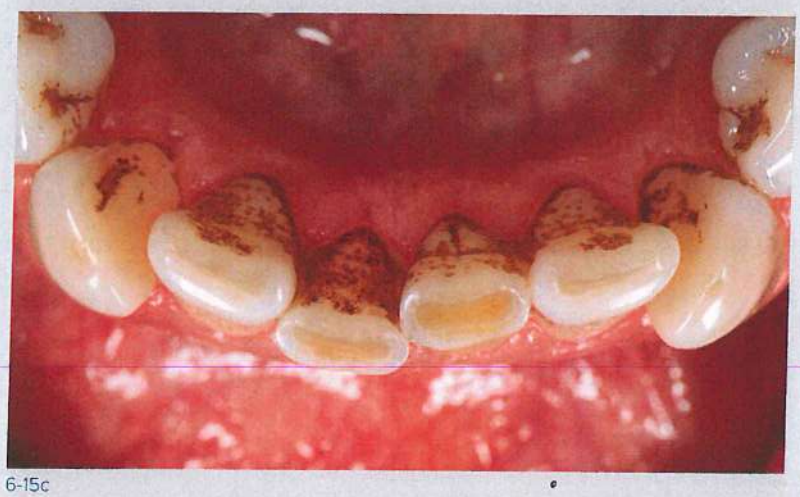

6-15c



6-15d



t.me/Dr_Mouayyad_AlbtousH



6-15e

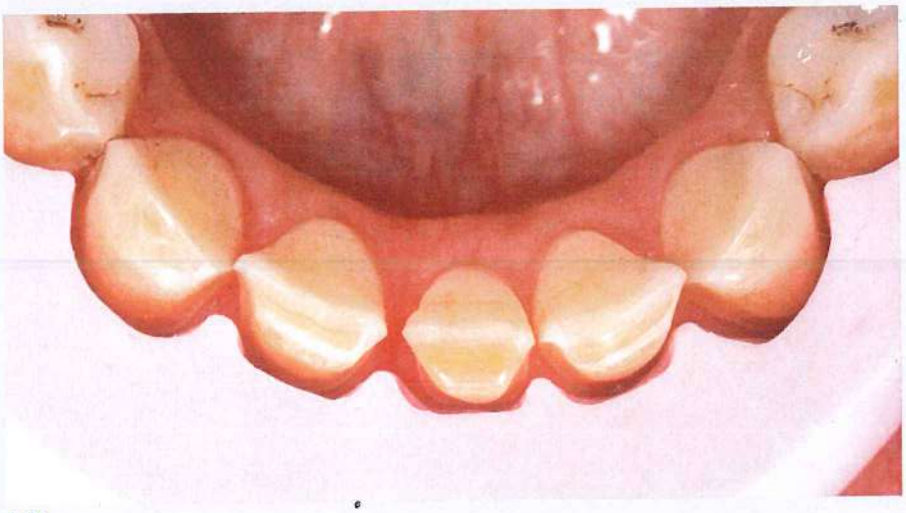

6-15f

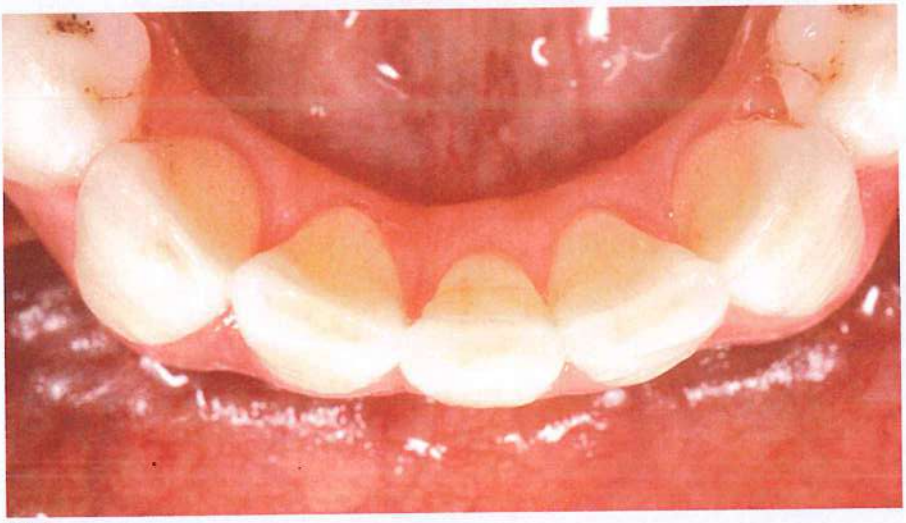

6-15g



t.me/Dr_Mouayyad_AlbtousH



6-15h



6-15i



6-15j

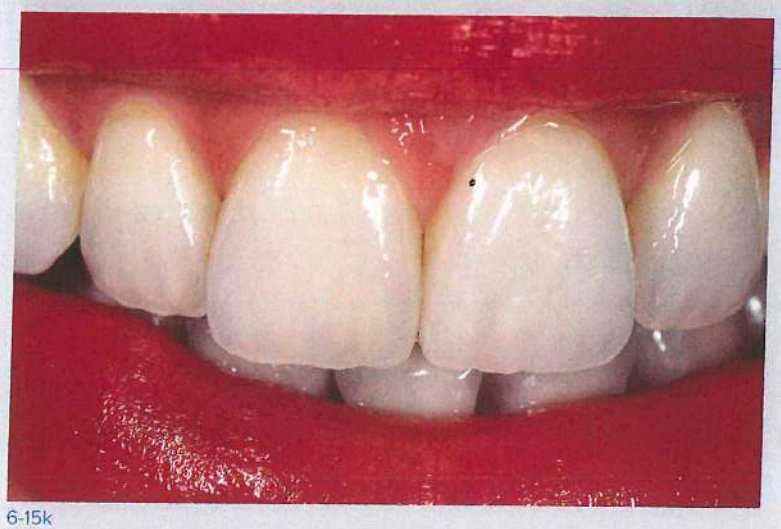

6-15k

**FIG 6-15** *(cont)* Once realigned *(e)*, the mandibular incisors, canines, and first premolars were prepared *(f)*, restored with BPRs *(g)*, and stabilized with a lingual bonded retainer (not shown). Definitive restorations on maxillary teeth were then carried out in a second stage *(h)*, which allowed for the exact shade reproduction of integrated mandibular veneers *(i and j)*. *(k)* Significant impact on the patient's comfort and self-confidence is expected. Detailed steps for the fabrication of mandibular veneers are shown in Fig 6-70.



t.me/Dr_Mouayyad_AlbtousH

# 6.5 COMBINED INDICATIONS

***It is uncommon to find patients with only one reason to justify the use of BPRs. Most patients in this chapter presented a combination of factors that finally led to the decision to use porcelain material in an indirect approach.*** Advanced direct composite resin techniques, such as guided natural layering (see Fig 3-48) could have been used instead of BPRs. High patient expectations and the low maintenance protocol, however, motivated the choice for indirect BPRs. Patients and clinicians should always be reminded that such a choice (BPRs) and the related expectations are concomitant to the collaboration of an experienced master ceramist. Presenting to the patient the respective advantages and shortcomings of each approach and weighing the cost-benefit ratio should allow both the clinician and the patient to reach a comfortable therapeutic decision.

The patient in Fig 6-16 displayed at least three main reasons to use BPRs. The restorations simultaneously resolved the problem of residual discoloration of a nonvital tooth, closed diastemata, and redefined tooth form and length.



6-16a



6-16b



6-16c



6-16d



6-16e

**FIG 6-16 Typical patient with mixed indications for BPRs.** *(a)* Preoperative view: The patient's request includes the closure of interdental spaces between the maxillary incisors. In addition, the left central incisor presents bleaching-resistant discoloration, and analysis of the smile reveals a significant space between the lower lip and maxillary incisors. *(b)* Tooth volume and length were redefined accordingly; the approximate curvature of the lip *(dotted line)* serves as a reference (unprepared teeth and silicon index of the wax-up). *(c to g)* Baseline and corresponding views of tooth preparations and final BPRs. Cohesiveness between the maxillary teeth and lower lip can now be observed. (Patient treated in collaboration with Dr Valérie Métral-Favez, Vevey, Switzerland.)



t.me/Dr_Mouayyad_AlbtousH



6-16f

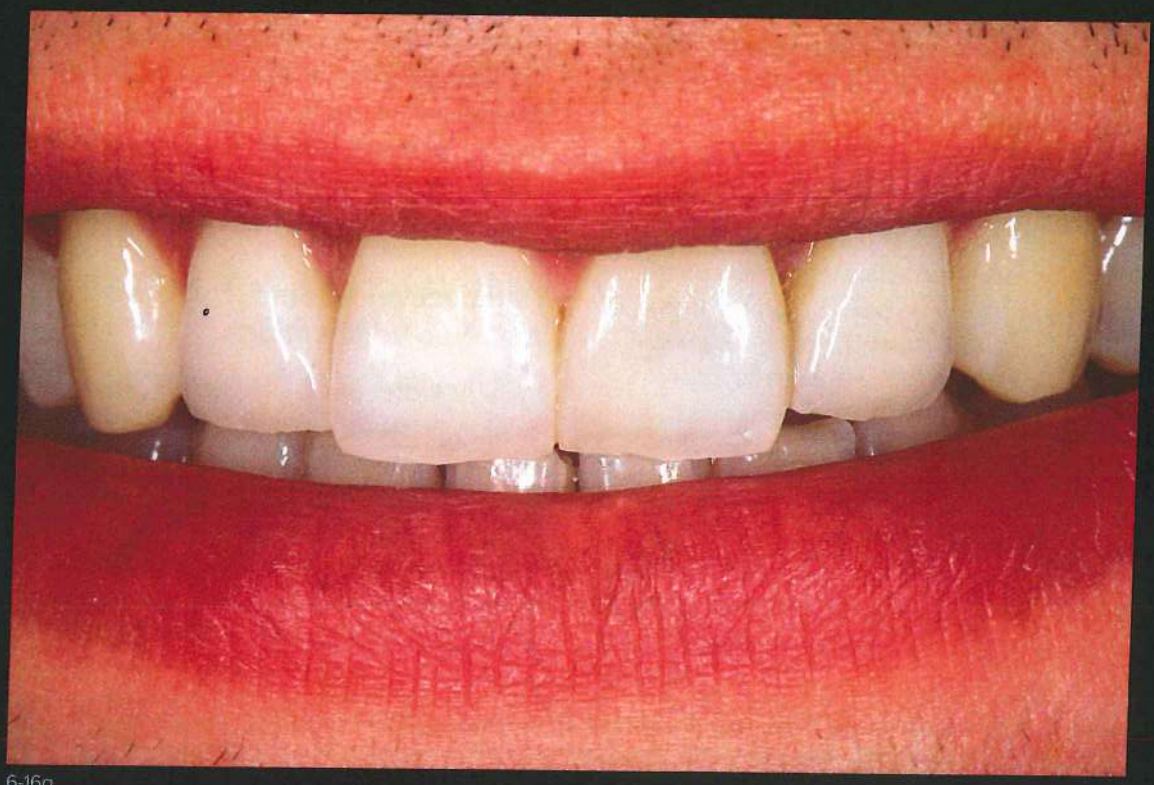

6-16g



t.me/Dr_Mouayyad_AlbtousH

## 6.6 TYPES IV AND V: FULL-COVERAGE CROWNS/ ENDOCROWNS

The so-called "porcelain jacket crown" was introduced to the dental profession more than 50 years before bonding to tooth structure (and especially to dentin) was available.[91] This metal-free porcelain was ideal in the anterior dentition but was only cemented and yielded favorable esthetic results at the cost of high failure rates. The obvious problem was the lack of cohesiveness between the brittle restorative material and the tooth. ***In the early 1990s, with the advent of efficient dentin bonding agents, the so-called "dentin-bonded crown" was proposed by Burke as the rebirth of the old jacket crown.***[92,93] The success of this apparently weak restoration is explained by the principle of strengthening of the restoration by the adhesive luting, similar to that of porcelain veneers.[93] Patient satisfaction was already very high,[94] ***when in the same decade, further optimization in the dentin bonding procedures was introduced in form of the IDS technique.***[29,95,96]

Like porcelain veneers, the particular ability of the feldspathic jacket crown to be etched and silanated produces such a reliable resin bonding that it makes it the perfect material for combination with the IDS technique. Hence its designation as type IV BPRs for full-crown coverage, most of which belong to group IVB for the replacement of existing PFM crowns.

Meticulous postetching cleaning techniques and heat-drying of the silane have further refined the resin-porcelain bond.[97–100] In addition, the concept of composite resin preheating[101] enabled the use of a regular, highly filled microhybrid material for thermomodified luting, further enhancing the robustness of this technique. Superior mechanical properties, better color stability, and facilitated delivery of the restoration are the major advantages of using a regular restorative material in lieu of resin cements or flowable composite resins. Section 6.13 provides all details and explanations related to adhesive delivery.

Figure 6-17 features a patient with existing PFM crowns and a significant umbrella effect on the gingiva (darkening of the tissues surrounding the restorations; see another example in Fig 6-19)[37] due to the metal substructure and dark underlying dentin. The walking bleach technique followed by the placement of adhesively retained core buildups and dentin-bonded porcelain jacket crowns were used successfully to address the existing problems.[102] The no-post therapeutic approach was chosen for maximum conservation of intact tooth substance. A new scientific rationale for no-post and even no-core approaches is explained in the next pages.

### Perspectives about ferrule, posts, and type V indications

***Type IV BPRs can be placed on either vital or nonvital teeth, which raises the question whether core buildups and intraradicular posts are needed as well as which materials should be used.*** The restoration of endodontically treated incisors (ETI) is a permanent challenge for the restorative dentist. The literature is unequivocal about the fact that the ferrule is

**FIG 6-17 Type IVB BPRs—The modern dentin-bonded jacket crowns.** *(a)* Preoperative view with opaque PFM restorations and dark surrounding tissues due to the umbrella effect. *(b)* The existing crowns were removed, as well as the radicular posts, in order to eliminate the discolorations by walking bleach technique. *(c)* A regular type II restoration was prepared on the left lateral incisor. *(d)* No posts were used for the reconstruction, just direct composite resin material to restore the geometry of the preparations. *(e)* An advanced alveolar model was used along with the refractory die technique to fabricate all four restorations.[103] A special layering technique using vertical slots for segmentation of the first bake was necessary to prevent porcelain shrinkage–induced cracks by decoupling (specific laboratory aspects related to the fabrication of those restorations are presented in Fig 6-71). *(f and g)* Final restorations (three type IV BPRs and one type IIA BPR on the left lateral incisor) before and after adhesive delivery. (Reproduced with permission from Magne et al.[102])



t.me/Dr_Mouayyad_AlbtousH



6-17a



6-17b



6-17c



6-17d



6-17e

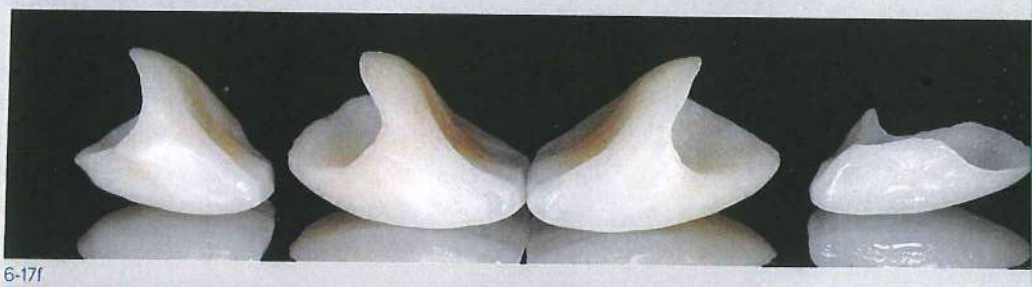

6-17f



6-17g



t.me/Dr_Mouayyad_AlbtousH

the dominating factor in the fracture resistance of ETIs.[104–106] Unfortunately, the operator is not always in control of the amount of remaining coronal structure. The absence of ferrule has generated a plethora of compensatory procedures, including surgical approaches, orthodontic extrusion, along with the use of various intraradicular posts and core buildup techniques. The use of fiber posts has become more popular instead of cast posts and cores[107,108] due to their esthetic and mechanical properties (elastic modulus similar to that of dentin) as well as decreased incidence of root fractures.[109] Other studies reported a lack of difference or even higher incidence of catastrophic failures for the fiber posts.[107,110–114] ***The lack of consensus on the use of intraradicular posts is further complicated by the fact that the real purpose of post placement is not to increase the resistance of the root but rather to provide mechanical retention for the core.*** In recent decades, mechanical retention has been progressively substituted by adhesion, and this trend logically undermined the use of posts when using IDS and adhesive crowns, even for ETIs.[106,115–117] Posts have already proven their lack of significance in posterior teeth without a ferrule and in anterior teeth with a ferrule.[106,118–120]

***New evidence is even suggesting that posts may not be necessary in severely damaged anterior teeth without a ferrule because they seriously increase the risk of catastrophic (nonrepairable) fractures.[115,116] When appropriate adhesive reinforced buildups (no post) or even endocrowns (no post, no core; see chapter 4, Fig 4-30) are used instead, the resistance to fracture is increased, and the risk of catastrophic failure is decreased (Fig 6-17h).[115,116,121]***

The type of buildup material can also influence the outcome, and new trends include regular restorative nanohybrids and bulk-fill materials such as short-fiber-reinforced composite resins. Traditional layering can lead to the incorporation of voids and interlayer gaps, resulting in less homogenous buildups. Bulk placement not only eliminates this potential problem but may even result in reduced shrinkage stresses while demonstrating similar mechanical performance with layered nanohybrids.[122–124] Short-fiber-reinforced materials have the potential to act as a load-bearing barrier under high occlusal forces to stop crack propagation through the restoration. The use of short-fiber-reinforced composites as a postless core buildup material to restore ETIs shows promising results,[116] but the most encouraging results have been obtained with CAD/CAM endocrowns, especially polymer-based ones (Fig 6-17h).[121]

In view of the above, and while waiting for confirmation with more clinical data, the endocrown can be considered the new prospective type V BPR indication for the restoration of compromised or severly broken-down endodontically treated anterior teeth with minimal or no ferrule effect.

**FIG 6-17h Type IV (crowns) and type V (endocrowns) bonded ceramic restorations on ETIs.** Accelerated fatigue of bonded lithium disilicate crowns until initial failure: Effect of various post and postless approaches.[106,115,116,121] *(A)* Fatigue testing of CAD/CAM IPS e.max crowns was carried out in a closed-loop electrodynamic system (Acumen III; MTS Systems) by simulating isometric contractions (5 Hz frequency load control 200 N to 1,000 N) applied to the incisal edge through a flat composite resin antagonist in submerged conditions. Twelve experimental groups with various buildups (*B* and *C*; G11 and G12 are CAD/CAM endocrowns): Light gray, fiber post; black, titanium post; Miris2, nanohybrid buildup; EvoC Bulk, bulk-fill buildup; ParaCore, dual-cure buildup; everX Post, bulk-fill short-fiber-reinforced buildup. *(D)* Detailed results express the number of load cycles until the opening of the palatal margin of the crowns *(see A, right)* usually preceding the complete fracture *(D, left;* statistical analysis with Kaplan Meier, Log Rank Post Hoc; bars with same letter are not different) and the percentages of catastrophic *(red)*, possibly reparable *(yellow)*, and reparable *(green)* fractures *(D, right)*. Ferrule groups yielded the best results, followed by no-post everX (G10) and no-post endocrowns (G11 and G12). Lava Ultimate (3M) endocrowns (G12) yielded the fewest catastrophic failures. See clinical example in chapter 4, Fig 4-30. (Images courtesy of Drs Marco Carvalho and Priscilla Lazari, Goiânia, Brazil.)



t.me/Dr_Mouayyad_AlbtousH

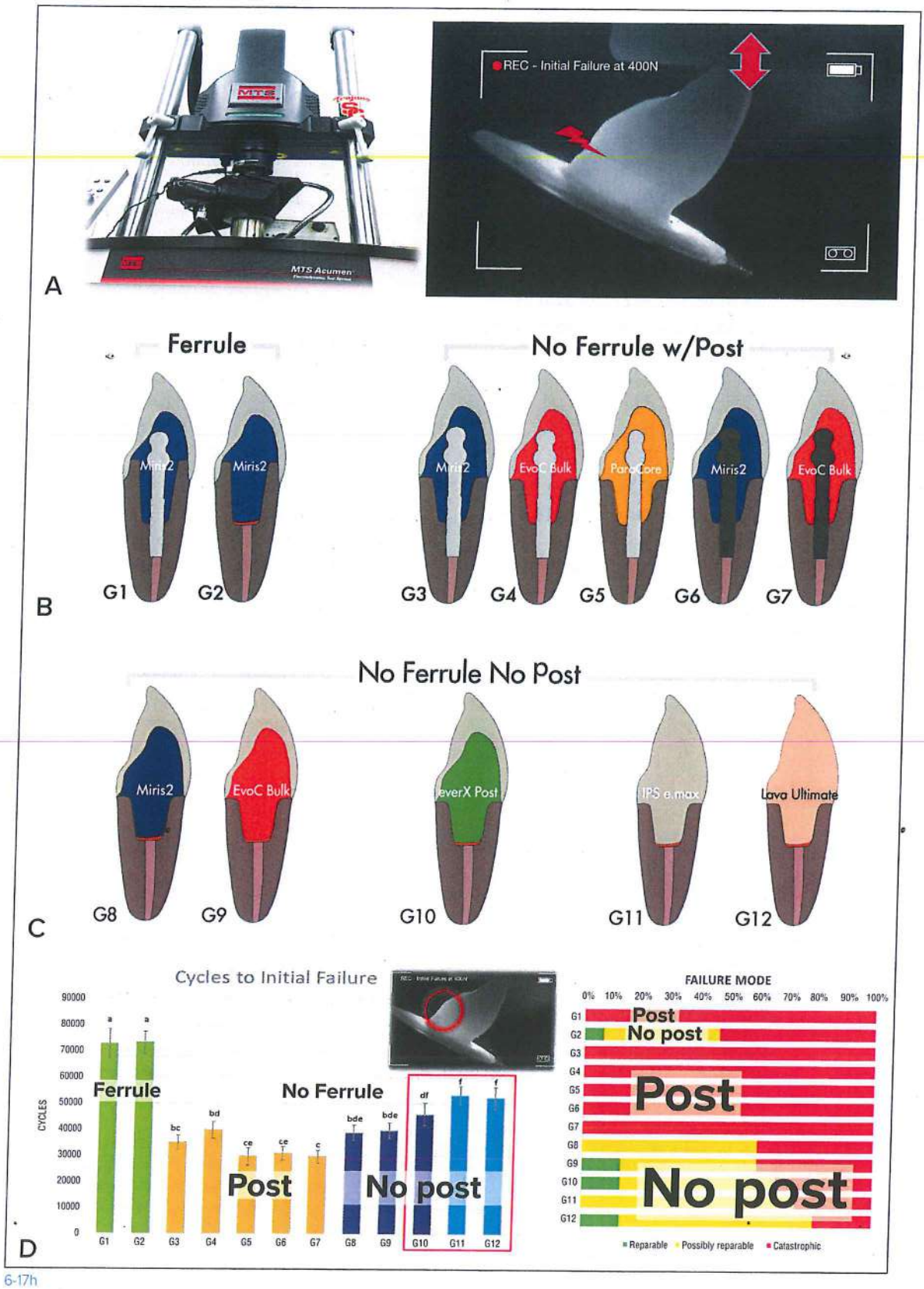


6-17h



t.me/Dr_Mouayyad_AlbtousH

# 6.7 BIOLOGIC CONSIDERATIONS

A comprehensive discussion of new indications for BPRs must include biologic considerations. ***For those patients showing type II and type III indications, traditional prosthetic treatment approaches (full crown coverage) would involve the removal of large amounts of sound tooth substance, with adverse effects on pulp, gingivae, and crown biomechanics, not to mention the financial consequences.*** The use of adhesive technology instead allows maximum preservation of tissues (including maintenance of tooth vitality) and limited costs, which also contributes to the satisfaction of the patient.

Another significant outcome is the excellent periodontal response of BPRs, which was first noted by Calamia in the late 1980s.[9] Due to their intrinsic favorable esthetics in the marginal area, bonded ceramic restorations do not require invading the gingival sulcus with the tooth preparation, which prevents potential damage to the periodontal tissues. Kourkouta et al[125] even demonstrated significant reductions in Plaque Index and plaque bacteria vitality after the placement of porcelain veneers. Such results call into question the general assumption that so-called "high-end" adhesive restorations are not indicated for patients with bad oral hygiene. ***In fact, owing to their "friendly" behavior and simple maintenance, BPRs might be the most forgiving restorations for patients struggling with oral hygiene*** (Fig 6-18a). One can anticipate that those patients' periodontium might respond better to ceramic materials considering that dental porcelain is less susceptible to accumulation of bacterial plaque in comparison to gold, resin, or even to mineralized tooth structures.[126–128] There is virtually no surface degradation of the ceramic material, which is corroborated by the absence of plaque accumulation (Fig 6-18b; see also the periodontal tissues around maxillary and mandibular type IIIA veneers after 19 years in Fig 6-12 and after 27 years in Fig 7-1).[24] An additional significant advantage of BPRs from the periodontal perspective is the avoidance of crown lengthening procedures because even very short clinical crowns can be recovered (see type IIIA).



**FIG 6-18 Follow-up views of periodontal soft tissues around BPRs after 5 to 6 years of clinical service without a specific maintenance protocol.** *(a)* Postoperative view 6 years after placement of a type IIA porcelain veneer on the lateral incisor showing a favorable periodontal situation despite poor oral hygiene; there has been a significant evolution of the cervical lesion on the natural unrestored canine. This case was detailed in Fig 6-5 (baseline view of the lateral incisor in Fig 6-5e). *(b)* Magnified view from another patient 5 years after the placement of this type IIIA BPR. The porcelain surface is still glossy, the margin is invisible, and there is no plaque accumulation despite the fact that no specific professional maintenance protocol has been carried out (the same can be said for the patient in *a*).



t.me/Dr_Mouayyad_AlbtousH

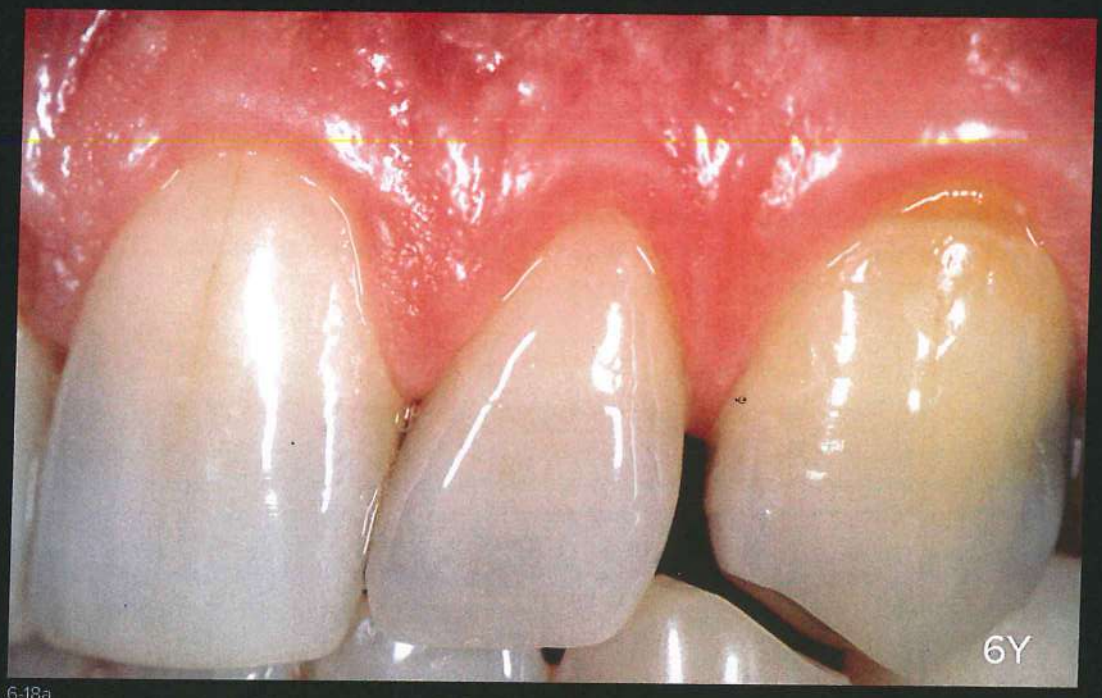


6-18a

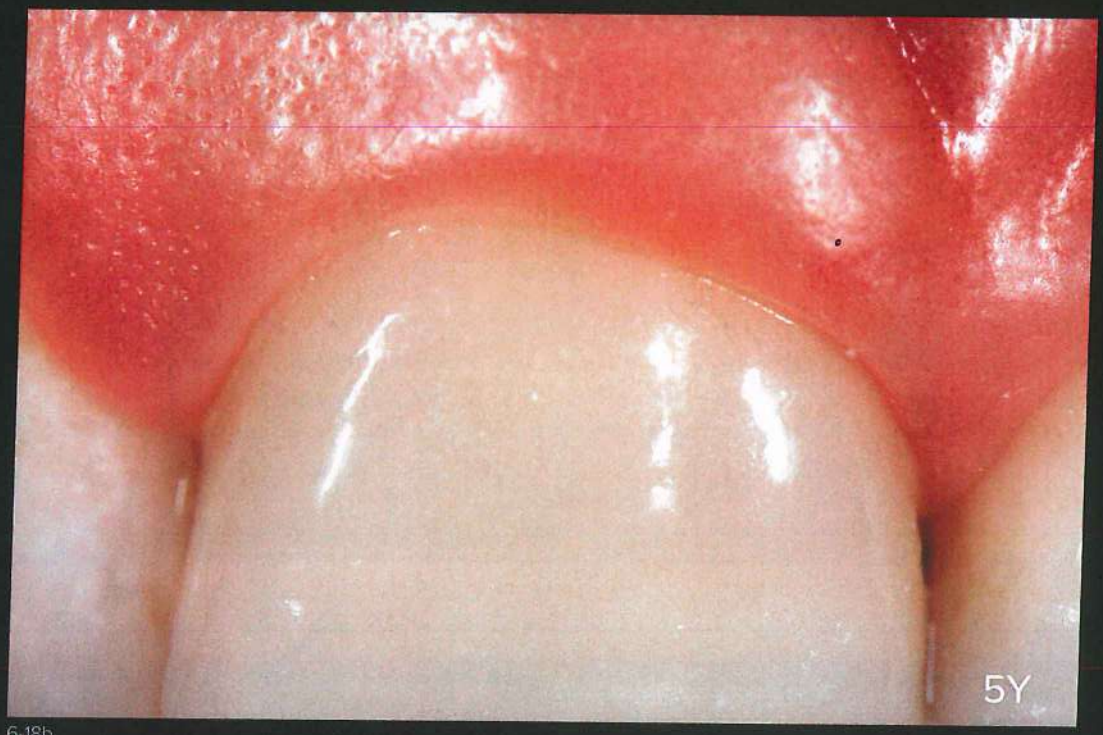


6-18b



t.me/Dr_Mouayyad_AlbtousH

## Umbrella effect

Finally, optimal esthetics of the marginal periodontium in the presence of BPRs is ensured through the so-called "esthetic width" inherent to these restorations (Fig 6-19).[37] With conventional full-coverage restorations, extended metal frameworks and opaque alumina/zirconia ceramic cores are associated with unpleasant optical effects in the surrounding soft tissues. This problem is increased by the presence of the upper lip: The proximity of the lip can generate an "umbrella effect" (or shadow) characterized by grayish marginal gingivae and dark interdental papillae (Figs 6-19b and 6-19d, top; see also Figs 6-15a and 6-17a). BPRs, on the other hand, exhibit an excellent optical behavior and promote a natural appearance of the marginal soft tissues (Figs 6-19c and 6-19d, bottom).



6-19a



6-19b

**FIG 6-19 "Esthetic width" and "umbrella effect" on the soft tissues.** *(a and b)* These maxillary restorations (full-coverage ceramic crowns from canine to canine) have an opaque core extending to the margins, blocking the light. As a result, grayish papillae are observed, especially in the presence of the lip. *(c)* In contrast, here the periodontal tissues around BPRs (right central incisor to left canine) appear healthy and naturally illuminated. Other aspects of this case are presented in Fig 5-4. *(d)* Diagram of the umbrella effect showing the lack of both direct and indirect light into the soft tissues when in the presence of an opaque core (right half) in comparison with a translucent core (left half).



t.me/Dr_Mouayyad_AlbtousH



6-19c

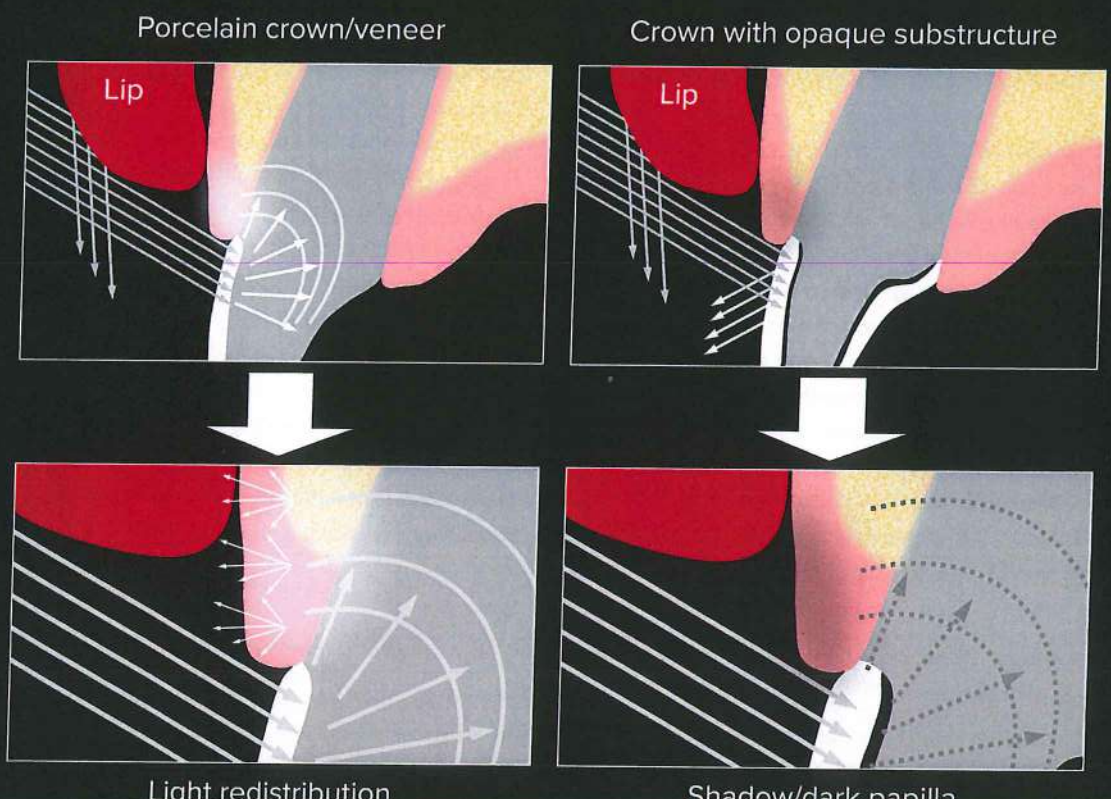


6-19d



t.me/Dr_Mouayyad_AlbtousH

# 6.8 PERSPECTIVES FOR OCCLUSAL VENEERS

Avoiding retentive features of tooth preparations is the best way to save tooth structure.[129,130] The usual occlusal thickness requirements for porcelain restorations vary between 1.5 and 2.0 mm (classic preparation).[131–134] New data suggest that more conservative approaches should be considered (0.4–0.6 mm at the developmental grooves and 1.0–1.3 mm at the cusp tips) in view of the development of stronger materials in combination with CAD/CAM techniques and innovative adhesive technology such as IDS.[29,96,134–136] The proposal for posterior "occlusal veneers" by Schlichting et al (ultrathin onlays/overlays with nonretentive design)[137–143] corresponds to the translational application of principles used in anterior porcelain laminate veneers. In this regard, thin posterior BPRs could potentially compete with gold onlays/overlays.

***In posterior teeth, thin occlusal restorations not only fulfill the principle of preservation of biology and tooth structure (the driving force of restorative dentistry) but also provide a supragingival approach facilitating maintenance and follow-ups of restorations,[144] as well as enhanced esthetics due to their improved blending ability (chameleon effect) compared to full-coverage crowns.***

Because the preparation is only driven by interocclusal clearance, usually obtained by opening the bite, and anatomical considerations (eg, depths of grooves; Fig 6-20), occlusal veneers are simpler and more intuitive than other preparation techniques. A significant increase in pulpal complications is associated with preparations with deep shoulders and chamfers, as was required for full-coverage crowns in the 1970s and 1980s.[129,145–147] Full-coverage crowns (PFM technique) are also linked with more gingival inflammation and secondary caries when compared to bonded restorations.[148] As Edelhoff and Sorensen remind us, ***PFM complete crowns require the removal of more than twice the amount of tooth structure compared to partial preparations with reduced macroretentive geometry, like onlays and partial ceramic crowns.***[129]

As a result of the expanded range of indications for thin restorations, occlusal veneers are now commonly used in the treatment of simple (single restorations) to advanced cases (quadrants, full mouth) of biocorrosion[140,141,149–152] (see chapter 5, Fig 5-21), stabilization of teeth with cracked tooth syndrome,[153,154] and endodontically treated teeth that have been reduced out of the occlusion by the endodontist to prevent fracture.

Beyond the occlusal veneer designs presented in Fig 6-20a, a multitude of other preparation designs are possible (overlays, "veneerlays," and "crownlays" as seen in chapter 4, Figs 4-12 and 4-20b) depending on the severity of the case and necessity to include the buccal surface of the tooth.

**FIG 6-20 Translational application of porcelain veneers from anterior to posterior teeth.** Experiments by Schlichting et al[137,138] demonstrated the extreme load-bearing capacity of occlusal veneers. Occlusal clearance can be obtained conservatively by careful treatment planning. *(a)* In the presence of biocorrosion and wear *(left)*, opening of the bite will naturally provide clearance at the level of the cusp tips *(green double arrows, right)*. Three approaches are then possible depending on multiple factors related to the case: *(b)* no-prep direct restorations (localized biocorrosion, simple occlusion); *(c)* minimally invasive approach (generalized cases treated with semi-direct CAD/CAM or pressed occlusal veneers); and *(d)* classic approach (when planning classic indirect layered porcelain restorations). *(e)* The minimally invasive approach is often preferred because the intact occlusal enamel and dentinoenamel junction can be preserved *(blue arrows)*, but the developmental grooves in the restoration should be more shallow than the natural morphology. *(f)* The classic approach relates to the use of weaker materials, such as feldspathic porcelain; it requires more occlusal reduction, resulting in more dentin exposure, and requires the use of IDS. A common challenge is the omission of clearance at the central groove area, including space for IDS *(red surface in b*; special caution is required because the adhesive will slightly accumulate at the bottom of the developmental grooves and reduce the restorative space).



t.me/Dr_Mouayyad_AlbtousH

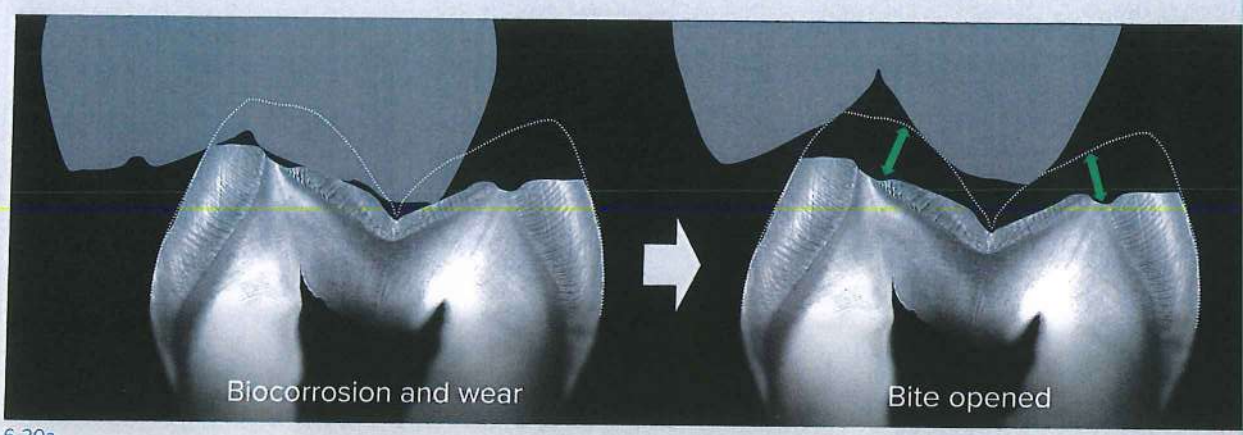


6-20a

No-prep direct restorations

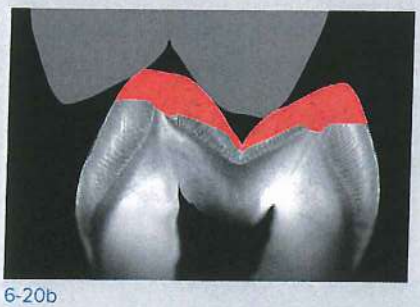

6-20b

Minimally invasive preparation

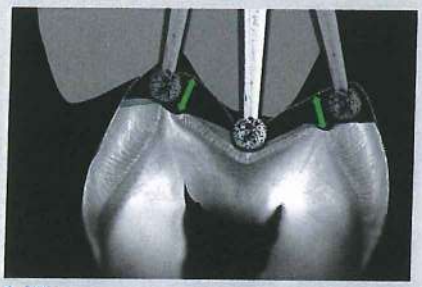

6-20c

Classic preparation

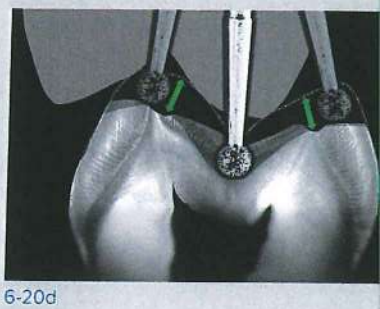

6-20d

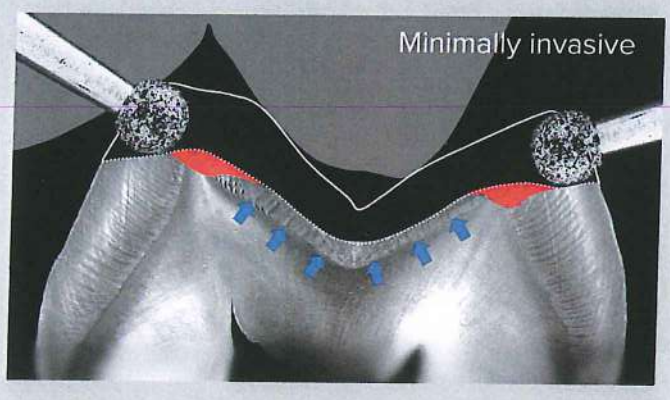


6-20e

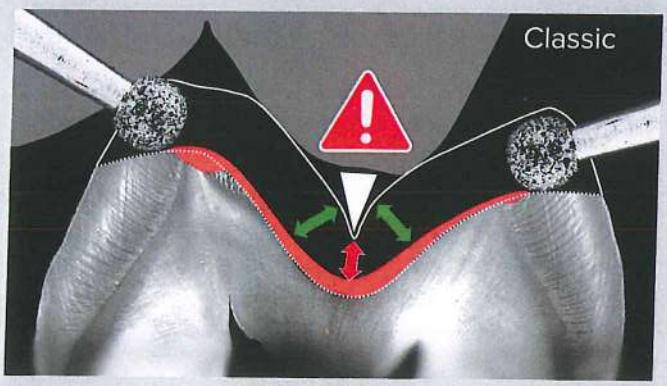


6-20f



t.me/Dr_Mouayyad_AlbtousH



6-20g



6-20h

**FIG 6-20** *(cont) (g to j)* Minimally invasive occlusal veneers. These cases are examples of early and minimally invasive treatment of biocorrosion, which were restored with thin-pressed lithium disilicate glass-ceramic restorations (dental technician August Bruguera, CDT, Barcelona, Spain) or CAD/CAM semi-(in)direct ultrathin occlusal veneers. (Parts *g* and *h* courtesy of Dr Francesca Vailati, Geneva, Switzerland, and reproduced with permission from Vailati et al[155]; clinical case and photography for parts *i* and *j* courtesy of Dr Luis Henrique Schlichting, Florianópolis, Brazil.)


t.me/Dr_Mouayyad_AlbtousH

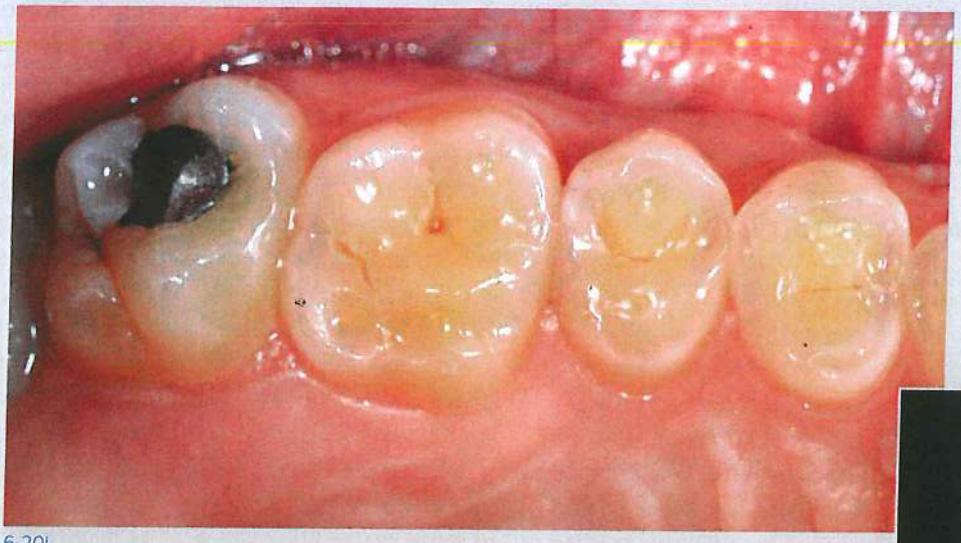

6-20i

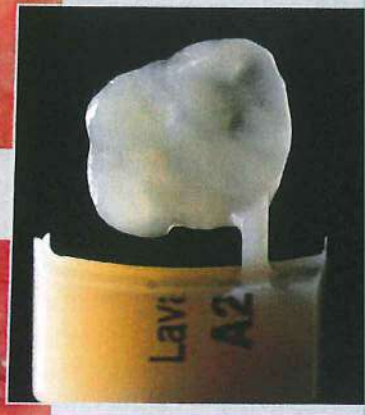


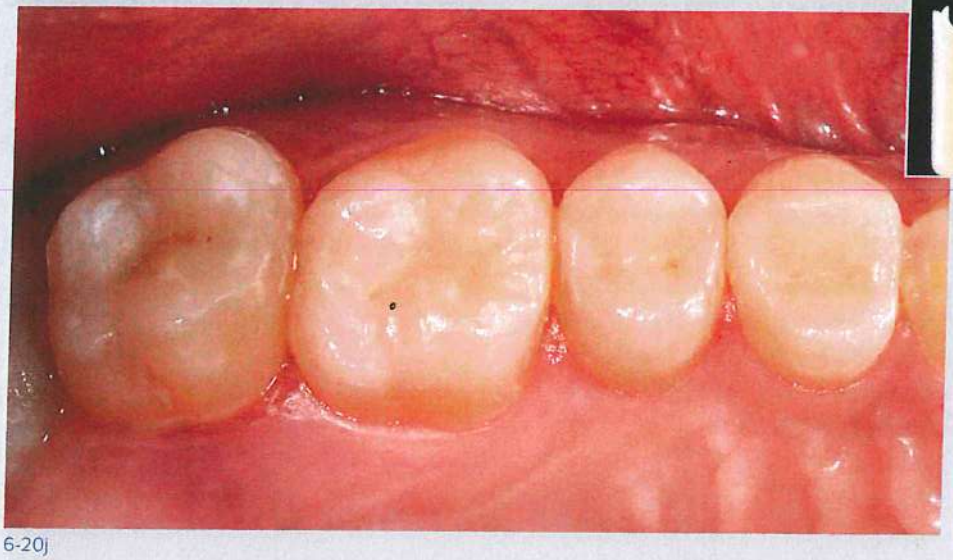

6-20j



t.me/Dr_Mouayyad_AlbtousH

# 6.9 TOOTH PREPARATION PRINCIPLES

## General considerations

***When the appropriate diagnostic steps described in chapter 5 (wax-up, mock-up) have been strictly applied, practical restorative procedures can begin with maximum confidence and predictability.***

The final objective being accurately defined, tested, and approved by the patient, the active therapeutic effort can now focus on the technical procedures regarding tooth preparation. The focus of the preparation design for BPRs should be the balance between optimal marginal adaptation of the final restoration and an utmost respect of the hard tissue morphology. As is the case for all adhesive restorations, BPRs must be completely differentiated from traditional cemented crown coverage, especially regarding retention and resistance form. The adhesive properties and physicochemical characteristics of the luting composites allow the tooth-restoration interface to be subjected to substantial stresses. From this viewpoint, the geometric and mechanical parameters of the tooth preparation are of only secondary importance. ***This leads to a maximal preservation of remaining sound mineralized tissue during the tooth preparation procedure and, consequently, to a very conservative approach (Fig 6-21).***

A minimum amount of preparation geometry, however, is still required in order to facilitate insertion and positioning of the ceramic workpiece during the final bonding procedure. Ensuring the long-term integrity of the tooth-restoration complex also implies the need for a sufficient and homogeneous ceramic thickness providing the restoration with the required intrinsic mechanical resistance to sustain fabrication and delivery procedures. Finally, well-defined preparation margins will allow for an accurate fit, soft emergence profile, as well as optimal maintenance of the future restorations.

***When dentin has been exposed, immediate dentin sealing (IDS) will always be the last step of tooth preparation procedures before final impressions.*** In anterior BPRs, the IDS layer often competes with the space for the porcelain and therefore requires particular attention.

This section systematically reviews tissue reduction, margin configuration and localization, and fundamental aspects related to wrapping and incisal overlapping and will address particular situations such as thin vs thick teeth, preexisting restorations, and diastemata, among others.

**FIG 6-21 Type IIIA BPRs following 10 years of successful clinical service.** *(a)* Initial view of previously crown-fractured incisors. *(b and c)* Only a pellicle of enamel was removed. Periodontal surgery (ie, crown lengthening) was not required despite severe loss of hard tissue and very short clinical crowns. *(d to f)* Detailed views of master model. *(g to i)* Corresponding ceramic restorations fabricated with a combination of feldspathic porcelain, hydrothermal low-fusing glass, and a refractory die technique. The incisal edge extends more than 5 mm on the left central incisor. There is very little primary stability of the restorations; the long-term success essentially relies on adhesion. *(j to l)* Clinical results more than 5 years after placement and at the 10-year follow-up. The acid-etch technique was used along with an enamel adhesive and a light-polymerizing restorative composite (microhybrid) as a luting agent. The restorations were bonded only to enamel because no efficient dentin adhesives were available at the time of placement. The restorations are supporting significant protrusive guidance. The 10-year follow-up *(l)* reveals a favorable soft tissue response. The restorations show excellent marginal adaptation and seal, color stability and smooth surfaces, as well as absence of recurrent caries or ceramic cracks. (Parts *a* and *c* reproduced with permission from Magne et al.[62])



t.me/Dr_Mouayyad_AlbtousH



6-21a



6-21b



6-21c

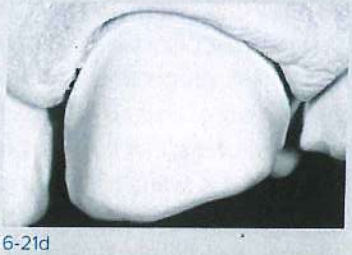

6-21d



6-21e

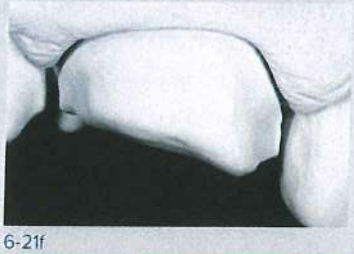

6-21f



6-21g

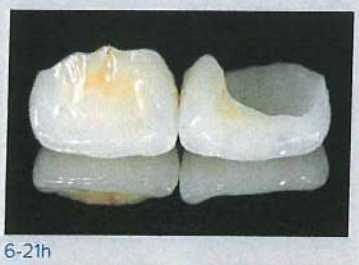

6-21h



6-21i




6-21j




6-21k




6-21l



t.me/Dr_Mouayyad_AlbtousH

## Historical pendulum of preparation concepts

### From "no-prep" to "over-prep"

Serious trends for oversimplification of anterior BPRs have reemerged in the last decade in the form of "no-prep" approaches.[156–161] The noninvasive preparation was already popular in the 1980s. During the 1990s and 2000s, more aggressive preparations for ceramic restorations were promoted as the result of overly simplified but greedy laboratory methods (original pressable ceramics).[162] Veneer preparations began looking like ¾-crown preparations. In some "impatient" patients looking at porcelain veneers as a substitute to orthodontic treatment (the so-called "instant-ortho" cases), even more aggressive preparations were used as a compensation for inadequate tooth position. Deep preparations (chamfers/shoulders) led to the loss of the "contact lens effect" (or chameleon effect) with margins that became more visible, like those of a crown preparation. The necessity to hide this transition with subgingival margins in turn conflicted with periodontal health and long-term maintenance.

### From "over-prep" to "no-prep"

An oversimplified preparation method therefore reappeared as a radical response to the 1990s–2000s preparation euphoria, which was also enabled by technologic advances to produce much thinner pressable ceramic veneers. Presented as a much simpler alternative to traditionally prepped veneers, no-prep veneers may at first appear extremely attractive to both the patient and the dentist. From the laboratory perspective, fabrication, handling, and finishing of those ultrathin restorations is not without challenges, mostly the difficulty in avoiding bulky margins and overhangs (Fig 6-22). Margins need first to be layered thicker than normal and then trimmed carefully under microscope in the laboratory or after delivery, once bonded to the tooth (Fig 6-22b). These procedures are very technique-sensitive but are required to provide a natural emergence profile rather than making the restoration look like it is sitting on the tooth. Chipped or jagged margins are common in the absence of a defined finish line (Fig 6-22d). This has to be corrected with the addition of luting composite or further finishing with a bur after bonding. The surface quality of laboratory-finished margins, however, can never be recovered by intraoral polishing. The long-term esthetic outcome and maintenance of such restorations must be questioned (Fig 6-22d).[163] Specific cases require the involvement of the interdental surface (diastemata, black triangles); due to the retentive contours of the tooth, the no-prep approach will not allow fitting the veneer at the mesiolingual and distolingual margins.

Another drawback is that flowable composite resins must be used to deliver these thin porcelain shells and avoid flexural forces during seating. Composite resin flow, however, is obtained at the cost of increased polymerization shrinkage and decreased elastic modulus, wear resistance, and strength.

**FIG 6-22 Clinical challenges of no-prep veneers and fragments.** *(a)* Ceramic fragment just after delivery on the left central incisor; note the step at the interface between the ceramic and the tooth. *(b)* An ultrafine-grain diamond bur was used to thin the ceramic and remove that step; note the rough and scratched interface and exposure of a thick cement line. *(c)* Same tooth after polishing of the interface; note the thick exposed cement line. *(d)* Interface of ceramic fragment after 4 years of clinical service; note areas with staining near the gingiva, demonstrating that it was difficult to obtain a proper polishing. (Images courtesy of Dr Victor Clavijo; reproduced with permission from Kabbach and Clavijo.[163])



t.me/Dr_Mouayyad_AlbtousH

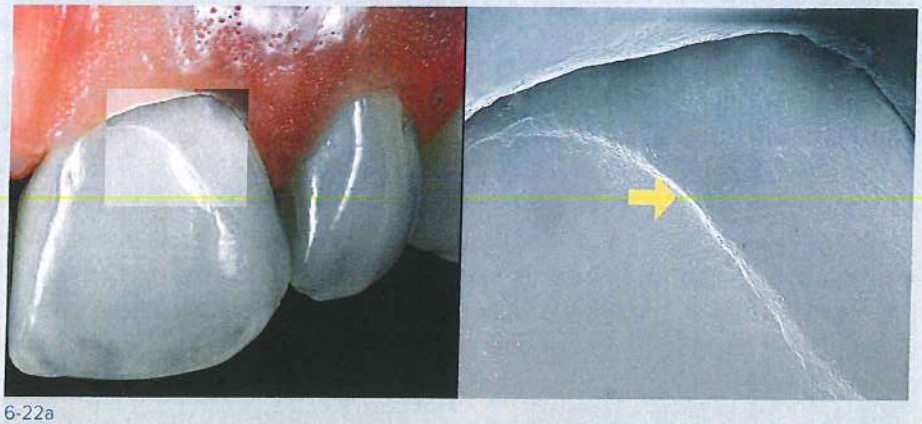

6-22a

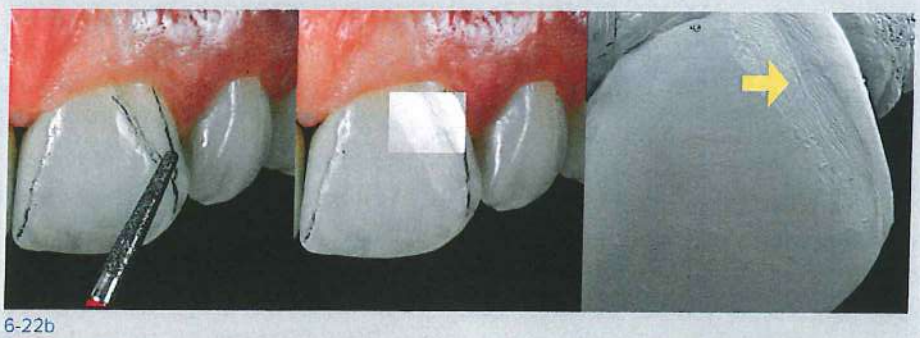

6-22b

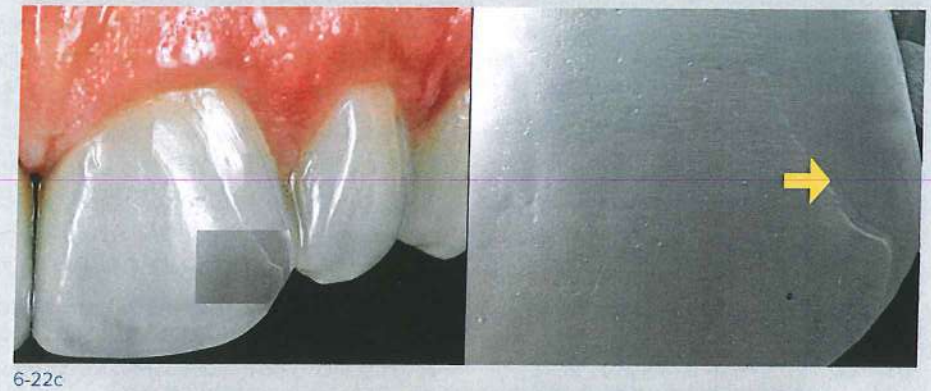

6-22c



6-22d



t.me/Dr_Mouayyad_AlbtousH

No-prep veneers are usually difficult to seat because they lack primary positional stability on the tooth due to their contact lens shape. Finally, a potential risk of the no-prep approach is that clinicians are tempted to plan the restorations as a symmetric package (6- or 10-pack) in order to keep the morphologic and marginal defects balanced/symmetric. Spending the time and effort in those delicate procedures to obtain appropriate fit and contours is not possible or realistic for everyone.

> It appears that the no-prep approach, which was supposed to be simpler and more efficient, is in fact more complicated and technique sensitive than other methods. Not to mention the fact that no-prep cases are often treatable with direct composite resin restorations using the guided natural layering technique (see chapter 3, Fig 3-48).

## The moderate preparation

The aforementioned concepts may confuse the clinician and even generate a certain amount of guilt for not being able to adapt to changing trends. Measuring the success of clinical dentistry as a function of the amount of treatment sold to the patient has generated "seduction marketing campaigns" (eg, to address anesthesia phobia). This goes against what is given by knowledge, wisdom, and experience, which is a careful customized recipe leading to the right treatment, not profit-based but one that respects the principles of enamel preservation while delivering what was pledged to the patient through the appropriate diagnostic approach, wax-up/mock-up, and informed consent.

***Hence, the golden standard for ultimate esthetic results and tissue conservation is the so-called "moderate approach." It consists in the selective reduction of tooth substance guided by the mock-up, itself mimicking the golden reference, the wax-up.***[52,53,56]

Coronal integrity and stability will be only marginally affected by moderate guided preparations. In most cases, the cementoenamel junction is preserved by the additive volume given by the wax-up.[21,24] Shallow chamfers of 0.3- to 0.4-mm depth will provide a stable margin while still generating a good chameleon effect and supragingival margins that are totally invisible. As a result, periodontal health is not jeopardized and long-term maintenance is simplified. Fabrication and handling of those restorations is far easier than no-prep veneers. Fitting and finishing the margins is possible while obtaining a natural emergence profile, optimal relationship with the soft tissues, and good porcelain support; hence, the risk of chipping during fabrication, handling, and delivery is significantly reduced compared to the no-prep approach. The excellent primary stability and marginal fit of the restoration significantly facilitates seating and positioning on the tooth.

Preheated regular restorative composite resins can be used as luting agent (decreased shrinkage and increased elastic modulus, wear resistance, and strength compared to flowable composite resins). Composite resin excesses and flashes can be removed manually, with a sickle scaler or a #12 scalpel blade (no grinding) because of the optimal marginal contour and fit. ***The systematic use of a frontal (horizontal) insertion path (see Fig 6-26a) constitutes a key element in this moderate approach to tooth preparation.[20] Because it respects the natural interdental divergence toward the incisal edge, this specific preparation design is particularly conservative while simultaneously allowing significant wrapping of the same interdental surfaces (required for managing interdental triangles or diastemata).*** Finally, moderate preparations benefit from a significant amount of data about follow-up and maintenance.



t.me/Dr_Mouayyad_AlbtousH

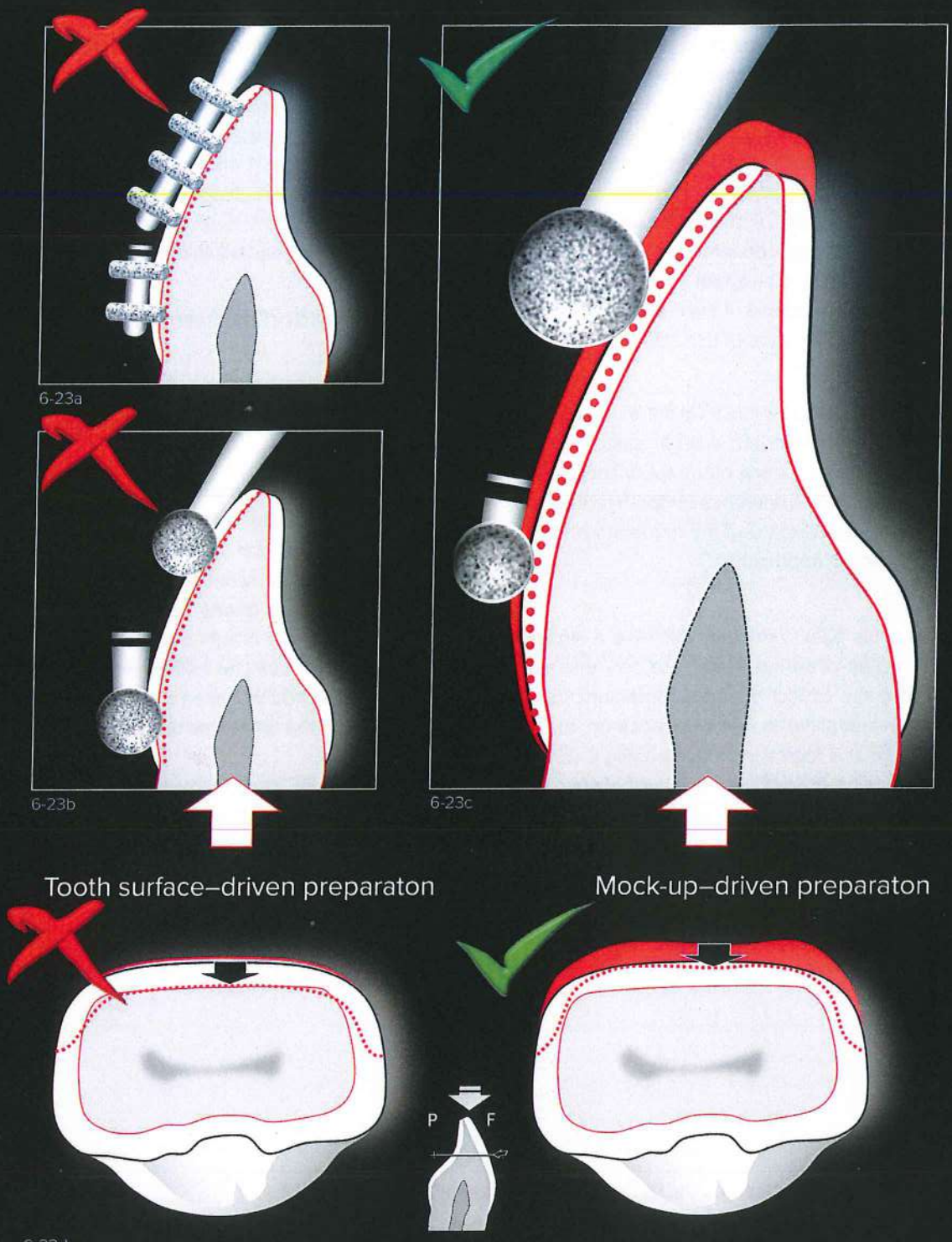


**FIG 6-23 Burs and mock-up for initial facial reduction: Schematic sagittal and horizontal cross sections of a central incisor.** *(a)* Calibration burs with diamond rings are not recommended because they cut according to preexisting tooth surface and volume. An excessive amount of enamel is reduced *(red dotted line)* with an augmented risk for dentin exposure. *(b)* Round diamond burs can be used the same way to calibrate the reduction. *(c)* However, they should be used over the mock-up (augmented volume, *surface in red*), and a smaller-diameter bur must be selected for the cervical reduction. In this way, the dentinoenamel junction *(red line)* and a significant amount of enamel can be preserved. *(d)* Horizontal cross-sectional schemes.



t.me/Dr_Mouayyad_AlbtousH

Early tooth preparation techniques for BPRs did not promote optimal preservation of enamel. Reduction burs with calibrated diamond rings or round burs were used to cut enamel, and depth cuts were based on the preexisting tooth surface (Figs 6-23a and 6-23b). When the initial enamel was already thin, reduction based on such depth cuts led to major dentin exposures. As explained in chapter 5, the veneer should aim to restore the original volume of the tooth (see Fig 5-5),[21,62] especially in cases of thin initial enamel.

> Therefore, a mock-up (intraoral replica of the diagnostic wax-up) restituting the original volume of the tooth should be used as a reference for tooth reduction (Fig 6-23c) using the moderate preparation approach.

This basic principle will save a significant amount of sound tissue, not only enamel but also the critical dentinoenamel junction. The more additive the wax-up/mock-up, the more enamel is logically preserved (Fig 6-23d). The mock-up (test-drive stage) will always reveal the maximum extent of additive volume that is acceptable to the patient. This is one of the reasons why the mock-up must be bonded and used for a certain amount of time; usually, the more time this mock-up is worn (2–3 weeks), the more the patient is deprogrammed from the previous design and will accept the new additive volume. The simplest and most important tool to check enamel reduction is represented by a well-adapted horizontally sectioned silicon index from the wax-up (Figs 6-24a to 6-24c).

## Recommended sequential procedure

The recommended preparation procedure is shown step by step in Figs 6-24 and 6-25.

***If the mock-up was approved in its original form and no intraoral editing was needed (no adjustments in shape and length), the same silicon indexes that were used for the mock-up can be used again during tooth preparation. However, when the mock-up was significantly adjusted in the mouth, new silicon indexes must be obtained, intraorally or on a new cast of the dentition with the edited mock-up.***

At least three silicon indexes are required (Fig 6-24a): two for checking the preparation depth and one for fabricating the provisional restoration.

**FIG 6-24 Preparatory stage for tooth preparation procedures.** *(a)* Two silicon indexes will be used for evaluating the preparation clearance *(top and bottom)*. The first one involves mainly the labial surface of the wax-up *(b)* and is used to evaluate labial clearance *(c;* note the significant space already available when placed on the model with intact teeth). This index must seat precisely on the occlusal surfaces of posterior teeth *(* in b and c)* or else the space will not be properly assessed. The second one is used to monitor the incisal clearance and is seated on the intact lingual surfaces *(d)*. The third index *(a, middle)* will be used for the fabrication of the provisional restorations with the exact same technique that was used for the mock-up. An alternate technique to that illustrated in chapter 5 to fabricate the mock-up is to anatomically cut the silicon putty to fit the scalloped contour of the gingiva, which facilitates removal of excess resin before the PMMA is completely set *(e and f, next page)*. A Shore-A hardness of 70–80 is recommended for the silicon putty material.



t.me/Dr_Mouayyad_AlbtousH

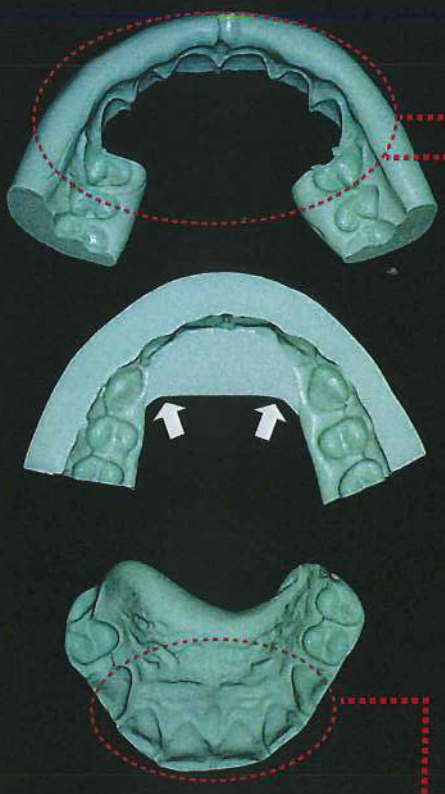

6-24a

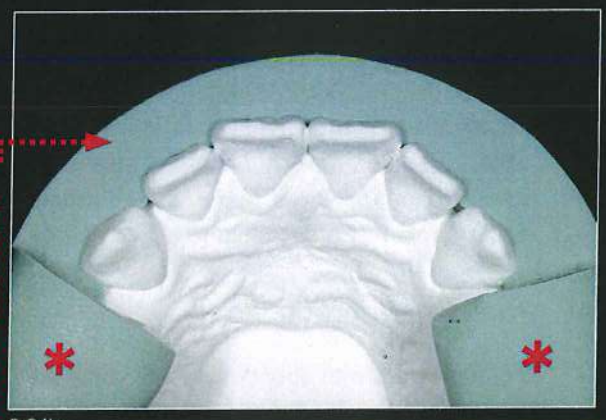

6-24b

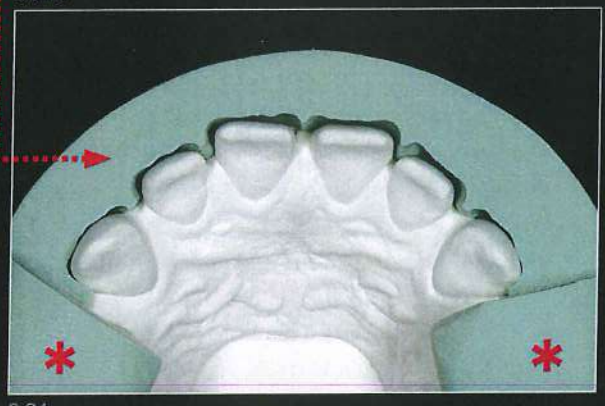

6-24c

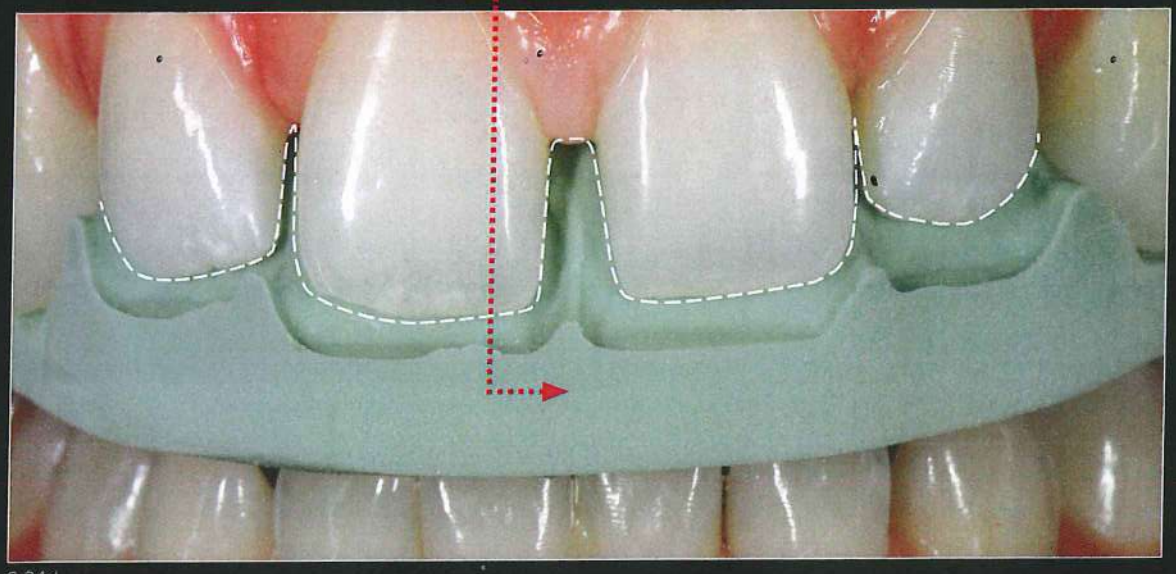

6-24d



t.me/Dr_Mouayyad_AlbtousH

An accurate mock-up (tested and approved by the patient) should always be the starting point of tooth preparation procedures. Proper hygiene during the mock-up stage (Fig 6-25a) will ensure that the periodontium stays healthy and will prevent bleeding during the next procedures. A bur kit developed with Brasseler (KIT ref K0082; Fig 6-25b) includes most of the instruments needed for anterior and posterior tooth preparation. ***There are two phases in tooth preparation: wet reduction and dry finishing.***

## Phase 1: Wet reduction

Diamond burs with abundant water spray are used as illustrated in Figs 6-23c and 6-25c for a calibrated reduction of the tooth surface. There are three steps to follow:

### 1. Axial reduction I: Depth cuts

Coarse round diamond burs are used to create facial reduction grooves with specific depth. The larger bur (eg, 801-023) is used at the junction between the incisal and middle third of the labial surface with the shank parallel to the tooth surface (Fig 6-25c). This horizontal groove is straight from mesial to distal, and the penetration of the burs should be limited by the mock-up (Fig 6-25d) to a depth of approximately 0.6 mm for refractory die–generated porcelain veneers. The second groove is shallower—about 0.4 mm—with bur 801-018 and is made at the junction between the middle third and cervical third of the labial surface. It is also mesiodistal, but it is scalloped to follow the gingival contour.

> It is critical to choose the right instruments according to the need for specific ceramic thicknesses. Some manufacturing techniques may require more space than others (especially when masking is required), and the laboratory technician/ceramist or CAD/CAM technician in charge must clearly indicate these requirements, knowing that reductions deeper that 0.4 mm near the gingiva may result in exposed dentin.

***The depth of cut (C in Fig 6-25c) can be easily changed by selecting other burs and measuring the diameter of the bur (d1), subtracting the diameter of the shank (d2), and dividing it by 2.***

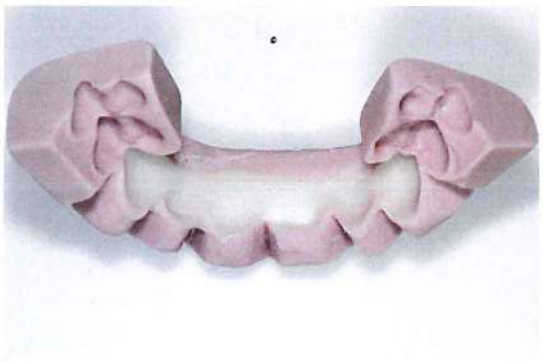

6-24e

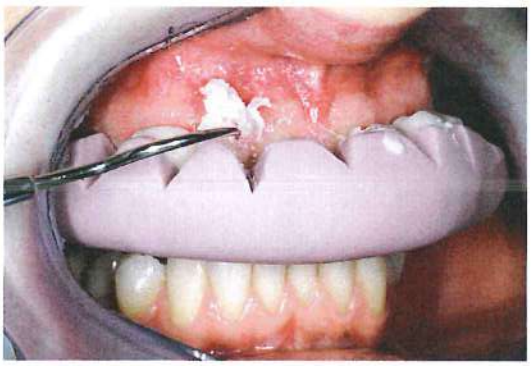

6-24f

**FIG 6-25 Step-by-step tooth preparation procedures.** *(a)* Tooth preparation always starts with a clean and approved mock-up (hygiene with Superfloss by Oral-B to reach gingival embrasure). *(b and c)* Using appropriate instruments (eg, coarse round diamonds such as 801-023 and 801-018), continuous horizontal depth cuts are obtained. The bur shank is maintained parallel to the mock-up surface to limit the bur penetration *(arrows in c)*. The depth of cut is obtained by a simple equation *(c, bottom right)*. When the mock-up is well additive, most of the preexisting tooth surface will be untouched and the reduction will be limited to the depth of the acrylic material.



t.me/Dr_Mouayyad_AlbtousH

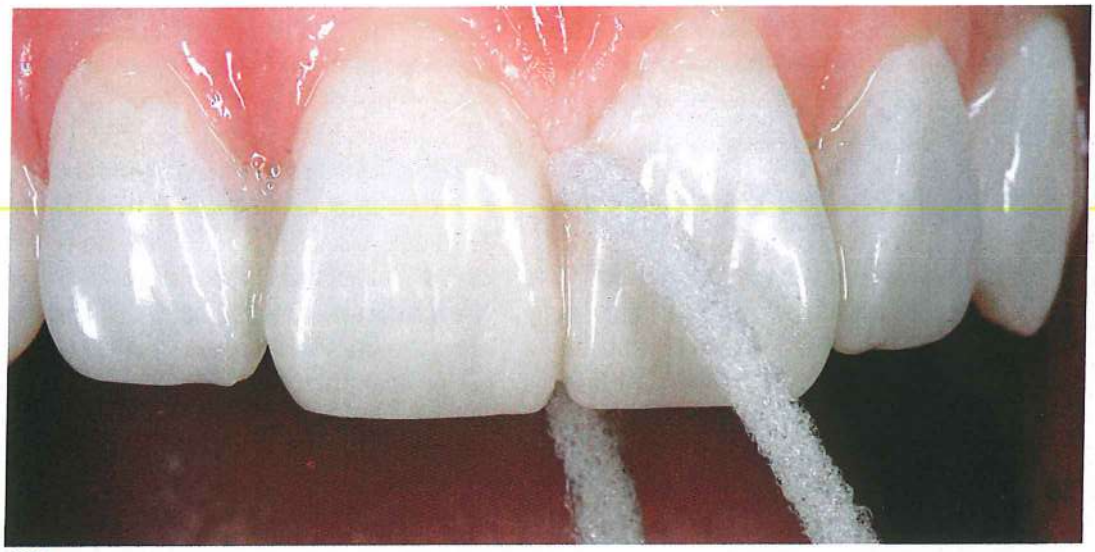

6-25a




6-25b



BIOMIMETIC RESTORATIVE DENTISTRY
by Brasseler, Bur Kit Ref K0082




6-25c



t.me/Dr_Mouayyad_AlbtousH

Depth cuts should be marked with a pencil (Figs 6-25e to 6-25h) and the remaining parts of the mock-up possibly removed with a scaler (optional; Fig 6-25h).

### 2. Axial reduction II: Main labial reduction

The main axial reduction necessitates the use of three different diameters of tapered round-ended burs classically designed for traditional fixed prosthodontics: eg, 850-023, 850-016, and 850-014 (Brasseler). The larger bur is used first to flatten the tooth surface until the pencil marks are erased (Figs 6-25i to 6-25j). When interdental spaces are accessible, such as in the case of Fig 6-25 (diastemata), the same bur or a slightly smaller one (850-016) can be used to wrap the interdental surface. Larger burs should be preferred because they tend to generate smoother surfaces. A uniform space of 0.6 mm should be predictably generated by this method (Fig 6-25k), ultimately producing the same thickness of ceramic at the proximal and axial levels. The smallest-diameter bur (850-014) and oscillating tips are used mainly to partially involve the interdental surface in the presence of large contact surfaces (additional details about interdental wrapping and finishing are given in Figs 6-27 and 6-30).



6-25d

**FIG 6-25** *(cont) (d)* Note the precise position of the bur during depth cuts. Slight variations in bur angulation *(dotted bur)* can produce inaccurate depths of cut. Pencil marks at the deepest area of the grooves are critical in this technique *(e to h)* because their elimination with the other burs will indicate that sufficient reduction has been obtained *(i and j)*. The key element in this method is that the reduction bur (eg, 850-023) is approximately at a 90-degree angle compared to the direction of the depth cuts *(arrows in j)*. Axial reduction is smoother when larger burs are used. Note the healthy aspect of the gingiva because of the good oral hygiene with the Superfloss underneath the previous mock-up. *(k)* The control of axial reduction reveals a uniform space. *(l)* The incisal edge clearance is controlled with the palatal index. (Parts *e* and *f* reproduced from Magne and Belser[52] with permission.)



t.me/Dr_Mouayyad_AlbtousH



6-25e



6-25f

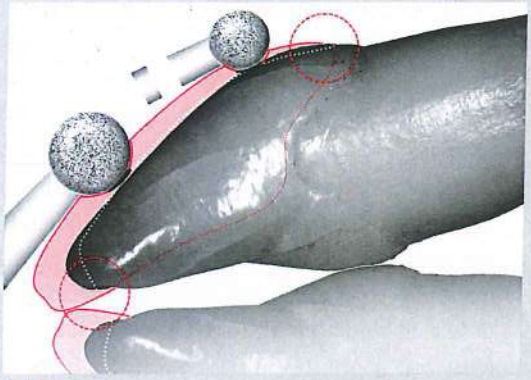

6-25g

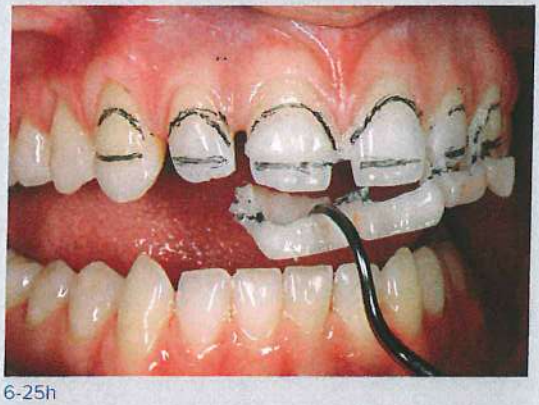

6-25h



6-25i



6-25j



6-25k



6-25l



t.me/Dr_Mouayyad_AlbtousH

### 3. Incisal reduction

The palatal silicon index is used to check the incisal clearance (Figs 6-25l and 6-25m). A range of 1.0 to 1.5 mm is required depending on the incisal edge thickness (additional details regarding incisal and palatal preparation are given in Figs 6-32 to 6-41).

### Cross-polarized photographs of preparations with shade tabs

While the preparations are still wet, it is fundamental to record possible discolorations (white or saturated spots, colored banding, etc) or translucent areas on the prepared teeth. The intensity of irregularities in color and opacity need to be communicated to the ceramist in order to facilitate the application of specific intrinsic masking to the thin restorations. As part of the eLAB protocol for veneers, cross-polarized images including the gray card will allow the fabrication of tooth-colored wax or acrylic dies for the virtual try-in (see Fig 5-37b).

> Intrinsic masking by the porcelain, when done properly using the parallel stratification technique,[164] is the best approach and yields more predictable results rather than using opaque luting agents (see Fig 6-70). A cross-polarized photograph of the hydrated preparations is the most valuable tool for the ceramist to achieve this goal.

## Phase 2: Dry finishing

At this stage, low-speed and fine diamonds and flexible discs can be used with air-cooling only for better visibility in order to obtain smooth surfaces and well-defined margins (see Fig 6-28).

### 1. Placement of a deflection cord

This step is optional, and ***choosing to mechanically deflect the gingiva can be motivated by different factors, such as the miniwing concept.*** To be applied properly, this concept requires the placement of intrasulcular margins at the interdental aspect of the tooth. In any case, slightly deflecting the gingiva is not always aimed at producing an intrasulcular margin but improving visibility during the preparation of the equigingival margin. A special atraumatic technique must be used for the insertion of deflection cords (bimanual technique; see Fig 6-28a). Additional details regarding interdental and cervical finish lines are given in the next section ("Cervical/proximal margin configuration and localization").

### 2. Finishing

It is essential to produce preparations without sharp angles (Fig 6-25n), considering that the improved quality of both the preparations (sufficient clearance for the ceramic, smooth contours, absence of undercuts) and the final impressions will significantly facilitate the work of the dental ceramist, leading to minimal use of the die spacer and thus reducing the risk of post-bonding cracks.[61–63] There is no need to polish the preparation; only the margins need to be refinished with a fine-grain diamond (eg, 8856L-020). A coarse flexible disk is used to soften all transition line angles (see Figs 6-28d to 6-28g).

**FIG 6-25** *(cont) (m)* Note the slight corrections of the incisal edges *(black dotted lines)* that are still required to generate proper incisal clearance with the silicon index *(white dotted line). (n)* Preparations were refined during the dry stage with a retraction cord (right overlay image) to extend the margins into the sulcus at the interdental aspect for the miniwing concept. Note the smooth preparation surfaces, even though no polishing was done. No dentin was exposed during the process, which was very conservative (compare preoperative left overlay image with final preparations). *(o)* An additional cut of the horizontally sectioned silicon index allows a check more cervically that the space is still uniform. *(p)* Due to the preparation principles, final restorations could be fully layered with an excellent esthetic result and optimal marginal adaptation (postoperative view). This case required a minor correction during the delivery process, which is explained in Fig 6-82. (Laboratory work by Michel Magne, MDT; part *n* reproduced with permission from Magne and Cascione.[100])



t.me/Dr_Mouayyad_AlbtousH

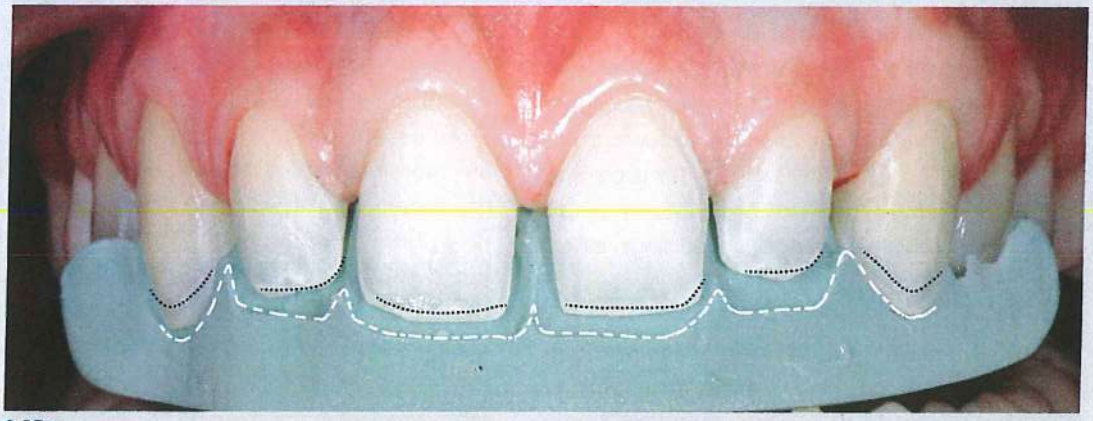

6-25m







6-25n

"Notebook" style silicon index

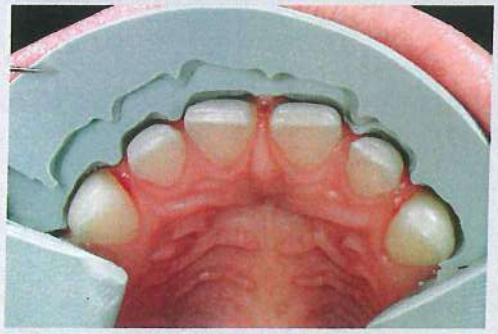

6-25o



6-25p



t.me/Dr_Mouayyad_AlbtousH

### 3. Final control of labial clearance

It is important to control the space available at different horizontal levels of the preparation (from cervical to incisal); this can be easily accomplished by sectioning the silicon index according to the "notebook method" (Fig 6-25o; see also Fig 6-45e), which is like a bound multilayer index.

### 4. IDS

***This constitutes the last step of tooth preparation before impression, whether analog or digital technology is used.*** Eventual dentin exposures are refreshed with a bur (freshly cut) and sealed with a dentin bonding agent. IDS is covered in a separate section later in this chapter (see Figs 6-45 and 6-46).

All essential elements of tooth preparation are presented in Fig 6-26. A last evaluation of the preparation must include careful examination of the insertion path of the future restoration and absence of undercuts, especially in cases where the proximal margins extend more palatal (see Figs 6-41 to 6-43). Specific situations regarding margin configuration and localization are discussed in the following section.

## Checklist for anterior BPR preparation

1. Chamfer size (0.3–0.4 mm)
2. Interdental extension for miniwings
3. Axial reduction (0.6 mm) - CHECK WITH INDEX
4. Incisal reduction (1–1.5 mm) - CHECK WITH INDEX
5. Absence of sharp internal line angles
6. Absence of retentive concavities (interdental)
7. Margin definition (palatal butt margin)
8. Incisal edge "seat"

**FIG 6-26 Basic elements of anterior tooth preparation.** These schematic views show that only a frontal/horizontal insertion path *(a, right)* allows respect of the natural tooth shape with the preparation: The mesiodistal dimension is narrower cervically compared to incisally *(arrows in a, left)*. *(b)* Axial reduction can vary between 0.3 and 0.4 mm at the cervical margins and up to 0.5 to 0.6 mm at midheight, but it might exceed those values when masking of discolorations is required. Incisal clearance approximates 1.0 to 1.5 mm but can extend up to 5 to 7 mm in the case of a fractured tooth (see Fig 6-10c). Note that the highest curvature (zenith) of the gingival margin is found at the distal level of central incisors *(* in b, left)*.[165] When the contour of the gingiva is too symmetric (and lacks this distal shift), use of a retraction cord is advocated to extend the margin into the gingival sulcus (distogingival) and obtain this effect by the contour of the restoration. *(c)* It is extremely important to round off all sharp edges (incisal view), which can be accomplished using coarse flexible disks (see Fig 6-28).



t.me/Dr_Mouayyad_AlbtousH

## FRONTAL/HORIZONTAL INSERTION PATH

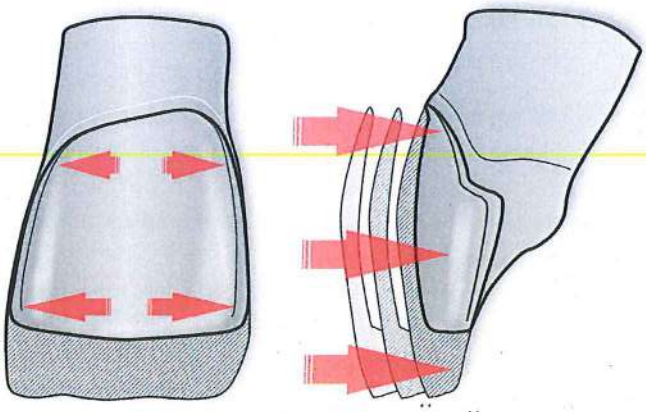

6-26a

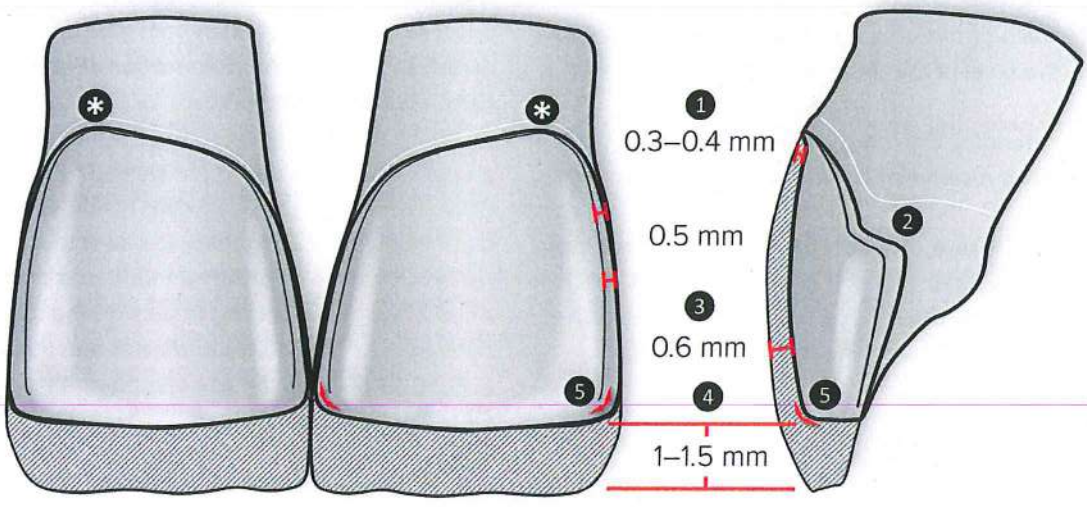


6-26b

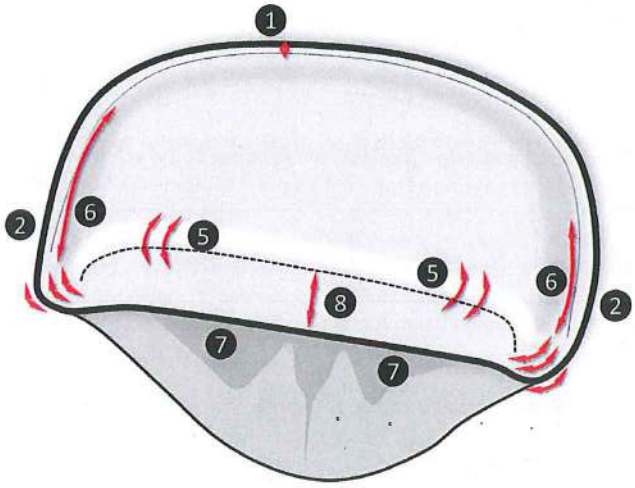


6-26c



t.me/Dr_Mouayyad_AlbtousH

## Cervical/proximal margin configuration and localization

### Cervical margins

In the cervical and proximal areas, the creation of a light chamfer without internal line angles is universally accepted. Such a finish line will allow a maximum preservation of enamel. For optimum esthetic results, it is recommended that the scalloped contour of the gingiva be respected. Insertion of a thin deflection cord (eg, Gingibraid 0a or 1a, VanR) may facilitate this task by underlining the individual gingival perimeter. In this case, the chamfer is prepared approximately 0.5 mm away from the cord (Fig 6-28b), leading to an equigingival margin once the cord is removed. ***For intrasulcular margins, the chamfer is extended to the level of the deflection cord.***

***Extending the margins into the sulcus is absolutely recommended in the following situations:***

- **Closure of diastema or black interdental triangle:** This should allow the dental technician to create a progressive emergence profile of the miniwing (see Fig 6-44).[37]
- **Case of cervical discoloration** (eg, nonvital teeth or tetracycline-stained teeth, when the dark band is located near the gingiva).
- **Gingival contouring:** In case of symmetric gingival contour (central incisors), the zenith of the gingiva can be shifted distally by the contour of the restoration (slight pressure on the gingival margin).

### Interdental margins

The amount of interdental extension depends on the type of interdental contact (Fig 6-27). Light contacts can be removed by conservatively extending the preparation limit (Fig 6-27, left). ***With a large contact surface, however, it is recommended that the surface be stripped open to create accessible margins without excessive interdental penetration (Fig 6-27, right, and Fig 6-28c).*** Except for two peculiar situations that require extending the interdental preparation toward the lingual (wrapping of old Class 3 restorations and reduction of diastemata/black triangles; see Fig 6-43), it is best to avoid useless sacrifice of proximal tooth substance. ***Another way of retracting tissues during ultraconservative tooth preparation is illustrated in Fig 6-29 through the use of rubber dam in a CAD/CAM case.***

**FIG 6-27 Definition of interdental extension (horizontal cross-sectional schematic views).** *(a)* The interdental margin *(red arrowheads)* can extend beyond a light contact point without significant sacrifice of tooth substance. *(b)* On the other hand, it is recommended that the preparation not be extended beyond a large proximal contact surface because of the significant amount of enamel that must be cut and the associated risks of dentin exposure *(triple white arrowheads). (c)* Instead, margin location can be kept conservative, provided that the contact surface is stripped open, which facilitates accurate reproduction during impression making. In all cases, a "ceramic-to-ceramic" interdental contact point will be recovered when the restorations are placed. Part c is illustrated with two clinical cases in Fig 6-42.

**FIG 6-28 Tooth preparation of biocorroded teeth: finishing.** The mock-up–driven labial reduction is already accomplished. This is now phase II (dry finishing). The bimanual technique is used to insert a deflection cord in an atraumatic way *(a)*, and the light chamfer is finalized 0.5 mm away from the cord *(b)* using an 860-016 bur. Note the biocorrosion lesions with exposed dentin on the labial surface, which will require IDS.



t.me/Dr_Mouayyad_AlbtousH

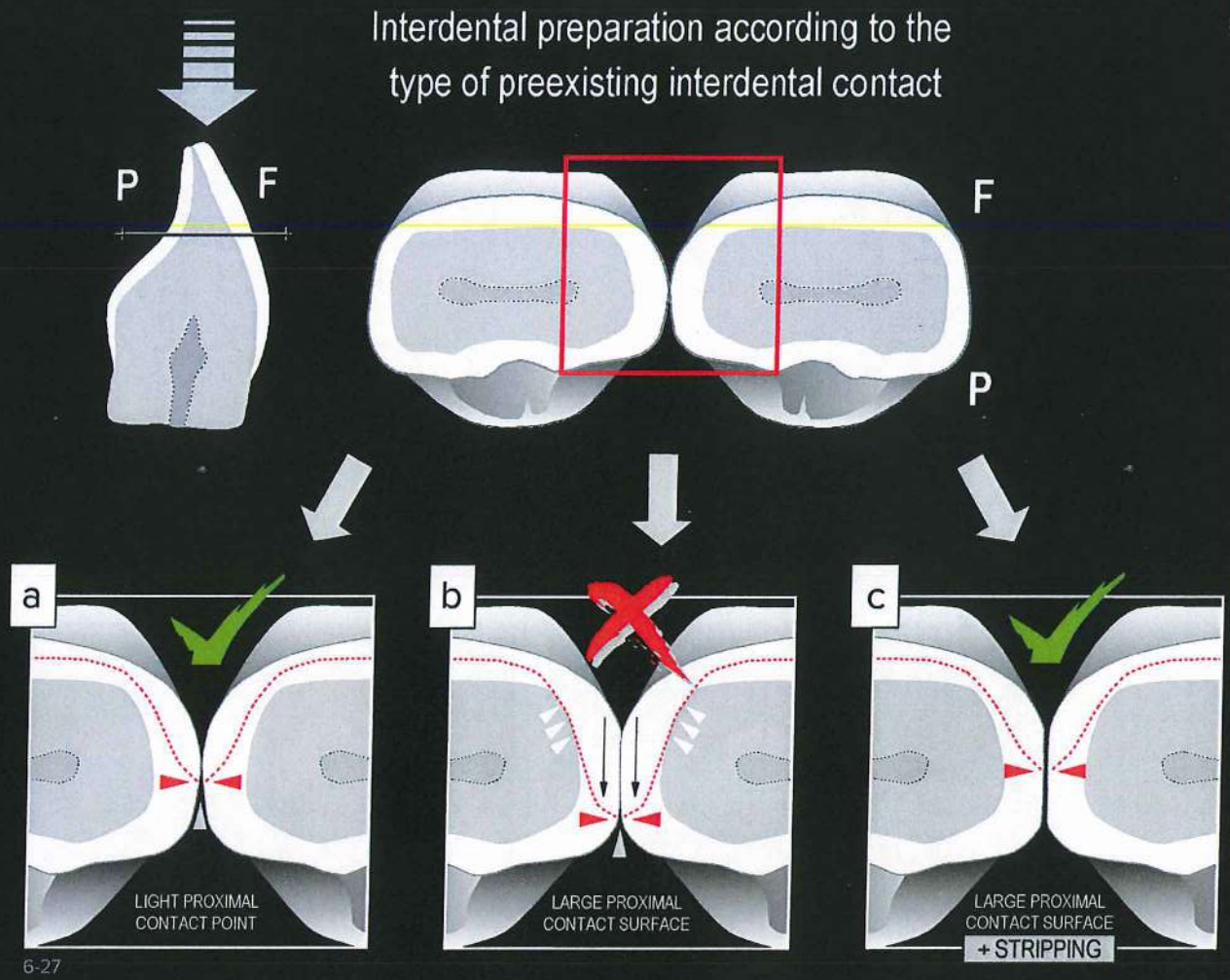


6-27



6-28a



6-28b



t.me/Dr_Mouayyad_AlbtousH

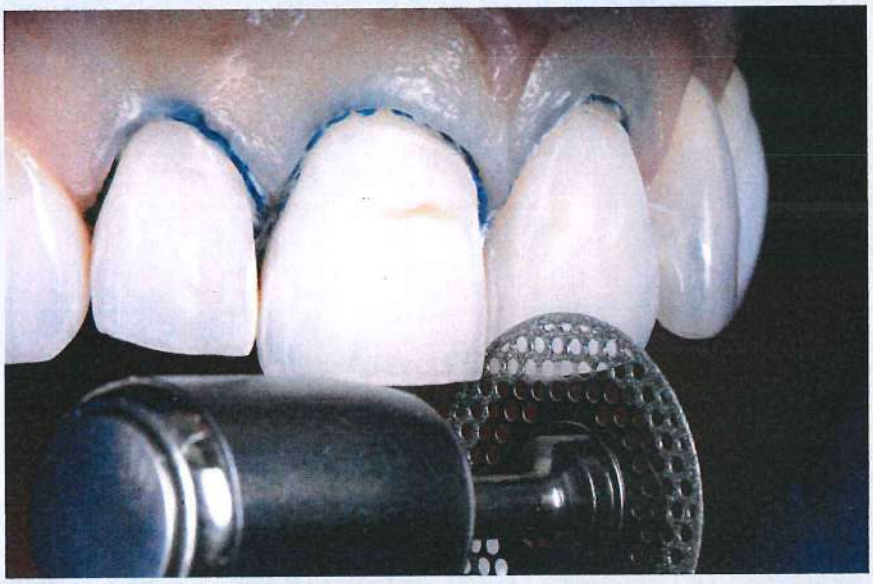

6-28c



6-28d



6-28e



6-28f



6-28g

**FIG 6-28** *(cont) (c)* Interdental contacts are cautiously stripped with an ultrafine diamond disk (VisionFlex, Brasseler) as explained in Fig 6-27 *(bottom right)*. Sharp edges are removed, especially at the labioincisal edge *(d and e)*, and rounded off with coarse flexible disks *(f,* IDS already applied to the biocorrosion lesions). *(g)* A metal band (Tofflemire) can be used to protect the adjacent tooth/preparation while rounding off the incisoproximal line angle with the disk. An alternative technique is to use oscillating tips (see Figs 6-30 and 6-31). *(h)* Note the perfect impression and absence of tearing, especially at the interdental level, where the small gap obtained with the diamond disks allowed the impression material to squeeze through the contact during retrieval (see more information about final impressions in Fig 6-48). The final restoration of this case is shown in Fig 6-57.


t.me/Dr_Mouayyad_AlbtousH

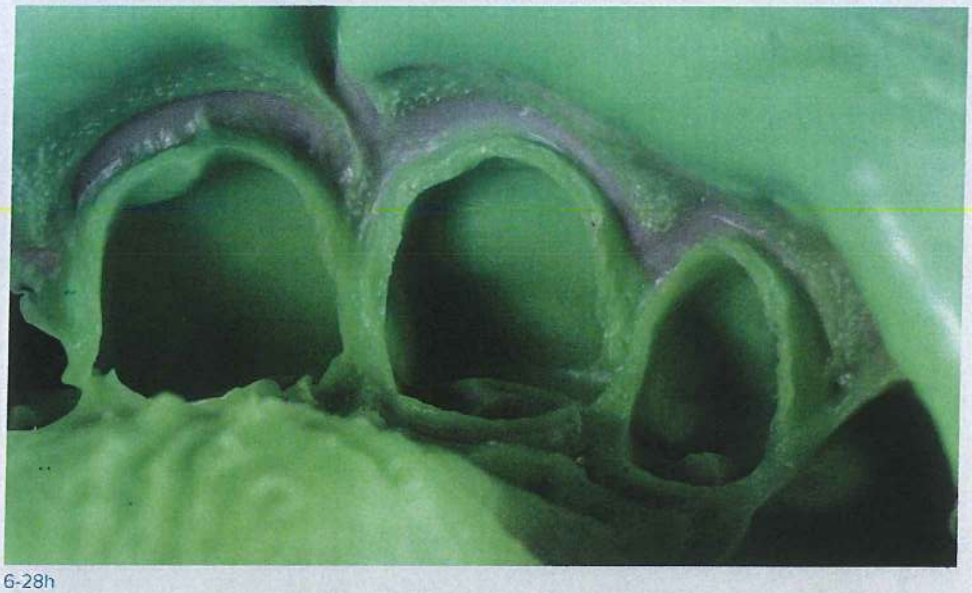

6-28h





6-29a



6-29b



6-29c

**FIG 6-29 Mock-up–driven minimal veneer preparation and finishing under rubber dam.** This diagnostic approach (dual-additive wax-up/mock-up) and initial treatment planning (including surgery) for this case was presented in chapter 5 (see Figs 5-13 and 5-14). The final mock-up *(a)* was used for the calibrated reduction of the teeth using round diamond burs *(b and c)*.



t.me/Dr_Mouayyad_AlbtousH

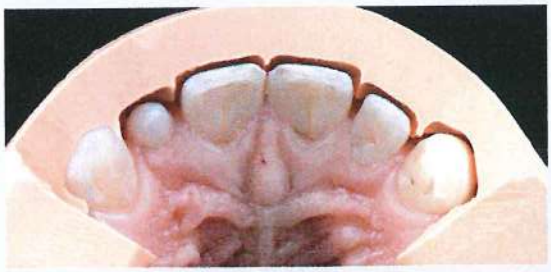

6-29d



6-29e

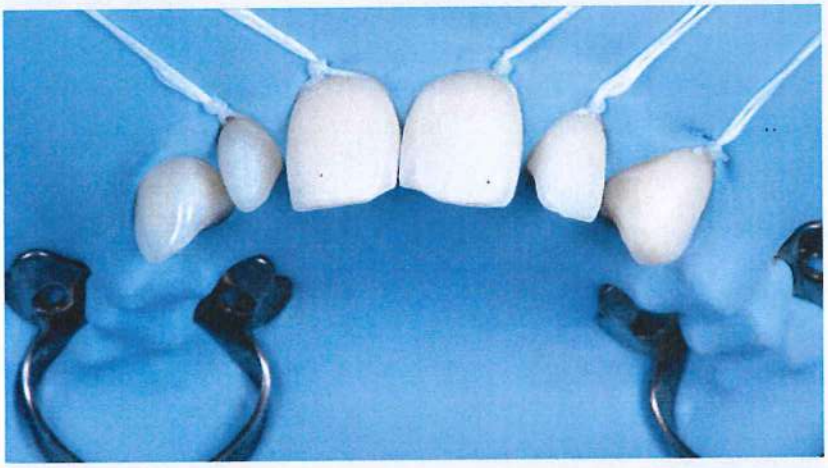

6-29f

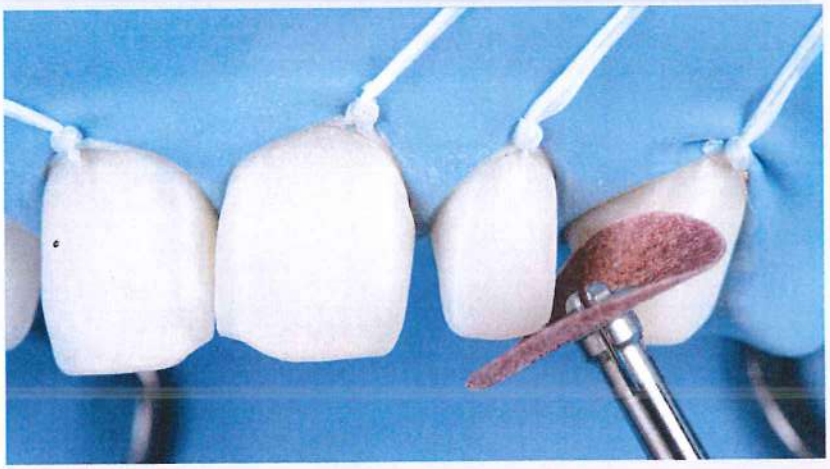

6-29g

**FIG 6-29** *(cont) (d and e)* Control of reduction with the silicon indexes. Note the healthy gingiva despite the fact that the patient was wearing the mock-up for several weeks. This case illustrates an alternative method to deflect the tissues and finish the preparations using rubber dam and a special ligature (described in chapter 3, Fig 3-26) on each tooth. *(f)* The ligature is attached to the inverted rubber dam frame to pull the tissues. *(g)* Note the excellent retraction and protection of the interdental papillae allowing access and fine finishing of the interdental margins. *(h)* Immediately following rubber dam removal, the preparations were powdered for scanning (overlay image with design directly copied from the mock-up—Cerec Biogeneric Copy). *(i)* Milled composite resin restorations on model (each veneer was customized according to the technique described in chapter 4, Fig 4-28). *(j)* Postoperative view after restoration delivery (with overlay image of preoperative view). The preliminary steps of this case are found in chapter 5 (Fig 5-14).



t.me/Dr_Mouayyad_AlbtousH

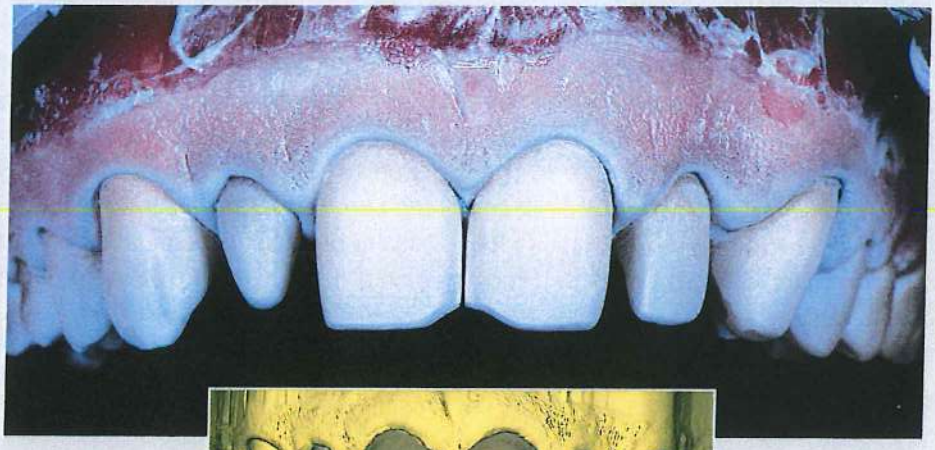

6-29h





6-29i





6-29j



t.me/Dr_Mouayyad_AlbtousH

***A significant advancement in interdental preparation was made with the introduction of sonic oscillating preparation techniques*** (Sonicflex/Sonicsys, KaVo; Fig 6-30; see also chapter 3, Figs 3-27e and 3-27f).

Due to their nonrotary action and half-bur shape (Figs 6-30 and 6-31), oscillating tips allow rapid and minimally invasive preparation. Margin definition is significantly enhanced and poses no risk to intact neighboring tooth surfaces. These tools are extremely useful in cases of marked crowding (see Fig 6-45f). Especially when used on large interdental contact surfaces and overlapping teeth, sonic tips allow significantly more conservative proximal preparation as compared to burs (Fig 6-30b). Another indication for oscillating preparation is the need for subgingival margins, which can be finished precisely without damaging the soft tissues.

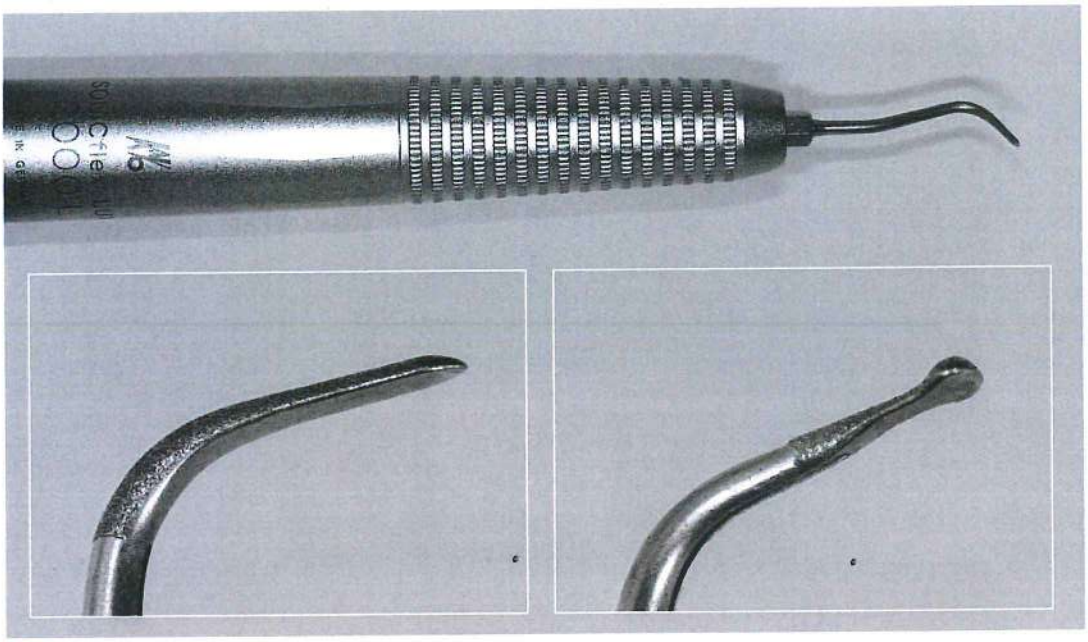

6-30a

**FIG 6-30 Oscillating instruments and their advantages over rotary instruments.** *(a)* Oscillating instruments include an air-driven sonic handpiece *(top)* and various tips with a "half-bur" shape featuring a flat nonworking surface. Typical instruments are the half-torpedo–shaped *(left)* and hemispheric *(right)* tips. More tips are described in chapter 3 (Fig 3-27e). *(b)* A significant amount of tissue can be saved when the interdental preparation is achieved with the half-torpedo–shaped tip because its cross section exactly conforms to the design of the margin *(left*, horizontal cross-sectional views as in Fig 6-27). When a traditional cylindric bur is used instead *(right)*, there is a high risk of overpreparation and dentin exposure *(white arrowheads)*, in addition to the risk of damaging the neighboring tooth *(black arrowheads)*.

**FIG 6-31 Oscillating preparation in a standard case.** The right central incisor had been fractured, and both central incisors will be veneered (see preparatory and diagnostic steps of this case in chapter 5, Fig 5-4). *(a)* Thin traditional burs can be used to begin the interdental preparation; special care must be taken (eg, use of a metallic band) to protect the neighboring tooth. *(b)* Final definition of the margin is achieved with an oscillating half-torpedo–shaped instrument. *(c)* In this specific situation, the task was facilitated by the presence of a composite restoration on the lateral incisor that could be stripped at the mesial aspect. *(d)* The proximal margin is sharp and accessible. *(e)* A uniform space is generated both labially and interproximally.



t.me/Dr_Mouayyad_AlbtousH

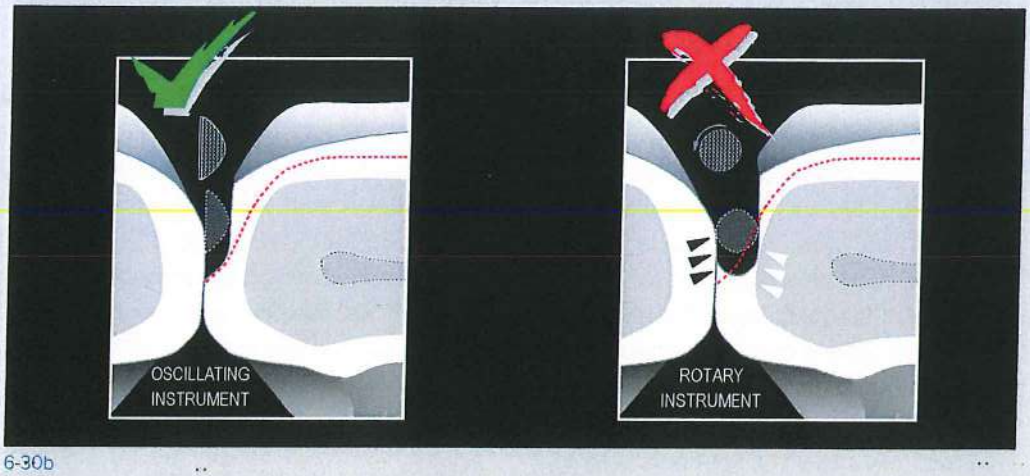


6-30b



6-31a

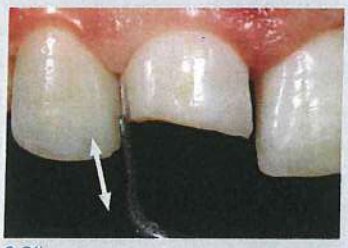

6-31b



6-31c



6-31d



6-31e



6-31f



6-31g

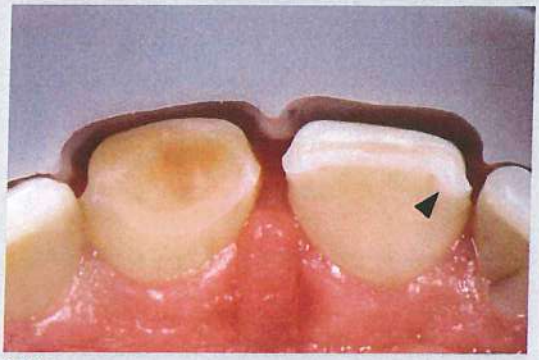

6-31h

**FIG 6-31** *(cont) (f to h)* Sonic tips were used again after the incisal reduction: The hemispheric tip is ideal to round and soften the contour of the margin at the transition between the axioproximal wall and linguoincisal edge *(black arrowhead in h)*. All prepared surfaces feature soft contours and were kept within enamel except for the fractured area of the right central incisor *(e)*. There seems to be a reduced space for the restoration in *h* (right central incisor, IDS applied) due to the more cervical cross section and different view angle.



t.me/Dr_Mouayyad_AlbtousH

## Wrapping and overlapping

The systematic creation of incisal and interproximal wraparound is applied in practice by the majority of clinicians and has been optimized in view of the biomechanical integration of the veneers. The extension of wrapping is dependent on the initial situation (eg, preexisting crown fracture) and the restorative objective: If major modification of form or closure of diastemata is planned, a maximum wraparound is imperative.

> Practically speaking, the application of interproximal and incisal wraparound offers many advantages[20]: It facilitates the esthetic definition of the BPR in the incisal zone, it enhances the liberty of the dental ceramist with respect to form and emergence profile of the restoration, and, most important, it facilitates the placement of the final restoration (eg, stabilization of the BPR and easy access to all margins during the bonding procedure).

As early as the late 1980s, a photoelastic study by Highton et al[166] revealed the importance of an incisal/interdental overlap, which appeared to provide the ceramic with a superior intrinsic resistance due to better stress distribution in the restoration itself. Additional scientific evidence suggests the type of incisal finish line to be used as a function of type and amount of incisal overlap.[23,57] Because the indications for BPRs have been successfully extended to the treatment of crown-fractured incisors and worn anterior dentitions (see Figs 6-10 to 6-12),[14–16,18–20] new questions have arisen concerning the design of such restorations. The extent of tooth substance loss must be considered because it will significantly influence the location of the palatal finish line (Fig 6-32). Different stress patterns are expected on the palatal margin of the restoration depending on the original level of the fracture line (eg, moderate fracture through the palatal concavity versus extensive fracture through the cingulum).

**FIG 6-32 Differential margin location for moderate or severe preexisting coronal fractures: tangential tensile stresses.[23]** *(a)* Possible location of the palatal fracture line *(arrowheads)*: in the area of the palatal concavity for the moderate fracture *(left)* and in the area of the tubercle convexity for the severe fracture *(right)*. *(b)* Stress distribution in the future restoration margin may differ depending on the area of fracture. Original contours and finite element mesh developed for the optimization of BPRs *(top)*.[23] The position of the palatal margin is indicated for different initial situations: I1–I4 (minimum loss of incisal structure), F1–F2 (moderate loss consequent to fracture or wear), and F3–F4 (severe loss consequent to fracture or wear). The facial aspect of the veneer is the same for all designs. The location of the palatal margin is the same for I4 and F2. The horizontal and vertical displacements are fixed at the cut plane of the root *(mesh image, arrows)*. The incisal load (50 N) is located approximately 1.5 mm below the incisal edge. Generally speaking, elevated tensile stresses are found at margins located nearby the palatal fossa (more explanations given in Fig 6-33). (Modified with permission from Magne and Douglas.[23])



t.me/Dr_Mouayyad_AlbtousH

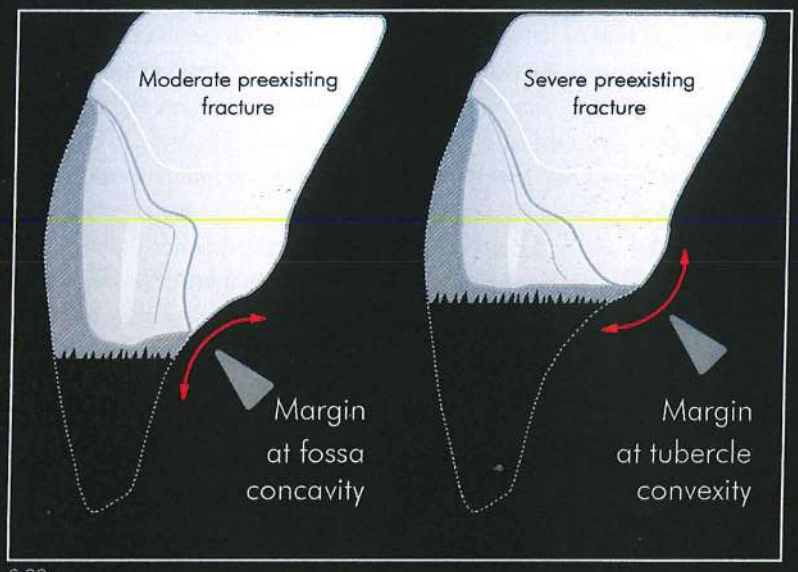


6-32a

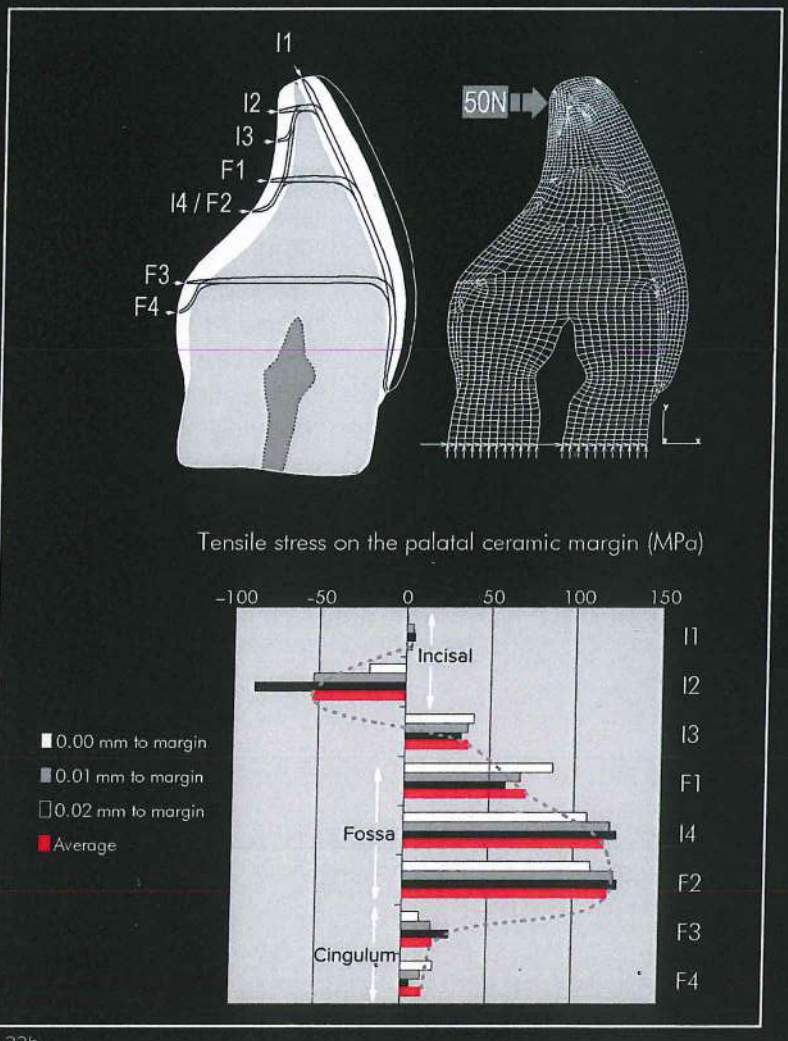


6-32b



t.me/Dr_Mouayyad_AlbtousH

Considering the high tensile stresses that may be generated in the palatal concavity during functional loading (Fig 6-33; see also chapter 1, Fig 1-6),[46] one must question whether the palatal "minichamfer," which is frequently prepared,[167] should not be replaced by a simpler finish line, such as a butt margin. The use of a butt margin actually provides the margin of the restoration with a strong bulk of porcelain, instead of creating a thin marginal extension of ceramic (as with a palatal chamfer). Figure 6-33 shows how changes in the palatal marginal design as well as the extension of BPRs influence the stress distribution during extreme functional loading. The restoration of moderately fractured and severely fractured incisors is considered. The results can be summarized as follows:

1. For maximum remaining tooth substance, the stress pattern along the palatal surface is barely influenced by the finish line of the BPRs (Fig 6-33, left column). Considerable differences are detected, however, when comparing stresses at the level of the restoration margin. Limited incisal overlaps (butt margin or minichamfer) protected the restoration margin from harmful tensile stresses in the palatal fossa. The use of a long chamfer that extends into the palatal concavity is not recommended because it creates a thin extension of ceramic in an area of maximum tensile stresses. Extending palatal margins too much into the fossa often results from an extended proximal preparation that tends to give the laminate veneer a design close to that of a three-quarter crown (Fig 6-34, left).[168] For this reason, in the case of extensive interdental preparation, the use of a minichamfer or a butt margin is recommended in order to avoid the palatal concavity (Fig 6-34, right).
2. In the presence of moderate crown fractures (incisal third) or severe wear, the palatal finish line is often localized in the zone of maximum tensile stresses (Fig 6-33, F1 and F2). In these situations, a butt margin limits the extension of the ceramic, thus reducing the amount of stress at the restoration interface. Worn teeth present the same dilemma as teeth with moderate fracture: *(b)* The incisal line crosses the critical zone of the palatal fossa. Here again, a butt margin (F1) permits minimal extension of the preparation with regard to the concavity, while the minichamfer (F2) places the restoration margin in an area of higher stress.

***When dealing with preexisting type I4 and F2 situations (extended lingual chamfer or biocorrosion-based situation), the lingual margin should be elevated with direct composite resin to convert those cases into I2 and F1 situations, respectively.*** In other cases with a larger amount of palatal clearance or full-mouth reconstructions with opening of the bite (including the Dahl principle), indirect palatal composite resin veneers can be combined with an I2-type or F1-type labial porcelain veneer (see Figs 5-19 and 5-21).

**FIG 6-33 Modified Von Mises stress distribution throughout the buccolingual section of restored incisors.[23]** The *thick dotted arrows* show the location and direction of load. The *thin white arrows* show the margin location (m). *(left column)* I1–I4: Margin location is very favorable for I1 and I2, less favorable for I3, and critical for I4. Stresses in the palatal concavity were well above 100 MPa only for I4 (see Fig 6-32b). *(right column)* F1 to F4: Margin location is not ideal but acceptable for F1 and critical for F2. Stresses in the palatal concavity are well above 100 MPa for F2 (see Fig 6-32b). Margin location and overall design of F3 and F4 are very favorable: The tooth-restoration interface and the restoration itself are not subjected to elevated stresses (see Fig 6-32b). (Reproduced with permission from Magne and Douglas.[23])



t.me/Dr_Mouayyad_AlbtousH

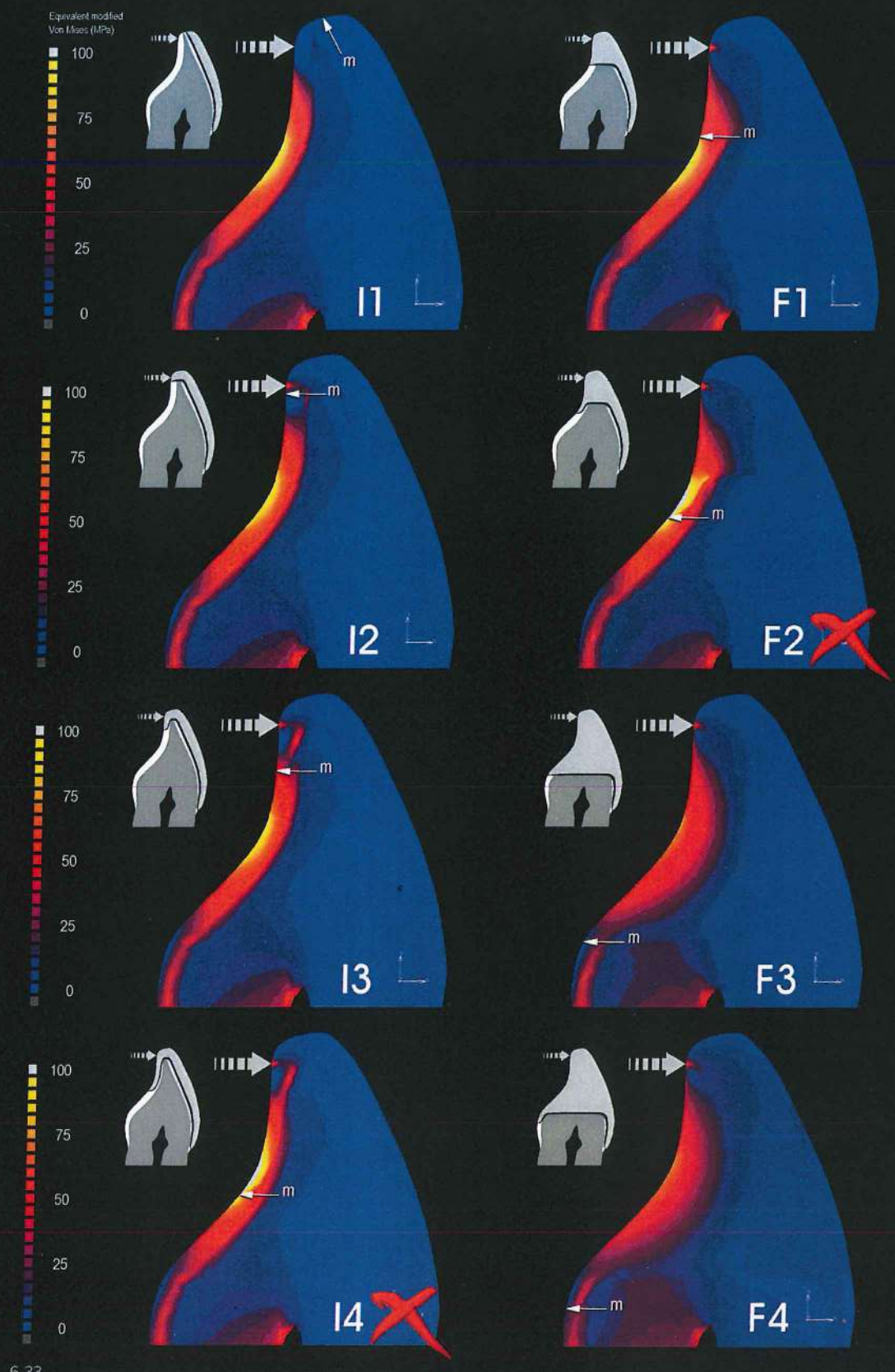


6-33



t.me/Dr_Mouayyad_AlbtousH

One should exercise caution when designing an enamel butt margin and avoid inverting the natural angle of the incisal surface. This situation may present longitudinally sectioned enamel rods, which may significantly affect the quality of subsequent adhesion to enamel.[169] The orientation of enamel prisms is illustrated in Fig 6-35. The situation appears most critical in the incisal area. For a butt margin perpendicular to the tooth long axis (or parallel to the natural incisal wear facet), enamel prisms are still sectioned at an angle of 30 degrees or more. For fractured teeth, a horizontal butt margin is adequate because a horizontal finish line will generally section the enamel prisms obliquely at an angle greater than 50 degrees. Another way to avoid the palatal concavity of fractured teeth would be to make a composite buildup designed as a "stress-breaker."

This modality was studied in a load-to-failure test by Andreasen et al[15] and yielded great ultimate crown strength (see Fig 6-11a). Gresnigt et al confirmed that existing composite resin restorations underneath veneers are not detrimental to the strength and survival rate of the restoration.[32,65] The finite element mesh was used to reproduce this situation and calculate the stress distribution (Fig 6-36). Presence of the composite resin provides a significant effect, simultaneously allowing the decrease of stresses in the palatal concavity (stress redistribution into the more "flexible" composite resin) and relocating the margin of the veneer into the "safe" incisal area. However, such buildups must be carefully considered because thick layers of composite proved to have a significant influence on the development of postbonding flaws.[61-63] ***Rebonding of the fractured tooth fragment, when possible, is certainly indicated because it has been proven to give good results when supplemented with a veneer.***[14] In fact, this treatment modality seems appropriate prior to placement of a laminate veneer because of uniform thermal expansion and the absence of hygroscopic expansion of the rebonded tooth fragment.

**FIG 6-34 Dilemma of extensive interdental preparations.** *(a)* Maximum penetration of the interdental space often leads the clinician to extend the incisal overlap during tooth preparation. The resulting veneer unfavorably involves the palatal concavity. *(b)* Clinical case of veneers featuring the problematic design illustrated in *a*. The accelerated degradation of the margins and short-term failure of the ceramics appeared at the level of the long palatal chamfer on the maxillary left central incisor. *(c)* Maximum interdental preparation is compatible with the avoidance of the palatal concavity and the realization of a butt incisal overlap. Such a design is especially recommended for the closure of interdental spaces due to gingival recession as well as for the total wrapping of preexisting Class 3 composites when indicated (see also Figs 6-40 and 6-41).[20] When redoing such a case of fractured extended lingual chamfer, the lingual margin should be elevated with composite resin to convert this I4 situation into I2 (see Fig 6-33). (Modified with permission from Magne and Douglas.[23])

**FIG 6-35 Orientation of enamel prisms measured on an intact tooth section.** Prism orientation is indicated (in degrees) based on measurements made at the possible locations of the margin.[23] (Modified with permission from Magne and Douglas.[23])

**FIG 6-36 Stress distribution throughout a fractured incisor veneered on top of a composite buildup (F1cp).** The *thick dotted arrows* show the location and direction of load. The *thin white arrow* shows the margin location. The stresses in the palatal concavity are decreased by redistribution into the more "flexible" composite. The margin of the veneer (m1) is relocated in the "safe" incisal area. This principle is applicable to type I4 and F2 preparations, for which composite resin can be used to elevate the lingual margin and convert the design to I2 and F1, respectively. (Modified with permission from Magne and Douglas.[23])



t.me/Dr_Mouayyad_AlbtousH

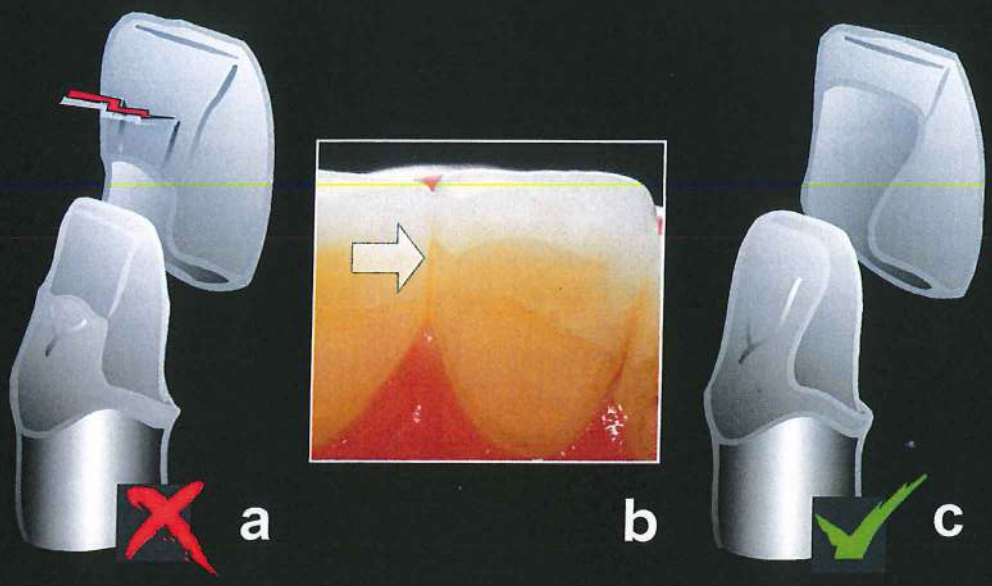


6-34

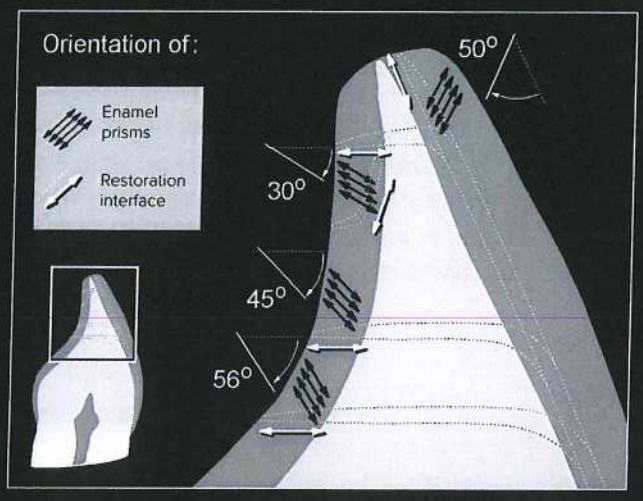


6-35

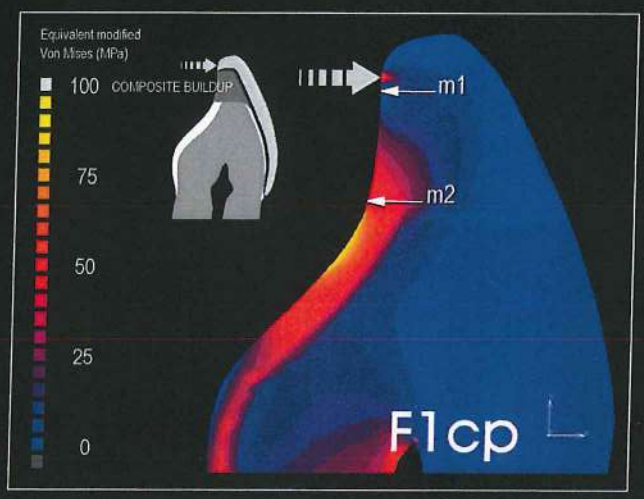


6-36



t.me/Dr_Mouayyad_AlbtousH

3. In the presence of severe crown fractures (incisal two-thirds), the palatal margins are subjected to low tensile forces because they are located in the low stress area of the cingulum (see Fig 6-33, F3 and F4). The latter, with its smooth convexity, can be combined either with a butt margin or a mini-chamfer without generating harmful stresses. Surprisingly, severe fractures (F3–F4) present characteristics less complex than those found in moderate fractures. The restoration itself shows lowered stresses in the palatal fossa because of stress redistribution in the bulk of the porcelain. Interestingly, the tooth-restoration interface is not subjected to stresses more harmful than those found in other restorative designs. Coincidentally for patients with crown fractures presented in Figs 6-10, 6-21, and 6-31, BPRs were placed on both central incisors with the palatal margin on one incisor placed below the palatal fossa, while on the other incisor the palatal margin was placed above it (Fig 6-37). Those designs result from different preexisting loss of tissue but both happen to be favorable in view of scientific data discussed within this section.

## Peculiar situations

### Thin versus thick teeth

Teeth restored with porcelain veneers are able to mimic the behavior of intact teeth with similar stress-distribution patterns. From the previous section, it is observable that stresses are highly correlated to shape (convex vs concave) and composition (eg, enamel-dentin distribution and restorative material thickness) and do not depend on the exact load direction or magnitude. This observation has been confirmed by reversing the load direction.[59] Due to the contrasting anatomy of the palatal surface, it is not surprising that the stress at the palatal ceramic margin is correlated with the stress of the intact incisor at the corresponding location (ie, high in the palatal fossa and low at the level of the tubercle). These anatomical factors can vary from tooth to tooth and from patient to patient, and one can anticipate that extremely thin teeth will be subjected to more bending stresses compared to thick teeth. Two extreme anatomical types are presented in Fig 6-38: a thin flat tooth that requires more incisal clearance to generate a certain bulk of incisal porcelain, and a thick curved incisor that requires only minimal incisal reduction. Careful observation of anatomical features of teeth to be restored (thick vs thin, flat vs concave) is imperative to the design optimization of BPRs.

**FIG 6-37 Ideal level of palatal margins.** Views of prepared central incisors *(left;* same patient as Fig 6-31) and BPRs on the master cast *(right).* The left central incisor is an F3-type BPR. The BPR on the right central incisor has an intermediate design between I2 and I3. The margin of both BPRs *(arrows)* could be placed outside the fossa *(red oval).* Note that the ceramic-to-ceramic interdental contact has been restored.



t.me/Dr_Mouayyad_AlbtousH

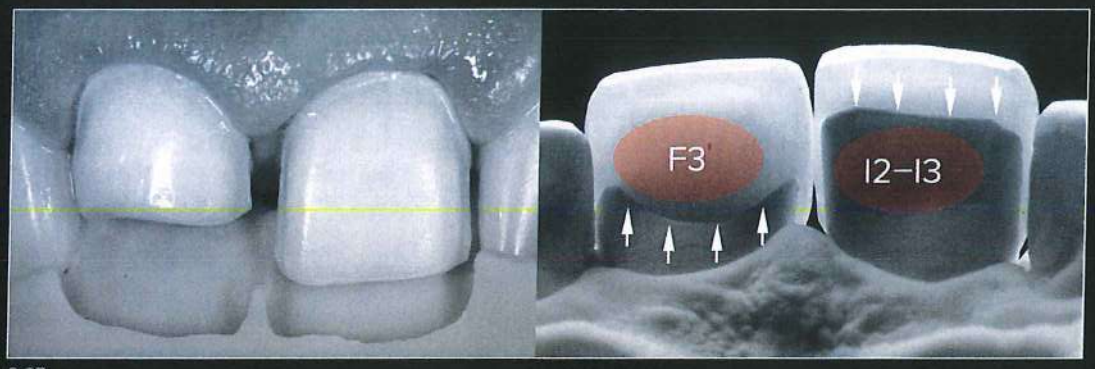


6-37

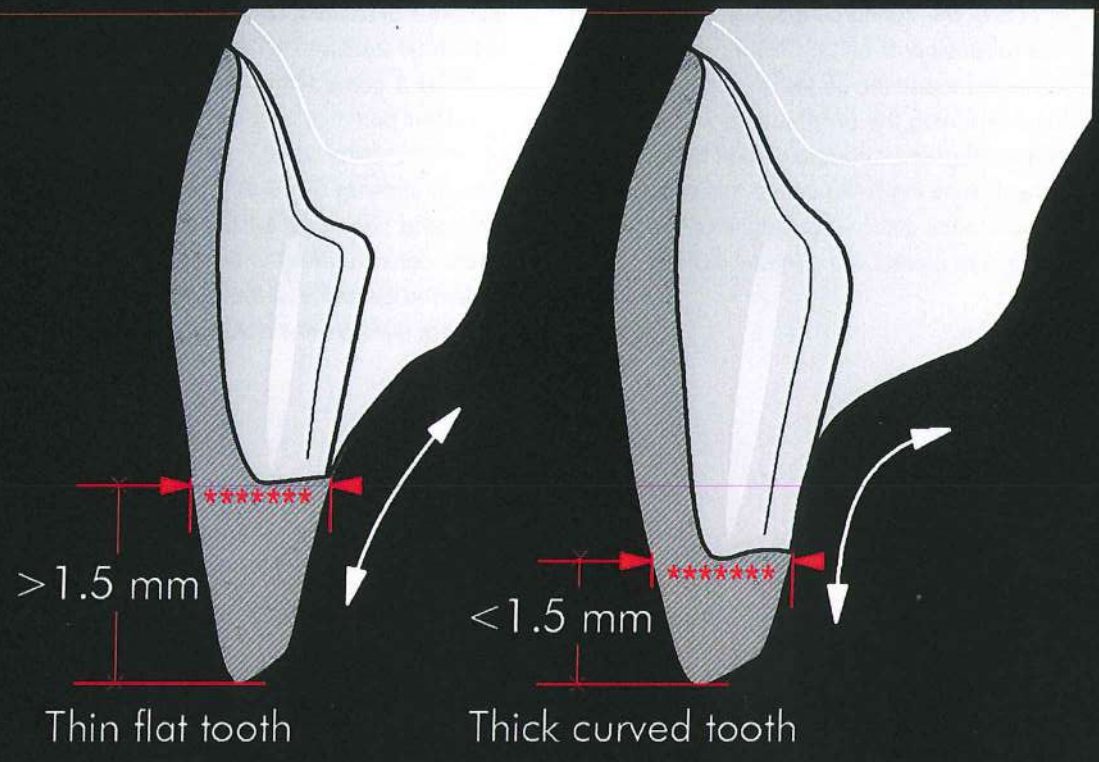


6-38

**FIG 6-38 Variable incisal clearance according to different anatomical type.** To create a critical thickness of incisal porcelain *(line of asterisks)*, the incisal edge of a thin flat tooth *(left)* must be reduced about 1.5 mm. The intrinsic resistance of the veneer will be enhanced without subjecting the palatal margin to harmful stresses (moderate palatal concavity). In a thick curved tooth *(right)*, a similar bulk of incisal porcelain is often compatible with 1 mm of incisal clearance. Again it is not recommended to proceed to extensive incisal reduction on such a tooth because it would place the palatal margins at the level of high tensile stresses in the deep fossa.



t.me/Dr_Mouayyad_AlbtousH

### Existing Class 4 defects

Extended loss of tooth structure (large Class 4 defects) can be restored by means of the laminate veneer alone (Fig 6-39, simplified approach).[15,20,23,24] Keeping an existing Class 4 restoration (or placing one) before using a BPR will not contribute to an increase in the ultimate strength of the tooth restoration complex[15] but could be considered as a positive resilient component underneath the veneer.[59] However, one should try to avoid large bulks of composite under thin porcelain veneer restorations because there is still significant concern about the additive effects of the curing contraction and high thermal expansion of certain composite resins.[61–63] Reducing in part the underlying composite resin (by deepening the preparation) will allow for a certain degree of compensation by the thicker ceramic (see Fig 6-14d where this principle was applied to the distal aspect of the central incisors and mesial aspect of the lateral incisors).

### Existing Class 3 restorations

Veneering teeth with preexisting Class 3 composite restorations again addresses the problem of interdental extension and positioning of the margins. The safety of interdental wrapping can be claimed because the most important mechanical events in incisors appear within the buccolingual plane.[29,31] Stresses and strains within the crown seem to be minimally affected by interdental preparations. However, mechanical loading is not the only source of stress. Additional factors must be considered, such as the polymerization contraction of the luting composite and the extremes of thermal changes. Problems related to thermal stresses can worsen in the presence of Class 3 composites. A numeric study indicated that partial or total wrapping of preexisting composite restorations is indicated to minimize thermal stresses (Fig 6-40).[64] ***Partial interdental wrapping seems to be the best compromise (more conservative) unless total wrapping is indicated because of the call for the miniwing concept (interdental closure).***

**FIG 6-39 Large Class 4 preexisting composites.** *(a and b)* Both central incisors present large Class 4 composite resin restorations that were removed immediately prior to tooth preparation. *(c)* The final preparations show the extent of the mesial interdental defects; *dotted areas* delineate exposed dentin that was sealed with a dentin bonding agent (IDS) prior to final impressions (solid master cast). *(d)* The corresponding porcelain restorations present a bulky mesial aspect but do not involve the remaining palatal surface. *(e)* Postoperative view following insertion of BPRs on the four incisors. Other views of this case can be found in Fig 6-81.

**FIG 6-40 Wraparound design in the presence of a preexisting Class 3 restoration.** The *white dashed arrow* shows the level of incisal preparation. *Gray dashed arrows* show the level of interdental preparation. Absence of interdental extension *(far left)* is not recommended due to limited esthetics and potential thermal effects of the intact remaining composite resin restoration.[64] Partial wrapping *(left center)* seems to offer favorable compromise for both esthetics and thermal stresses. Total wrapping *(right center)* might be indicated and is an advantageous design when combined with a butt incisal margin. Extensive chamfering into the palatal fossa *(far right)* must be avoided due to functional stresses (see also Fig 6-34, *center*) and because it often generates an acute incisal edge *(black arrowhead)*.



t.me/Dr_Mouayyad_AlbtousH



6-39a

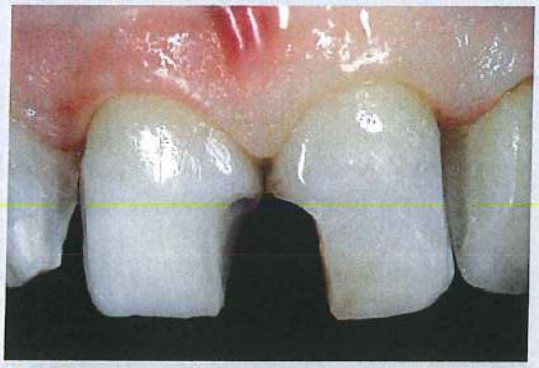

6-39b

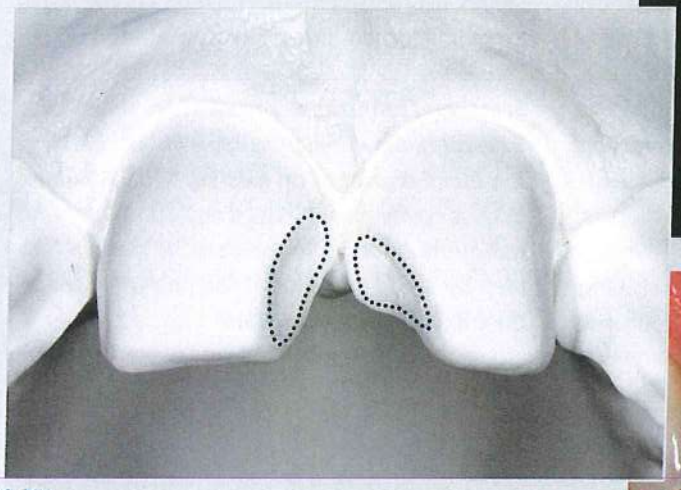

6-39c



6-39d



6-39e

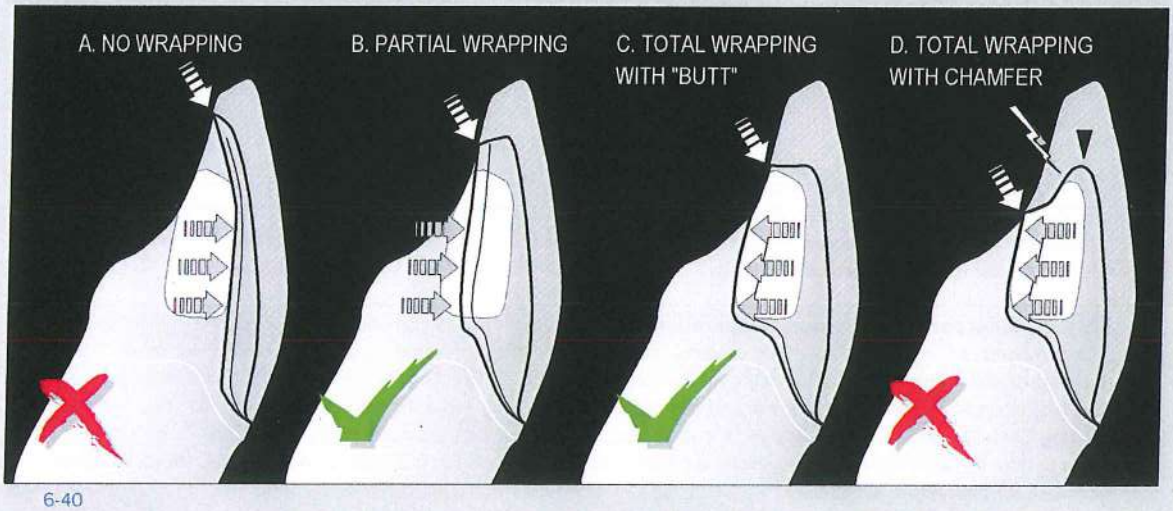


6-40



t.me/Dr_Mouayyad_AlbtousH

Overall performance of different degrees of interdental wraparound designs can be evaluated in light of practical and clinical parameters. The short-wrap veneer corresponds to a traditional and conservative proximal veneer preparation that stays facial to the interdental contact. This often precludes the need for temporization but ultimately leaves the tooth-restoration interface visible. Instead, preparations extending into the contact area hide the margin and provide a positive seat for precise insertion.[170] Practitioners and dental technicians, however, should know that long-wrap veneers are difficult to fabricate and manipulate, as a result of the extension of ceramic, delicate insertion axis, and margin definition. Clinically, typical errors in the course of extending proximal preparations include the realization of a deep incisoproximal chamfer (Fig 6-41, right). A minichamfer or butt incisal coverage is recommended instead. A safe method for interdental and incisal tooth preparation involves keeping the main axis of the bur (or oscillating tip) oblique or horizontal (Fig 6-41, left). Improper design often results from vertical preparations (Fig 6-41, right). Maximum wraparound is absolutely indicated when major changes of form or closures of diastemata (or interdental triangles) are planned, providing that an adequate margin (interdental chamfer) and ceramic thickness are achieved.

In other situations, a partial wraparound (medium wrap) may represent the best compromise between stress distribution, esthetics, and clinical practicality when placing porcelain veneers on teeth restored with Class 3 composite resins (Fig 6-42). In this situation, preexisting restorations must be carefully examined for their quality and eventually replaced during initial treatment (before prepping the veneers).

***In the long term, replacement of previous Class 3 restorations is still possible without affecting the facial aspect of an existing BPR. A palatal access cavity must be used and combined with adequate bonding to the ceramic margin*** *(see step-by-step sequence of such a repair procedure in chapter 7, Fig 7-13).*[31]

**FIG 6-41 Caution for maximum wraparound preparations.** Even though facial axial preparation can be achieved with the bur aligned parallel to the tooth long axis, ideal interdental and incisal cutting is achieved with a horizontal stroke *(left)*. When a vertical positioning of the bur is chosen instead, risks of excessive chamfering and overpreparing into the palatal fossa are obvious *(right)*.

**FIG 6-42 Ideal partial wraparound preparations.** Final stage of tooth preparation in the presence of existing Class 3 restorations. *(a)* The VisionFlex disk is cautiously used to slice the interdental contact. *(b)* Note the uniform reduction and interdental margin located within the future contact surface. *(c)* Finishing of the preparation includes removal of all sharp internal line angles *(black arrows)* with a Sof-Lex disk (3M). Note the interdental margin located within the existing Class 3 restorations. *(d and e)* This same design is also indicated in the absence of Class 3 restorations in order to hide the interdental margins and is explained schematically in Fig 6-27 (part c). (Parts *a* to *c* reproduced with permission from Magne and Belser.[52])



t.me/Dr_Mouayyad_AlbtousH

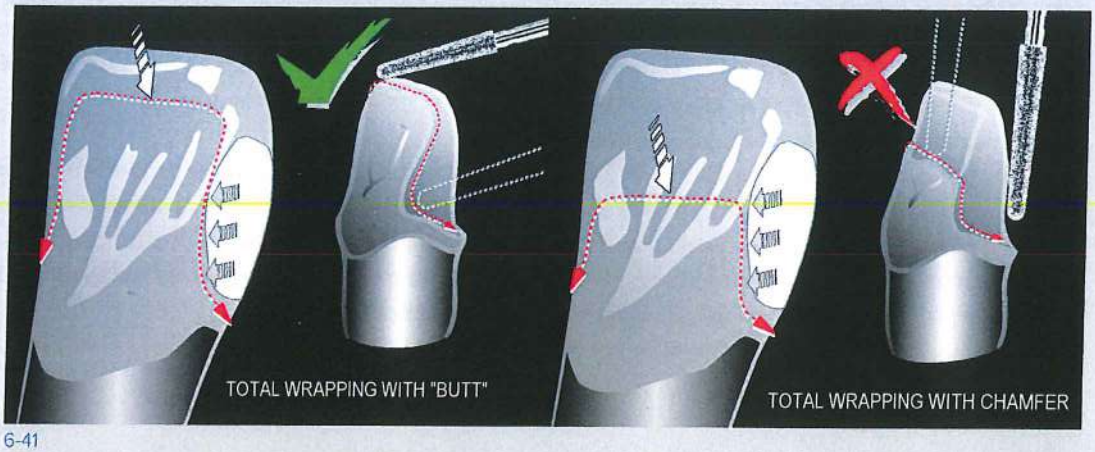


6-41

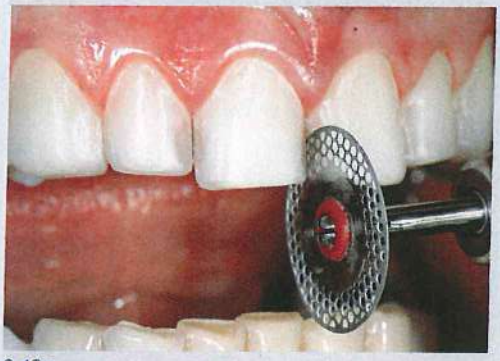

6-42a

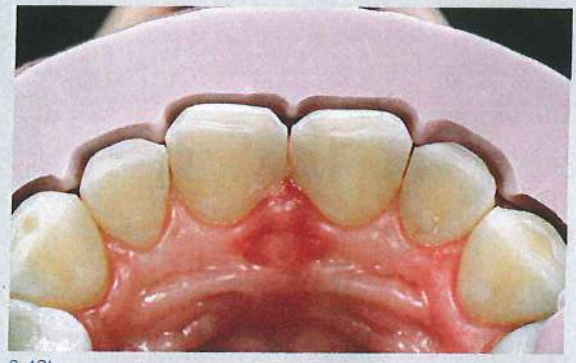

6-42b

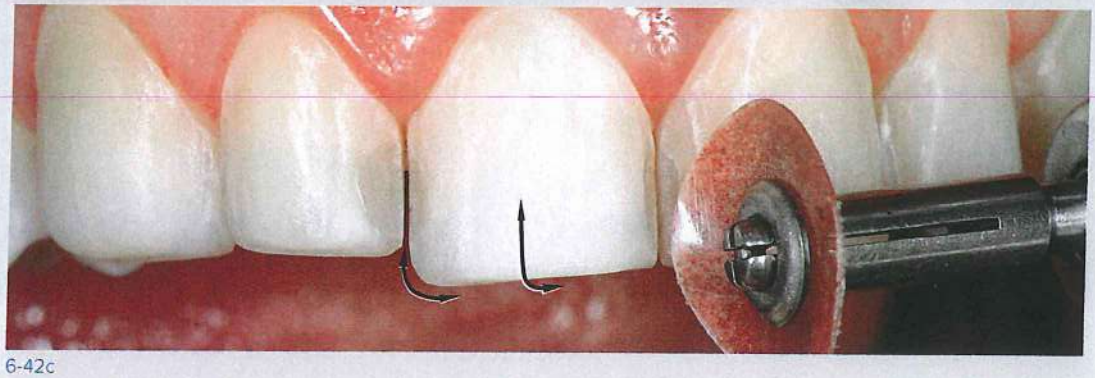

6-42c



6-42d

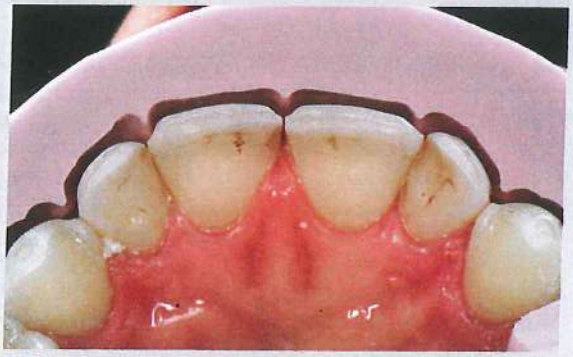

6-42e



t.me/Dr_Mouayyad_AlbtousH

### Preparations for closure or reduction of diastemata or "black" interdental triangles

Cases in which diastemata or black interdental triangles are to be closed require an extended interproximal preparation, which in turn allows the ceramist to produce a progressive emergence of the interdental extension (Fig 6-43a) to form a pyramidal miniwing (see design in Figs 6-6a and 6-6b). These very specific situations require a meticulous study of the insertion axis of the future veneer. It is therefore highly recommended that diagnostic preparations be carried out on the initial models.

***In the case of a reduced periodontium, a horizontal path of insertion is absolutely required in order to preserve the coronal tooth structure despite a reduced diameter of the tooth in the cervical area.[20]***

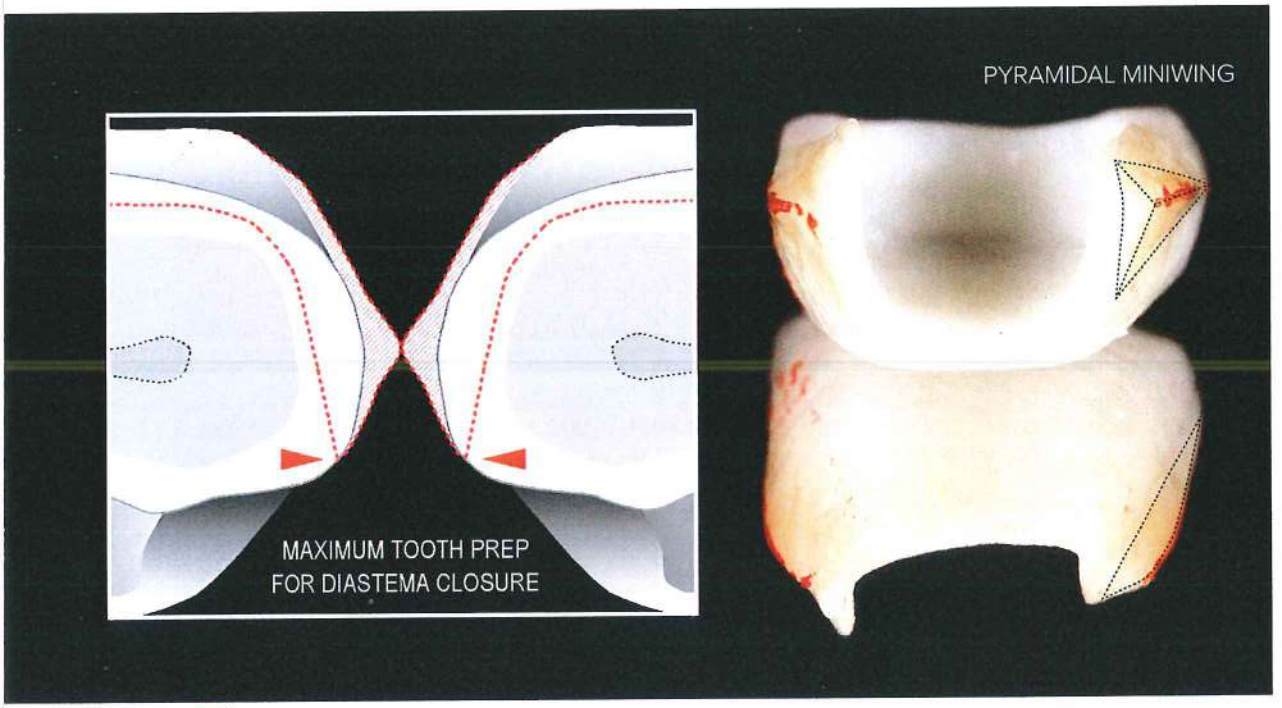


6-43a

**FIG 6-43 Tooth preparation for diastema closure.** *(a)* Closures of interdental triangles or diastemata are rare situations where maximum penetration of the proximal surface is required to allow the dental technician to generate interdental miniwings with progressive profile that compensates for the loss of soft tissue or abnormal tooth position *(left)*. *(right)* Typical aspect of the corresponding BPR; the miniwings, which form a precise line angle *(marked in red)*, are made with a porcelain of a higher chroma to prevent the illusion of a bulky tooth. *(b)* Teeth are often larger in the incisal area (A) compared to the cervical area (B). Maximum proximal extension must be combined with a butt palatal margin because it will allow a horizontal insertion path of the veneer. *(c)* The natural divergence of axial walls can be maintained, which logically leads to a maximum preservation of enamel (additional views of this case can be found in Fig 6-7). *(d)* When maximum proximal penetration is combined with a palatal chamfer, it will only allow an oblique insertion path of the veneer. In this case, the natural divergence of axial walls cannot be maintained, which logically leads to more invasive tooth preparation and increased risk of axial dentin exposure compared to *b*. (Part *c* reproduced with permission from Belser et al.[20])



t.me/Dr_Mouayyad_AlbtousH

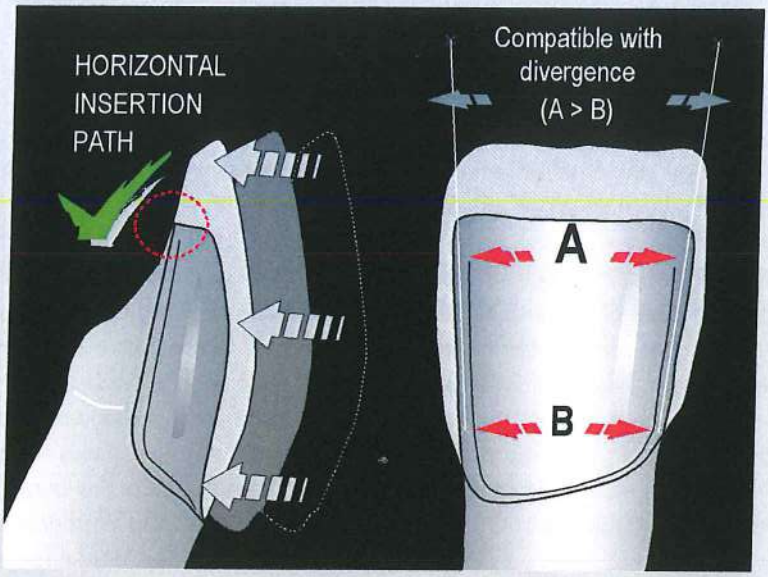


6-43b

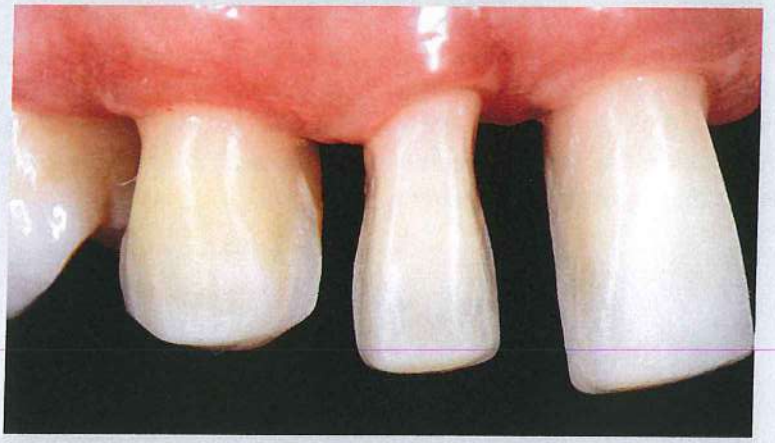

6-43c

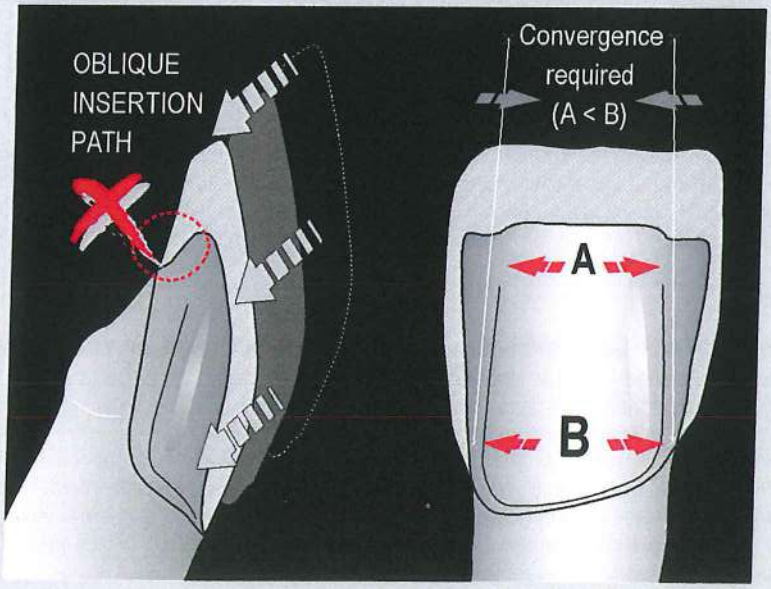


6-43d


t.me/Dr_Mouayyad_AlbtousH

Closure of open interdental triangles (consecutive to the loss of papillae) requires the same principle as discussed for diastemata. Figure 6-44 shows an additional requirement for the subtle closing of any kind of interdental space: To produce a gradually progressive emergence profile, the interdental cervical margin must be placed into the gingival sulcus. Such an approach was applied in the case of Fig 6-45. Closing of the space between the central incisors was first visualized with a basic diagnostic mock-up and was followed by appropriate tooth preparation. Due to the original prominence of these teeth, extensive dentin exposures could not be avoided, which required the use of IDS.

## IDS

Despite a major effort to confine the preparation to the enamel shell, peculiar situations such as initially prominent or misaligned teeth (Figs 6-45 and 6-46) may still involve deeper preparations reaching dentin. This should not constitute a limitation in the use of BPRs. Whenever a substantial accessible area of dentin has been exposed by the preparation, local application of a dentin bonding agent (DBA) is recommended. Previous approaches to dentin bonding consisted of ignoring the dentin exposure and delaying the application of the DBA (eg, acid etching followed by the application of the primer and bonding resin) until the last treatment stage, when proceeding to delivering the veneer. With such an approach, to avoid incomplete seating of the restoration, it was usually recommended that the adhesive resin be kept unpolymerized when seating the veneer. It was established, however, that the pressure of the luting composite during the seating of the veneer created a collapse of demineralized dentin (collagen fibers) and subsequently affected the adhesive interface cohesiveness.[29,171,172] For this reason, an original approach was proposed to optimize the DBA application—the immediate dentin sealing or IDS technique—which is extensively described and explained in chapter 4 (section 4.4).[29,37,95,96,173–176]

**FIG 6-44 Intrasulcular margin for optimal interdental closure.** Intrasulcular margins *(center)* allow not only for optimal interdental closure but also for improved emergence profile compared to supragingival margins *(right)*. The gingival fiber apparatus is not negatively affected by such modification of the interdental design when an intrasulcular interdental margin is used,[38] and a long-term esthetic success can be established. Additive luting (explained on pages 756-757) is an important adjunct technique that can be used to compensate for interdental preparations not extending/wrapping enough toward the linguogingival interdental area (see Fig 6-83).

**FIG 6-45 Combined indications for BPRs: biocorrosion and closure of unsightly black triangle.** *(a to d)* Initial treatment of this case included graft-type interventions (detailed in chapter 5, Fig 5-3) followed by the realization of study casts, a wax-up, and a basic mock-up to compensate for tooth aging, cracking, chipping, and thinning of enamel as well as to reduce the black interdental triangle between the central incisors. The patient immediately accepted the treatment proposal with veneers. *(e and f)* Facial axial reduction was carefully controlled using a "notebook" type silicon index. *(g)* Due to the proximity of the preexisting metal-ceramic crown, safe interdental finishing of tooth preparations was achieved with half-torpedo oscillating diamond tips, which are also extremely useful to generate smooth and low-trauma intrasulcular margins. Due to the existing prominence of the central incisors and thin residual enamel, extended dentin exposures were unavoidable.



t.me/Dr_Mouayyad_AlbtousH

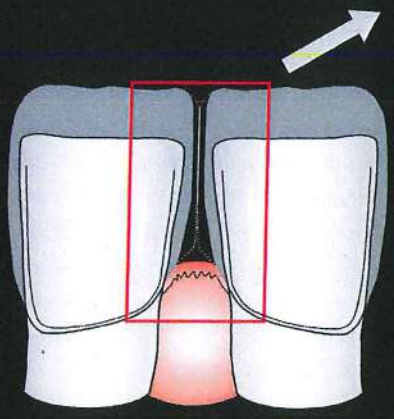

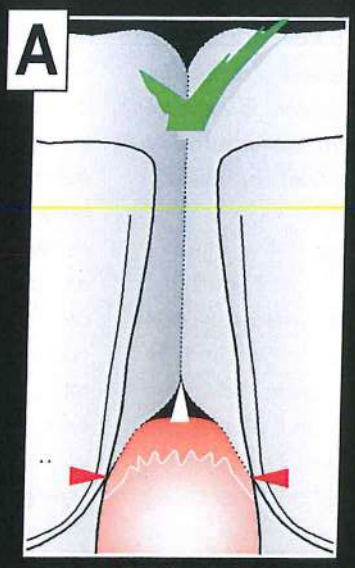


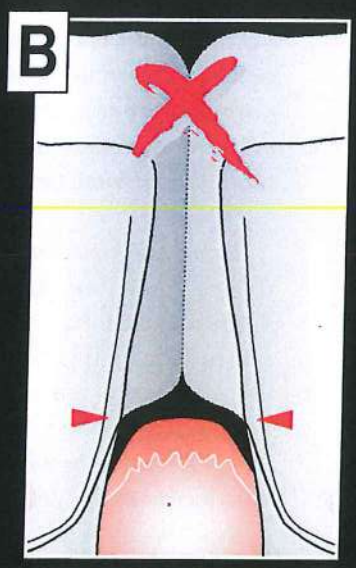


6-44

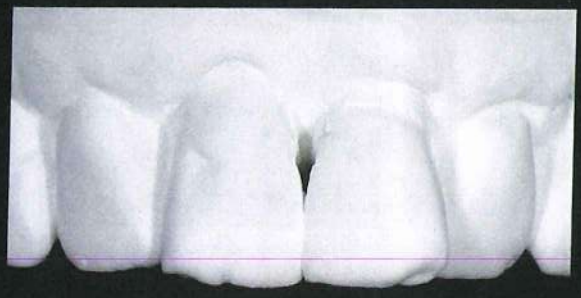

6-45a



6-45b



6-45c



6-45d



6-45e



6-45f



6-45g



t.me/Dr_Mouayyad_AlbtousH

***Because the DBA appears to have a superior potential for adhesion when applied to freshly prepared dentin, its application is recommended immediately after the completion of tooth preparation, before the final impression.***

There are more than 20 reasons to use the IDS technique (see chapter 4, Fig 4-17 and Table 4-4); above all, this precautionary measure seals and protects the pulpodentinal organ and, by the same token, prevents sensitivity and bacterial leakage during the provisional phase. The use of a filled adhesive resin (eg, OptiBond FL, Kerr) facilitates this procedure. Additional curing of the DBA through a layer of glycerin jelly is recommended, followed by gentle pumicing to remove the oxygen inhibition layer and prevent interaction of the dentin adhesive with the impression material. ***In the presence of gingival margins in dentin, a marked chamfer is recommended to provide adequate margin definition and enough space for the adhesive and overlying restoration (Fig 6-45m).*** Magnification instruments (loupes with minimum 6.5× or operatory microscope) significantly help to accurately place the adhesive and remove eventual excess of resin from the margin. Further adhesion of the luting agent to the preexisting adhesive layer must be promoted by surface roughening (see luting procedures in Fig 6-78).[29]



6-45h



6-45i



6-45j



6-45k



6-45l

**FIG 6-45** *(cont) (h)* Extended dentin exposures require IDS (before final impression), starting with etching of the sclerotic cervical dentin (35% phosphoric acid), which requires an extended etching time of 20 to 30 seconds. *(i)* The remaining dentin was etched for only 10 to 15 seconds. *(j and k)* After rinsing and evacuation of the excess water, a hydrophilic monomer (OptiBond FL, Primer) was applied by a gentle light brushing motion followed by suction of the excess solvent (note the resin-saturated dentin with glossy appearance). *(l)* A thin coat of filled adhesive resin (OptiBond FL, Adhesive) was applied and cured. Use of a periodontal probe allows careful and accurate placement. To avoid interaction with the impression material, the surface of the adhesive layer must be devoid of the inhibition layer; additional polymerization after covering the adhesive with glycerin jelly (not illustrated here but in Fig 6-46) followed by soft pumicing is recommended. Note the intrasulcular margin at the mesial aspect of both central incisors. The same IDS procedure was subsequently applied to the other central incisor.



t.me/Dr_Mouayyad_AlbtousH

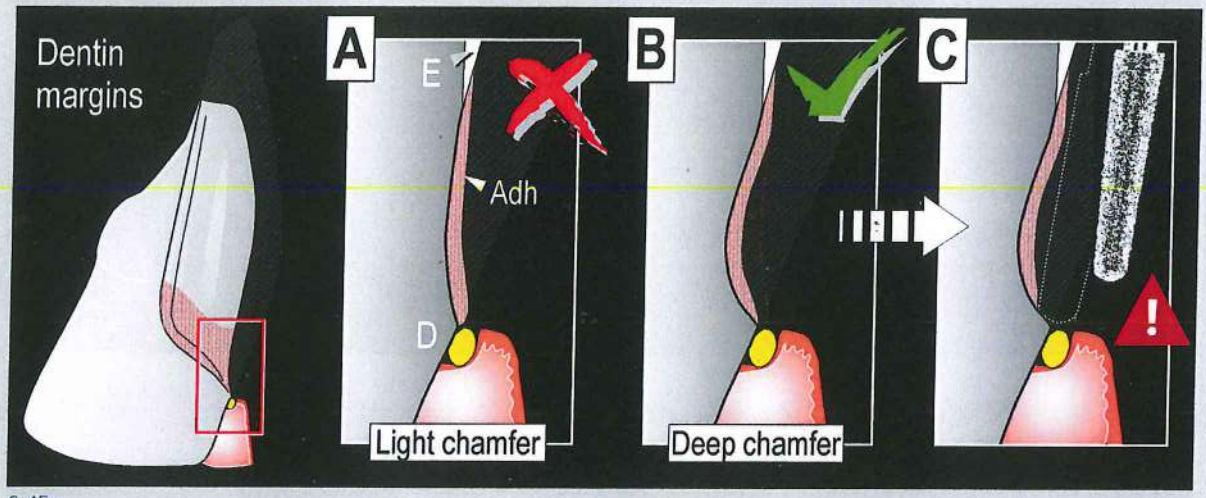


6-45m

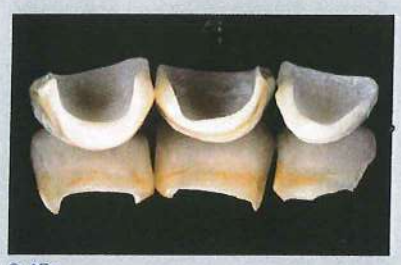

6-45n



6-45o



6-45p



6-45q



6-45r

**FIG 6-45** *(cont) (m)* Schematic cross-sectional views of gingival dentin margins (D) with deflection cord in place *(yellow)*. E, residual enamel. IDS is not possible in the presence of a traditional light chamfer *(center left)* because the adhesive layer (Adh) tends to pull over the margin, creating a feather-edge finish line and insufficient margin definition. IDS can be easily carried out in the presence of a marked chamfer *(center right)* because application of the adhesive can be confined to the prepared surface and leaves sufficient space for the restoration. In case of excesses, the resin can be removed ~0.5 mm from the dentin perimeter with fine-grain diamonds *(right)*, but this re-exposes dentin ⚠, which will require proper conditioning of the preparation margin (etching, primer) during restoration delivery. *(n and o)* The intrasulcular margins allowed the use of interdental miniwings to close the black interdental triangle. *(p)* Opaque porcelain of a higher chroma was used in the interdental and cervical areas. Simulation of the root portion is also possible with porcelain veneers, which was essential to the esthetic outcome of this case. *(q and r)* The before-and-after views of the smile emphasize the esthetic and functional rejuvenation of the smile through recovery of the enamellike shell, which enhances color, crown shape, and length. Due to IDS, those veneers were clinically successful for over 10 years despite the major dentin exposure (see chapter 5, Fig 5-3i).[32]


t.me/Dr_Mouayyad_AlbtousH



6-46a



6-46b



6-46c



6-46d



6-46e



6-46f



6-46g



6-46h

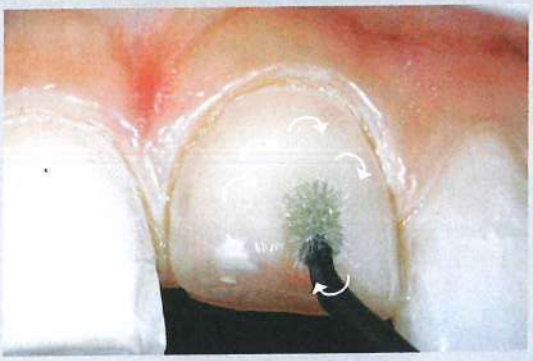

6-46i

**FIG 6-46 IDS of preparation and medium-term follow-up of type IIIA veneer.** This case of trauma was originally treated with fragment reattachment on the right central incisor (visible in *a*) and direct composite resin on the left central incisor. Veneer preparations were finished with beveling of the sharp labioincisal line angle *(b)*, the placement of a conservative chamber *(c)*, and final softening of all transition angles with oscillating tips *(d)* and flexible disks *(e)*. There was a major dentin exposure of the labial surface on the left central incisor, which required IDS. First, the exposed dentin was freshly cut with a coarse diamond *(f)*, then etched for 10 seconds *(g)*, rinsed, and gently dried *(h; arrows* outline the dentin area) before application of the primer *(i*, OptiBond FL) with gentle circular brushing motion for at least 20 seconds (several applications preferred).


t.me/Dr_Mouayyad_AlbtousH



6-46j

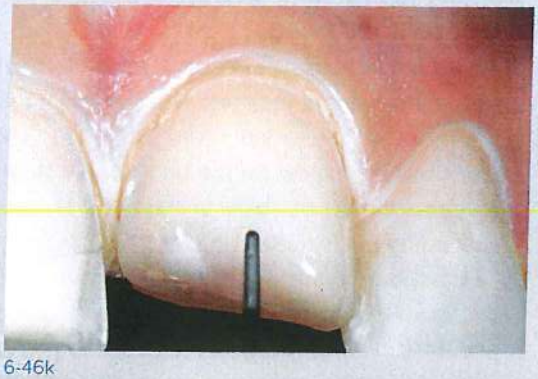

6-46k



6-46l



6-46m



6-46n



6-46o



6-46p




6-46q

**FIG 6-46** *(cont) (j)* Note the moist dentin surface (shiny but without moving film of fluid) following gentle air/suction drying (the texture left by the diamond bur must be visible). *(k and l)* The adhesive resin is carefully placed and distributed with the tip of a periodontal probe, followed by polymerization *(m,* twice for 10 seconds each to avoid heating of the pulp), placement of glycerin gel *(n,* air-blocking), and polymerization again *(o,* 10 seconds). *(p)* Final preparations with double retraction cords before final impression. *(q)* Postoperative view 3 years later. Note the direct Class 4 composite resin restoration (also in 3rd year of clinical service) on the mandibular left central incisor (overlay image of preoperative situation; see details in chapter 3, Fig 3-41). (Reproduced with permission from Magne and Magne.[25])



t.me/Dr_Mouayyad_AlbtousH

### "Internal" miniwing

Figure 6-47 depicts a case of inverted morphology of the central incisors: The cervical width is larger than the incisal width (Fig 6-47a). The mock-up, fabricated on the unprepared teeth, revealed the impossibility to invert this tapered shape (Fig 6-47b; notice the rectangular central incisors) due to the underlying cervical enamel volume. However, following tooth preparation, enough clearance was given at the mesiogingival and distogingival aspects of the central incisors (Figs 6-47c and 6-47d) in order for the ceramist to be able to design a recessed (flatter than the original contour of the tooth) and flat triangular interdental surface. These mesial and distal internal miniwings were slightly colored to increase saturation. ***The combined effect of shape and color allowed the line angles to be optically moved and the natural taper of those teeth to be restored (Figs 6-47e to 6-47g).***



6-47a



6-47b



6-47c

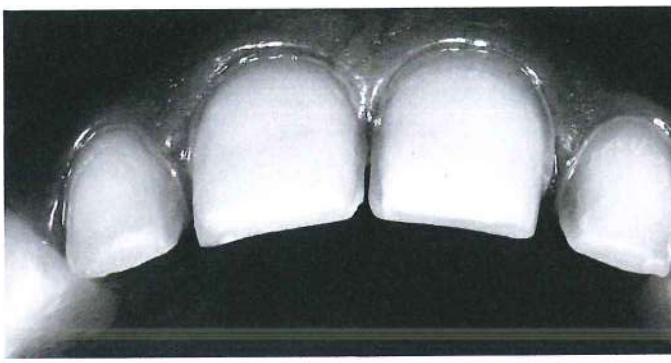

6-47d

**FIG 6-47 Inverted taper of central incisors corrected by internal miniwings.** *(a)* This patient presented with inverted tooth taper of her central incisors. *(b)* Following wax-up and mock-up, the patient was satisfied, but the tooth shapes are still very rectangular due to the wide existing cervical perimeter. Direct composite restoration could have been selected, but the patient requested the use of high-end porcelain restorations. *(c and d)* Following tooth preparation for four veneers on her maxillary incisors, it was possible to obtain a recessed triangular surface at the mesial and distal gingival aspects of the porcelain veneers (especially visible at the mesial surface in e). *(f and g)* The final veneers display a beautiful triangular tapered shape despite the wide root base. The optical illusion is given by the shape and color of the internal miniwings *(yellow in overlay image)*. Canine tips were also lengthened with direct composite resin. (Case treated in collaboration with Dr Joseph Hannah; reproduced with permission from Magne et al.[56])



t.me/Dr_Mouayyad_AlbtousH

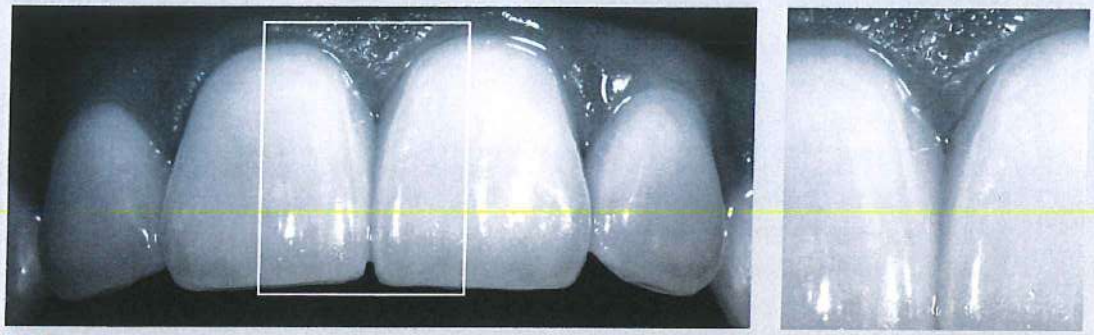

6-47e



6-47f



6-47g



t.me/Dr_Mouayyad_AlbtousH

# 6.10 DEFINITIVE IMPRESSIONS

Because of the margin accessibility (usually favorable for BPRs), final impressions or scanning with an intraoral system should not present a major challenge. Precise tooth preparations and adequately conditioned gingival tissues are paramount for both analog and digital workflows.

The advantages of optical impressions and the digital workflow have been discussed in chapter 4 (section 4.2). The advantages of the analog approach may be substantial depending on the fabrication technique that will be selected for the anterior BPRs. When using artisanal methods, such as the most acclaimed and sophisticated refractory die–generated veneers (artisanal full-layering process, see section 6.12), the analog process will be more suitable; special working models are needed, especially the refractory dies, which cannot be 3D-printed yet. A "one-step, double-mix" impression technique[177–179] (Fig 6-48) will provide appropriate reproduction of the preparations and surrounding tissues. Addition silicone materials (polyvinyl siloxanes [PVS]) are recommended due to their broadly recognized elasticity and resistance to tearing; they also provide dimensional stability and accuracy for multiple pours, which will be essential to the fabrication of adequate master models (see section 6.12).[178,180]

## Gingival deflection

Accurate reproduction of the surrounding soft tissues in the final impressions is imperative, as it will help the ceramist in the optimization of tooth shape and contours. As is the case when placing finish lines, an atraumatic gingival deflection method is essential.[179,181] The use of deflection cords (devoid of adrenaline impregnation), induces the least clinical damage to the periodontal tissues compared to other methods.

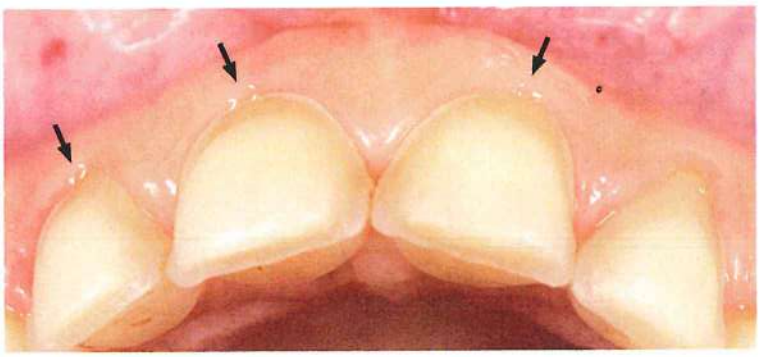

6-48a

**FIG 6-48 Conditioning of the gingiva before analog/digital impressions.** *(a)* Clinical view following tooth preparations: Crevicular fluid contaminates the preparation margins *(arrows). (b to e)* High-quality impressions are possible when a compression cord (here surgical suture 2-0) is placed to seal the bottom of the sulcus. Individual compression cords are placed, one per tooth from the mesial to the distal aspect. The second cord is placed over the compressive one; it is larger but also more superficial (here Gingibraid 0a, Kerr). *(f)* Use of two instruments (bimanual technique combining a periodontal probe and a spatula) facilitates the insertion with low forces. *(g)* The packing must remain in place and be allowed to absorb water for about 5 minutes to generate some expansion of the superficial cord. Excess moisture is eliminated just prior to taking the impression. *(h)* The deflection cord should be single and continuous on several teeth.



t.me/Dr_Mouayyad_AlbtousH

## I. COMPRESSION CORDS

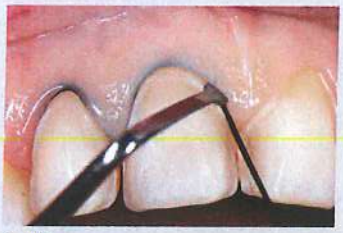

6-48b

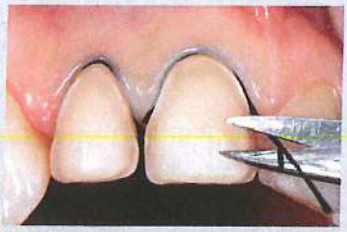

6-48c



6-48d

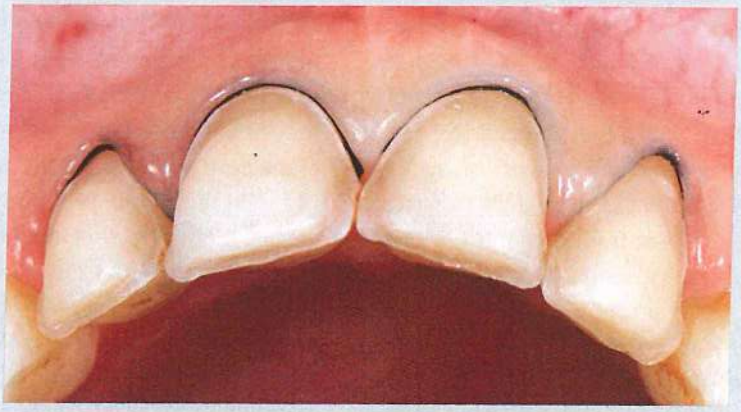

6-48e

## II. DEFLECTION CORD

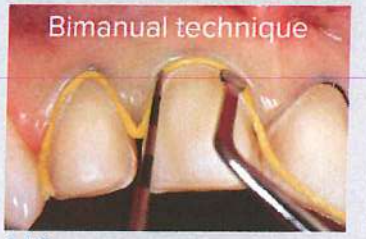


6-48f




6-48g



6-48h



t.me/Dr_Mouayyad_AlbtousH

The preexisting cord (used during tooth preparation) is removed and replaced by a new and definitive packing (Figs 6-48a to 6-48h). A systematic approach using two cords is recommended.[182]

**A compression cord of small diameter** (eg, surgical suture 2-0 or Gingibraid 0a, Kerr) is first inserted in the bottom of the sulcus. This cord will remain in place during impression taking, thus "sealing" the sulcus and limiting the flow of crevicular fluid. **A more superficial deflection cord** (eg, Gingibraid 0a or 1a, Kerr) is then inserted in the entrance of the sulcus with the bimanual technique (Fig 6-48f). Unlike the compression cord, a single deflection cord can be used for multiple preparations (Fig 6-48h). Gingival deflection must be carried out at least 5 to 10 minutes prior to impression taking, allowing the deflection cord to expand by water sorption.

***When IDS has been previously applied, the adhesive resin inhibition layer must be completely removed from the surface of the tooth to avoid interaction with the impression material[183,184]; additional light curing after covering the adhesive with glycerin jelly (air-blocking) and gentle rubbing with pumice are required and will result in successful PVS impressions.[183]*** This treatment, however, will not prevent polyether materials from adhering to the IDS resin coating, making them contraindicated unless the IDS is covered with additional composite resin (regular or flowable).[185]

## One-step, double-mix impression

In the "one step, double-mix" impression technique, the deflection cord is removed, immediately followed by injection of a light-body material and insertion of the tray loaded with a more viscous material (Figs 6-48i to 6-48q). Due to the viscoelastic behavior of gingival tissues, they remain temporarily deflected after removal of the cord (Fig 6-48r), which allows penetration of the light-body impression material into the sulcus, slightly beyond the preparation margins (Figs 6-48s to 6-48u). Either commercial or individual trays are compatible with the technique. Individual trays, however, offer more accurate intraoral positioning, require less heavy-body material, and facilitate fabrication of the master cast in the laboratory.

> Whether for analog or digital impressions, the initial clinical steps regarding the soft tissue deflection (see Figs 6-48b to 6-48h) can be applied similarly.

**FIG 6-48** *(cont)* **One-step, double-mix analog impression.** *(i)* Cross-sectional schematic view of clinical situation with double cord packing. *(j)* During impression taking, sequences 1, 2, and 3 are carried out rapidly: The deflection cord is removed, and a fluid impression material *(blue)* is immediately injected into the sulcus. The entire preparation is then covered with the light-body material and air-blown before insertion of the tray, which has been loaded with a more viscous mass *(purple)*. The corresponding "dynamic" clinical sequence is described in *k* to *q*: The same operator can simultaneously remove the deflection cord and then inject the light-body material *(k to n)*. *(o)* Insertion of the tray is preceded by gentle air-blowing of the low-viscosity material. *(p and q)* The entire procedure is carried out with lip retractors in place. *(r)* The purpose of this technique and the viscoelasticity of the soft tissues are illustrated by the clinical view just following retrieval of the tray: The gingiva is still well deflected, and the compression cord maintains a dry sulcus. *(s and t)* The impression demonstrates accurate reproduction of preparations and margins as well as the absence of blood or moisture. *(u)* Magnified view of the impression cross section around the left central incisor. Provisional restorations of this case can be seen in Fig 6-53. (Patient treated in collaboration with Dr Nikolaos Perakis, Bologna, Italy.)



t.me/Dr_Mouayyad_AlbtousH

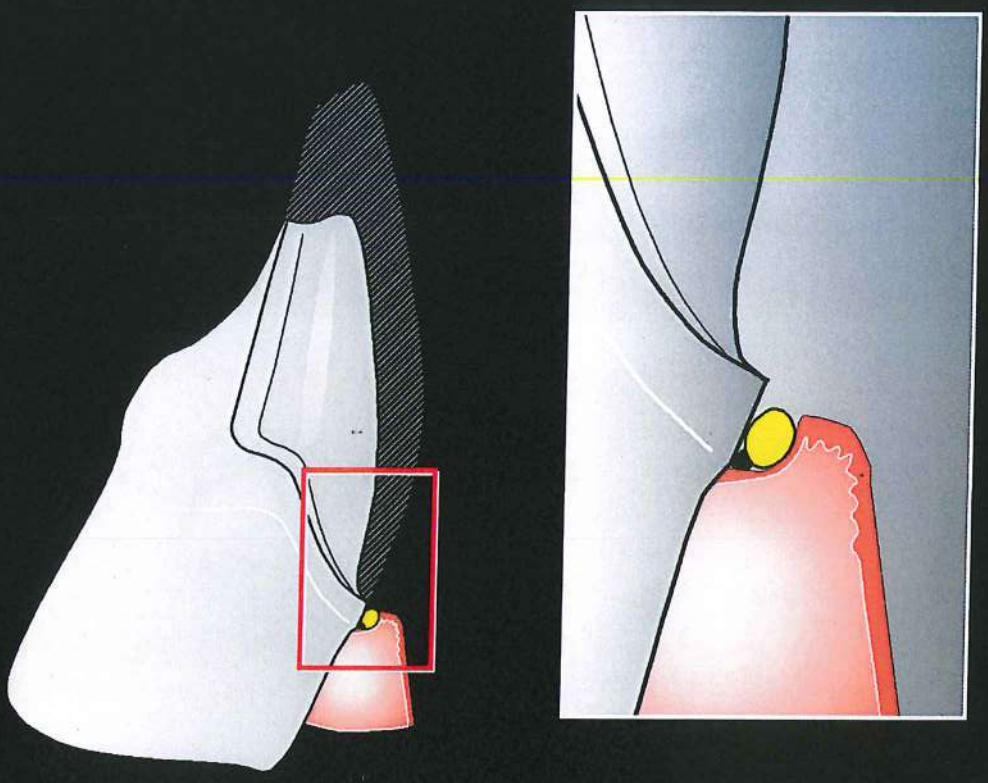

6-48i

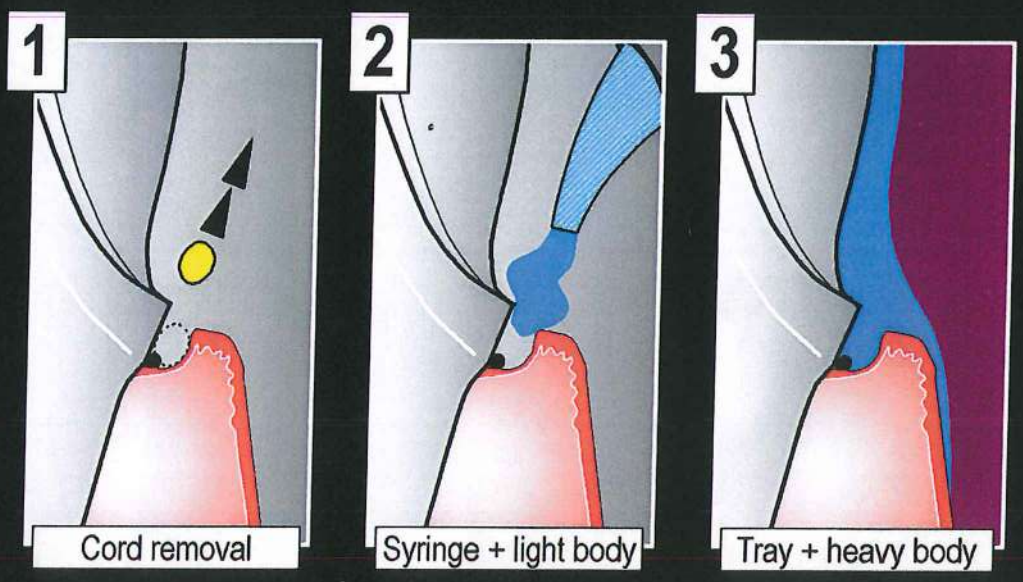


6-48j



t.me/Dr_Mouayyad_AlbtousH



6-48k

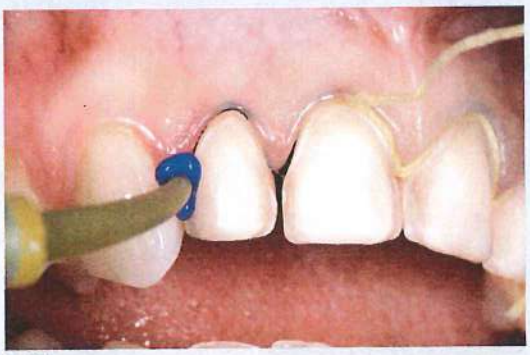

6-48l



6-48m



6-48n

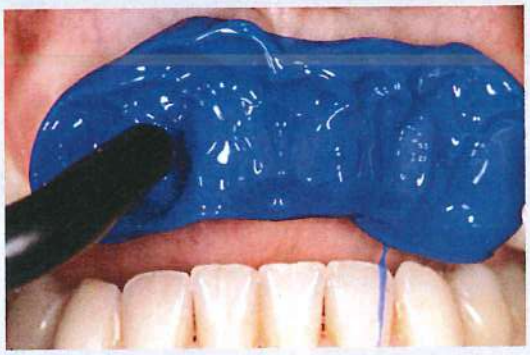

6-48o



6-48p

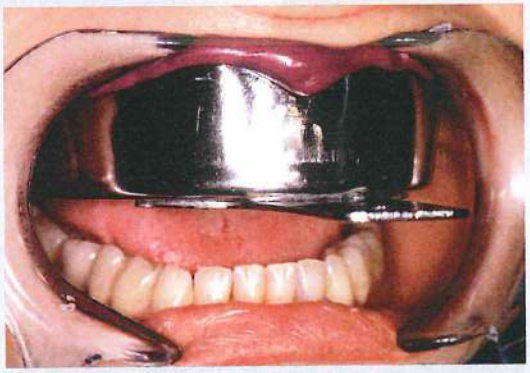

6-48q

Fig 6-48u

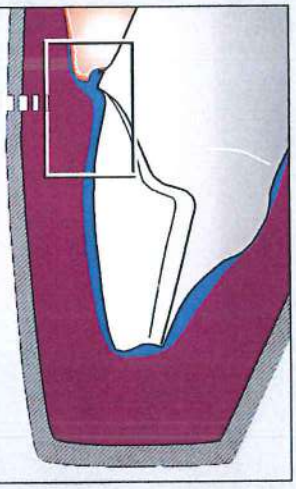



t.me/Dr_Mouayyad_AlbtousH

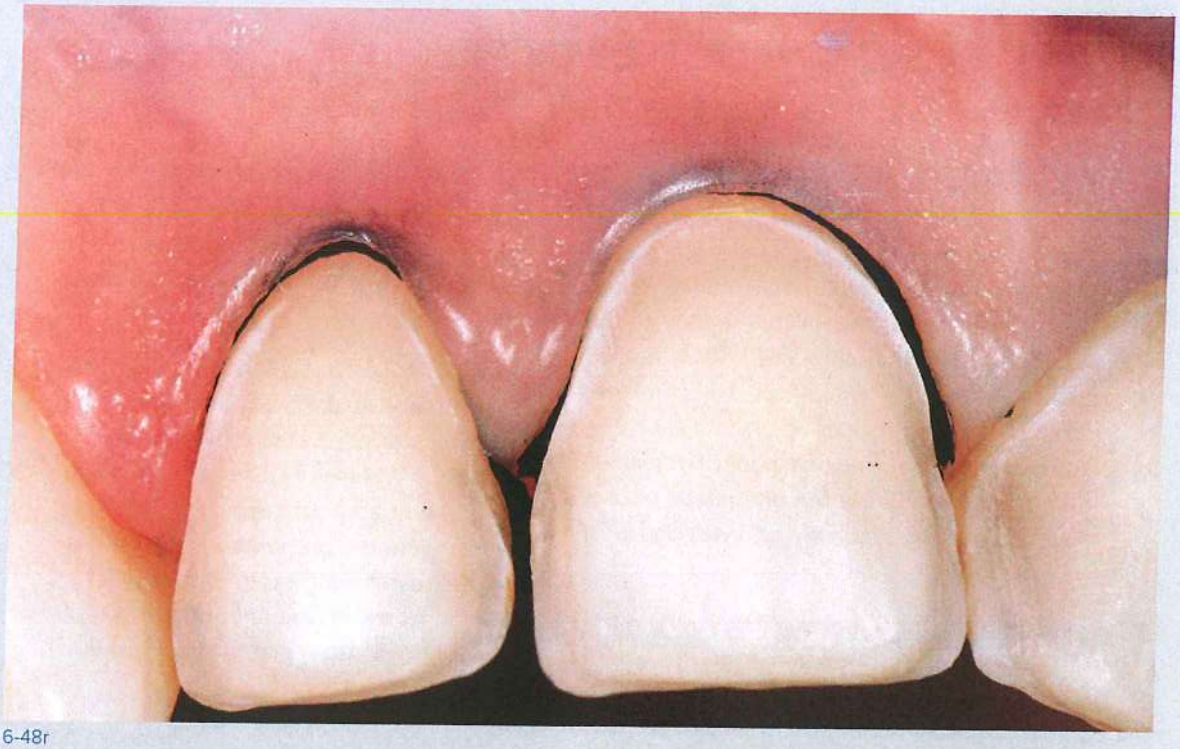

6-48r

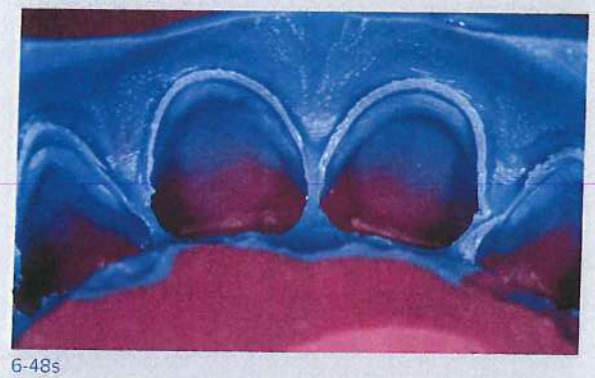

6-48s



6-48t



6-48u



t.me/Dr_Mouayyad_AlbtousH

# 6.11 PROVISIONAL RESTORATIONS

## Fabrication techniques

Provisional restorations can be fabricated with the same technique and materials as the mock-up (ie, using the silicone matrix of the wax-up loaded with autocure PMMA applied intraorally to the preparations until complete setting of the resin (see all details in section 5.6). ***Whenever the mock-up was significantly modified intraorally during the diagnostic phase, new silicon indexes from the edited design must be generated.***

***Similarly to the mock-up, use of bisacryl and composite resins is not recommended because of their brittle behavior. PMMAs, with their elastic and favorable handling properties, constitute optimal materials to be used as provisional restorations.***

There are various ways to generate provisional veneers, involving different fabrication times and esthetic outcomes. The more sophisticated methods require the combined use of dentinlike and enamellike acrylic resins (Fig 6-49). The widely recognized Vita shade guide can be used to select the right dentin core material (eg, New Outline A2 dentin, Anaxdent). Enamellike PMMA must not have specific shades; transparent (eg, New Outline, Transpa Clear) and "milky" translucent resins (eg, New Outline, High Value) can be combined to achieve different opacities. The previous dentin target shade of the mock-up can be modified based on the patient's feedback during the diagnostic phase. See Table 5-4 for a complete description of the possibilities offered when combining the different masses.

It should always be anticipated that the glazing of the PMMA will result in a loss of ½ to 1 shade (eg, A2 becomes A3), especially when using thick glazing resin with camphorquinone initiator.

> All the technical/material aspects discussed for the mock-up in chapter 5 apply similarly to the provisional restorations. Whenever IDS has been applied, however, abundant application of Vaseline onto the preparations (as well as the neighboring teeth and gingiva) is mandatory to prevent adherences of the PMMA to the resin coating (Fig 6-50).

Many application modes of the resin are possible. In the **one-step, double-mix technique**, a small amount of a translucent/transparent mixture is first poured into the incisal edge of the silicon index. It is immediately covered with a second mixture of dentinlike material and pressed over the teeth. This one-step method is simple and not time-consuming and can generate provisional restorations with some degree of translucency that gradually increases toward the incisal edge.

The **one-step, single-mix technique** is the most convenient (Fig 6-50); a single amount of dentin acrylic resin is mixed, loaded to the silicon index, and applied to the teeth. The powder content can consist of 100% dentinlike resin (cases of discolored teeth) or include 10% transparent/translucent resin for a more chameleon-type effect. This method always results in a restoration with uniform shade and opacity. However, **additional paint-on colors and glazing** can produce a very favorable esthetic outcome (see coloring technique in chapter 5, Figs 5-10 and 5-12).



t.me/Dr_Mouayyad_AlbtousH




**FIG 6-49 Basic PMMA materials required for esthetic provisional restorations.** Highly esthetic provisional restorations can be achieved using PMMA resins (New Outline). Mock-ups and provisionals mainly require dentinlike core PMMA *(top left)*. Incisal resins *(top center and top right)* can be used as modifiers (see possible mixes in Table 5-4). When using the cutback technique (see Fig 6-51), various aspects of the incisal edge are obtained by mixing different ratios of transparent and translucent incisal powders: 50%/50% for an average tooth and 70%/30% for a young transparent incisal edge. The dentinlike resin core features standardized colors based on the Vita shade guide. Skin Glaze (Anaxdent) is a low-viscosity clear light-polymerizing resin to seal the surface of PMMA and composite resin restorations.



t.me/Dr_Mouayyad_AlbtousH



6-50a



6-50b



6-50c



6-50d

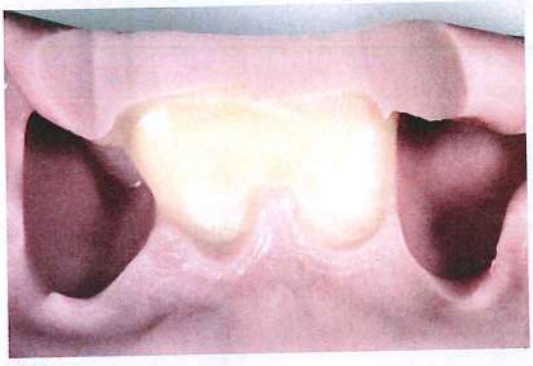

6-50e

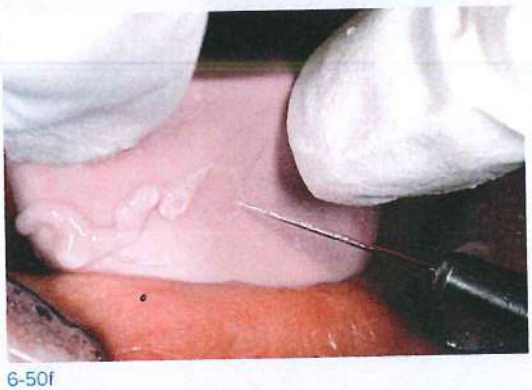

6-50f

**FIG 6-50 Shrink-fit provisional veneers fabricated with a one-step, single-mix technique.** *(a)* This patient presented with damaged mandibular central incisors: The right central incisor is endodontically treated and cracked, and the left central incisor shows a large area of enamel-dentin chipping. The patient demanded that those teeth be restored with porcelain veneers. *(b)* The preparations wrapped the incisal edge and proximal surfaces and required IDS (clinical view during polymerization of the resin coating through glycerin gel). *(c)* The large IDS surface involves the incisal edge and most of the labial surface (a small amount of additional composite resin was applied to the left incisor). *(f)* Following final impressions, a provisional restoration must be fabricated; however, the PMMA will likely adhere to the IDS surface unless a thick layer of Vaseline is applied *(d*; note also the blue periphery wax applied to the linguocervical embrasure between the teeth). *(e)* A PMMA dentin mixture is applied to the silicon index and left until dull before being pressed over the preparations. *(f)* The operatory field is water-cooled to limit the exothermic reaction. Note the thin film of polymerized PMMA over the gingiva *(g)*, which is easily peeled off *(h)*. The lingual margins are adjusted with a large steel bur *(i)*, and the crack line was simulated with brown color *(j)*, polymerized *(k)*, and sealed with Skin Glaze *(l*, clinical view during postpolymerization through glycerin gel). *(m)* Some coloring was added interdentally to simulate the natural staining of neighboring teeth. The porcelain veneers were then fabricated and delivered. *(n and o)* Clinical view after 5 years of uneventful clinical service.


t.me/Dr_Mouayyad_AlbtousH



6-50g



6-50h



6-50i



6-50j



6-50k



6-50l



6-50m




6-50n




6-50o



t.me/Dr_Mouayyad_AlbtousH

The **two-step, double-mix technique** (Fig 6-51) is a sophisticated way to fabricate provisional veneers but is also time-consuming and more adapted to an indirect approach (laboratory provisionals). In this technique, a uniform dentin mixture is applied to the silicon index, which is pressed over the preparations. The incisal edge is then cut back to reproduce the histoanatomy of dentin. Light-polymerizing colorants can be applied to the dentin core (alike the natural layering technique for direct composite resin) to simulate incisal characteristics (blue-lavender incisal effect, crack lines, white spots, etc). The silicon index is then loaded again, this time with a translucent/transparent mixture, and pressed over the characterized dentin core. This technique corresponds to the intraoral application of the laboratory sandwich technique and can result in extremely sophisticated provisional restorations.

## Glazing

***With the introduction of glazing resins (eg, Skin Glaze, Anaxdent), it is no longer necessary to mechanically polish the provisional restorations.*** For multiple connected restorations, the glazing resin can be mixed with brown colorants to infiltrate the connection areas (see effect in Fig 6-50m), optically "separating" the splinted provisional restorations and enhancing the esthetic outcome. The color of the restorations can be modulated by the thickness of the glazing resin: Thicker layers tend to produce more saturation, due to the presence of camphorquinone in the glaze.




**FIG 6-51 Provisional veneers made with a sandwich technique.** *(a)* Tooth preparations, neighboring teeth, and soft tissues have been isolated with Vaseline. The silicon index is first loaded with dentinlike PMMA *(b and c)* and pressed over the preparations until curing is complete *(d)*. *(e)* Areas that will be cut back are marked with a pencil. *(f)* A rough diamond bur is used at low speed (without water spray) to shape the incisal edge into a histoanatomical dentin core. *(g)* Incisoproximal embrasures are reduced with an abrasive disk and a scalpel. Incisal effects, white spots, and craze lines can be painted onto this dentin core using photopolymerizing stains (not used in this case). After the surface of the cut-back resin is wet with monomer liquid, the silicon index is loaded with transparent/translucent mixture *(h)* and pressed intraorally over the preexisting dentin core until curing is complete *(i)*. *(j and k)* Clinical views of sandwich provisional veneers after glazing. The diagnostic approach and final restoration of this case are illustrated in chapter 5, Fig 5-4. *(l)* Another case of two provisional veneers on both central incisors, which have been fabricated in a two-step, double-mix sandwich technique. Interarch relationships allowed the provisional to be extended above the palatal preparation margin *(arrowhead)*, which enhanced the primary stability and locking of the restorations. *(m and n)* Distinct effects have been obtained as a result of the contrast between dentin and incisal shades.



t.me/Dr_Mouayyad_AlbtousH



6-51g




6-51h



6-51i



6-51j



6-51k



6-51l



6-51m



6-51n



t.me/Dr_Mouayyad_AlbtousH

## Shrink-fit locking vs cementing vs spot-bonding provisional restorations

Whenever possible, it is preferred to fabricate the entire provisional restoration intraorally in one segment over the isolated preparations.

***Complete intraoral fabrication allows splinting and shrink-fitting a group of provisional veneers by spontaneous locking due to intraoral resin shrinkage and the differential preparation insertion axes.***

When proper stability is obtained through the above-mentioned principles, the provisional restoration can only be removed for the final restoration try-in by interdental separation (Fig 6-52), allowing the provisional veneers to be reused and reseated if necessary. In case the provisional restoration must be reused (eg, in the interim due to further modifications of the final restoration), it can be secured with clear temporary cement (Temp-Bond Clear, Kerr; Fig 6-53) and additionally locked with PMMA or flowable resin additions to reconnect the palatal embrasures.

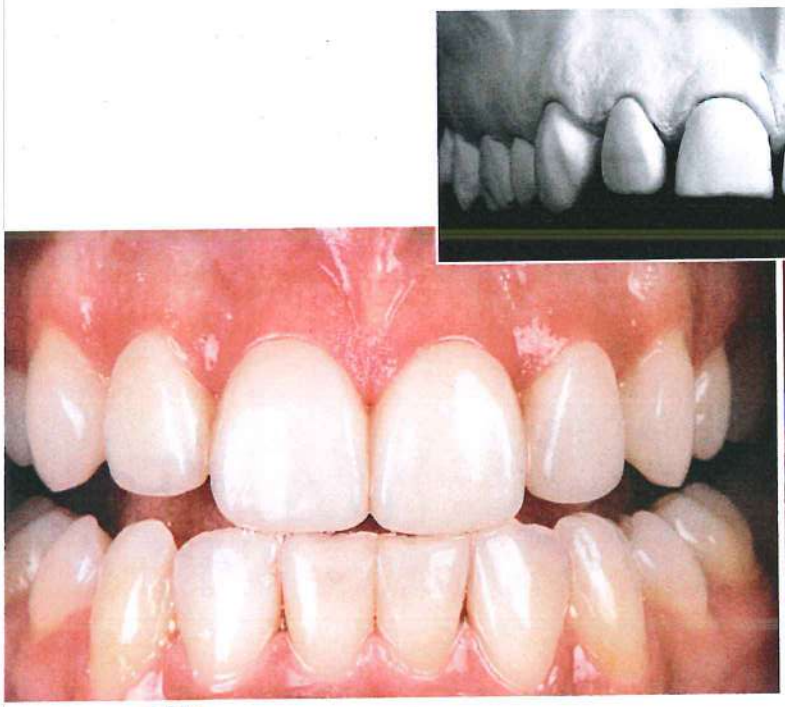

6-52a

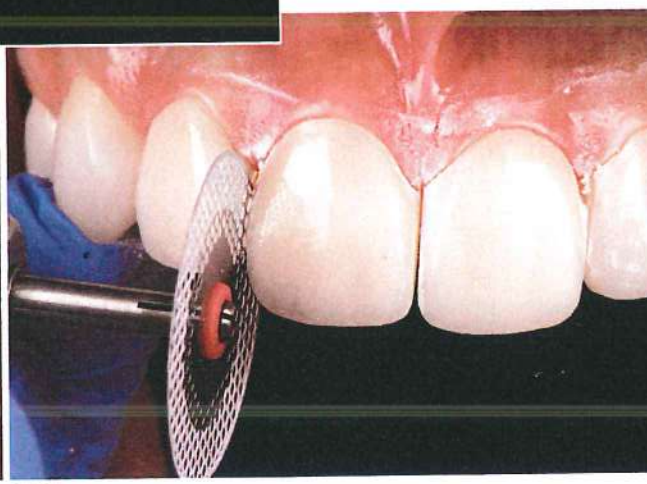

6-52b

**FIG 6-52 Removal of four-unit shrink-fit and locked provisional.** *(a)* The four maxillary incisor provisional veneers are locked by extensive interdental undercuts (minimal tooth preparations in top overlay image). *(b)* They can be removed only after interdental separation with the VisionFlex disk (Brasseler). If needed (after try-in of definitive restorations reveals that modifications must be carried out), they can be reseated on the teeth and reassembled by interdental splinting with PMMA or flowable composite resin. (Part *a* reproduced with permission from Magne.[186])



t.me/Dr_Mouayyad_AlbtousH




6-53a





6-53b



6-53c



6-53d

**FIG 6-53 Provisional cementation.** *(a)* Temp-Bond Clear is a dual-cure, slightly tooth-colored, and translucent cement that is ideal for reseating a used provisional restoration, when necessary (image courtesy of Kerr). *(b)* Clinical view of provisional veneers just before elimination of excess cement. *(c and d)* The translucent temporary cement can ensure a favorable esthetic outcome despite the minimal thickness and relative translucency of provisional veneers. The tooth preparations and final impression of this case can be found in Fig 6-48.



t.me/Dr_Mouayyad_AlbtousH

In the presence of enamel-only preparations, preliminary spot-etching of the enamel and omission of the Vaseline is indicated. In the presence of IDS resin-coated dentin, however, isolation and shrink-fit is the best option. Primary locking of the provisional through interdental undercuts and lingual extensions will provide stability of the restoration for several weeks. In the case of insufficient undercuts (eg, when restoring only two central incisors), locking must be enhanced by the addition of flowable composite resin in the palatal cervical embrasure or on the palatal surface (see Fig 6-51l) or by spot-bonding the interproximal contact with the intact neighboring teeth (from the lingual side). Finally, the most difficult (but also the rarest) situation is fabricating and securing a single central incisor provisional restoration, not only because of the difficulty in color matching the contralateral incisor but also for retention. A solution to these challenges is presented in Fig 6-54.



6-54a



6-54b



6-54c



6-54d

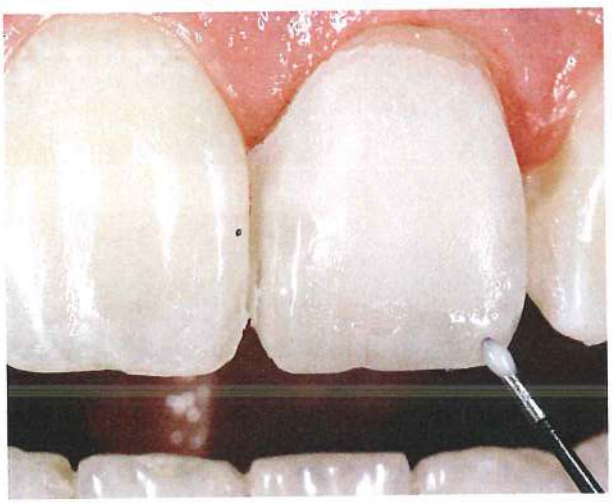

6-54e

**FIG 6-54 Spot-bonding a single central incisor provisional.** This preparation for a type IIIA BPR on the left central incisor *(a)* was isolated with Vaseline and provisionalized with PMMA resin via the one-step, single-mix technique *(b and c)*. The value of the incisal edge was decreased by the application of a gray color wash *(d,* followed by polymerization), and white spots were added *(e,* followed by polymerization) to match those on the right central incisor. *(f)* A glazing resin was applied and polymerized (polymerized again with glycerin gel). The primary stability of the PMMA veneer was insufficient; therefore, it was retrieved, and spot-etching *(g)* and spot-bonding with OptiBond FL adhesive resin *(h and i)* were performed. Special care was taken and a small amount of adhesive was placed with a periodontal probe *(h)* to avoid spreading toward the linguoincisal edge where IDS was applied. *(j)* The provisional PMMA provides outstanding blending and esthetic properties.



t.me/Dr_Mouayyad_AlbtousH

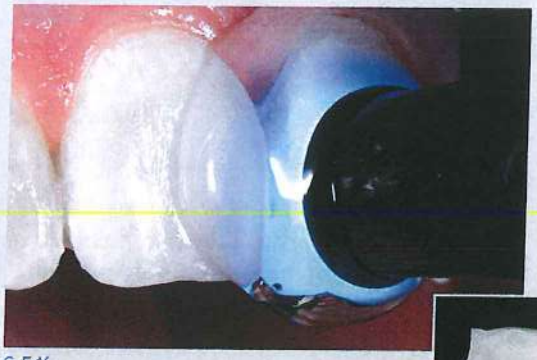

6-54f



6-54g





6-54h



6-54i

## SPOT-BONDING



6-54j





t.me/Dr_Mouayyad_AlbtousH

# 6.12 LABORATORY PROCEDURES

A plethora of laboratory methods have been proposed for fabricating BPRs. This section addresses the choice of the restorative materials and technique as well as the type of master models needed for the most refined approaches. During this final treatment phase, effort essentially focuses on the reproduction of a design that has already been tested and approved by the patient during the diagnostic phase. Only minor modifications are allowed in order to respect what was pledged to the patient.

***Final impressions, whether analog or digital, must therefore be provided to the laboratory along with impressions or digital scans of the latest design (edited mock-up) that was approved by the patient, to be used by the ceramist as a Biocopy reference.***

The patient, clinician, and ceramist will interact for a last clinical try-in of the definitive restorations before proceeding to the final luting procedure, which often completes this clinical session.

## Ceramics: Which one?

Ceramic is not the most affordable material, but it is the most enamellike material when it comes to the replacement of significant amounts of tooth substance, probably because of its ability to simulate and restore crown rigidity.[29,31] Even traditional porcelains such as feldspathic materials are able to compensate for structural tooth weakness. When used in the form of bonded veneers, they can contribute to the recovery of crown biomechanics, including for nonvital incisors.[31] ***The use of tougher ceramics, such as lithium disilicate or even zirconia-based ceramics, is possible but not necessary for BPRs.*** In a clinical trial including long-span incisal edge reconstruction using feldspathic BPRs,[24] the worst failure was represented by an accidental chipping that occurred during a traumatic bite after 1 year of clinical service. The veneer was polished, and no further complications occurred to this patient after more than 7 years of clinical service. In the same study, 12% of teeth displayed cracking, which could justify the use of tougher ceramics. The majority of these postbonding cracks, however, are not necessarily related to the intrinsic material properties but rather errors in tooth preparation (types I4 and F2 designs; Fig 6-55), aluminum oxide airborne-particle abrasion of the porcelain fitting surface (see example in chapter 7, Fig 7-9), insufficient cleaning after hydrofluoric acid etching, and inappropriate bonding (eg, omission of IDS technique). In addition, one should debate to what extent cracking should be considered as a failure in view of the following:

> Cracking is an unavoidable phenomenon in the aging of brittle layered materials. In the case of enamel, cracking proves to be a natural protective process against tensile stresses,[46,187] and even most intact teeth display numerous enamel cracks.



t.me/Dr_Mouayyad_AlbtousH

A crucial role is played by the dentinoenamel junction acting as a "crack-stopper" due to its specific architecture and collagen fiber arrangement (see chapter 1, Fig 1-10).[187] The same can be said about cracked feldspathic BPRs: As long as the bond between the tooth and restoration can survive, the restoration will be preserved, as was the case for six cracked teeth in the aforementioned study.[24] Cases of early failures did not prevent the tooth-restoration complex from still serving optimally for many years. A basic cause for failure is also the excessive invasion of the palatal surface in the form of a long chamfer (I4 design; Fig 6-55).[23]

Additional considerations about cracking and repair of cracked BPRs are presented in chapter 7 (see section 7.4).



6-55a




6-55b




6-55c

**FIG 6-55 Three-year follow-up of palatally cracked veneer.** *(a)* Baseline facial view of porcelain veneers. *(b)* Palatal cracking occurred 2 weeks after placement due to an error in tooth preparation (see explanation in Fig 6-34). *(c)* No evolution of the crack is detected after more than 3 years. The restoration continued to serve without problems for at least 5 years. Repair of a similar crack is presented in Fig 7-12.



t.me/Dr_Mouayyad_AlbtousH

***Crack propensity can be minimized by (1) "soft" preparations (no sharp angles), (2) sufficient thickness of the ceramic material,[62,63] (3) adequate wrapping and design of the restoration,[23,64,166] and (4) thorough cleaning of the porcelain surface following hydrofluoric acid etching.*** *Repair of unesthetic postbonding cracks is always possible and explained in chapter 7 (Figs 7-11 and 7-12).*

It is important to remember that the ultimate tensile strength of feldspathic porcelains, also used in the PFM technique, is two to three times higher than that of enamel (see chapter 1, Table 1-1). Wear properties of dental ceramics represent their most contestable aspect.[188–190] Adequately fired feldspathic porcelains, however, can show significantly less abrasion compared to aluminous porcelain and noncrystalline low-fusing glass.[191] In addition, porcelain veneers might not be the source of significant enamel wear problems because of the conservative nature of the treatment: The palatal and functional side of the tooth is often preserved and left intact. This assumption is consistent with the fact that most clinical evaluations on porcelain veneers and BPRs[9,24,192–195] have not revealed significant wear problems.

## Choice of the fabrication technique

**Porcelain fired over refractory die** is the oldest[196] and the most widespread method to fabricate a porcelain piece. The main advantages of this technique are as follows:

- No special equipment is required.
- Extremely sophisticated effects of color and translucency can be obtained through a full-thickness layering technique (see Fig 6-55a). Selective intrinsic masking is a unique possibility of this technique (see Fig 6-70).
- Traditional feldspathic porcelains can be used; when combined with hydrofluoric acid etching and silanization, they show extremely reliable resin bonding.[197]
- Feldspathic porcelains are also well-known to the ceramist because of the PFM technique.

These advantages are also found in the platinum foil technique, which is the closest alternative to the refractory die technique but requires less effort in model making. Data from the early 1990s[198–200] repeatedly showed the superior marginal fidelity of platinum foil veneers. These results have lost their relevance since the introduction of improved refractory materials and use of smaller individual dies.[201,202]

***Microparticle air abrasion with 25- to 50-µm glass pearls is now used to remove the refractory material from the completed veneers, which also allowed for significant improvements in marginal closures of refractory-derived veneers that can easily approach 40 microns (Fig 6-56).[203]***

The platinum foil technique suffered from the fact that working models had to be prepared by trimming of the gingiva surrounding the margins in order to adapt the foil. Refractory dies, on the other hand, can be seated on a model with intact soft tissues (soft tissue model; see Fig 6-62), which is a major element to guide the stratification and elaboration of fine ceramic contours and emergence profile.

***The complex workflow in the fabrication of stone casts is one of the main criticisms of the refractory die technique (see Figs 6-59 to 6-63), unless printed models are used (see Fig 6-64). As a result, at least two simplified techniques have been proposed to fabricate BPRs: pressed ceramic and machined ceramic.***

**FIG 6-56 Feldspathic porcelain veneers layered over refractory dies.** These veneers *(top)* have been fabricated by layering feldspathic porcelain over refractory material. Marginal fidelity can be excellent, as illustrated by the repositioning of the BPR on its original intact stone die *(bottom)*.



t.me/Dr_Mouayyad_AlbtousH

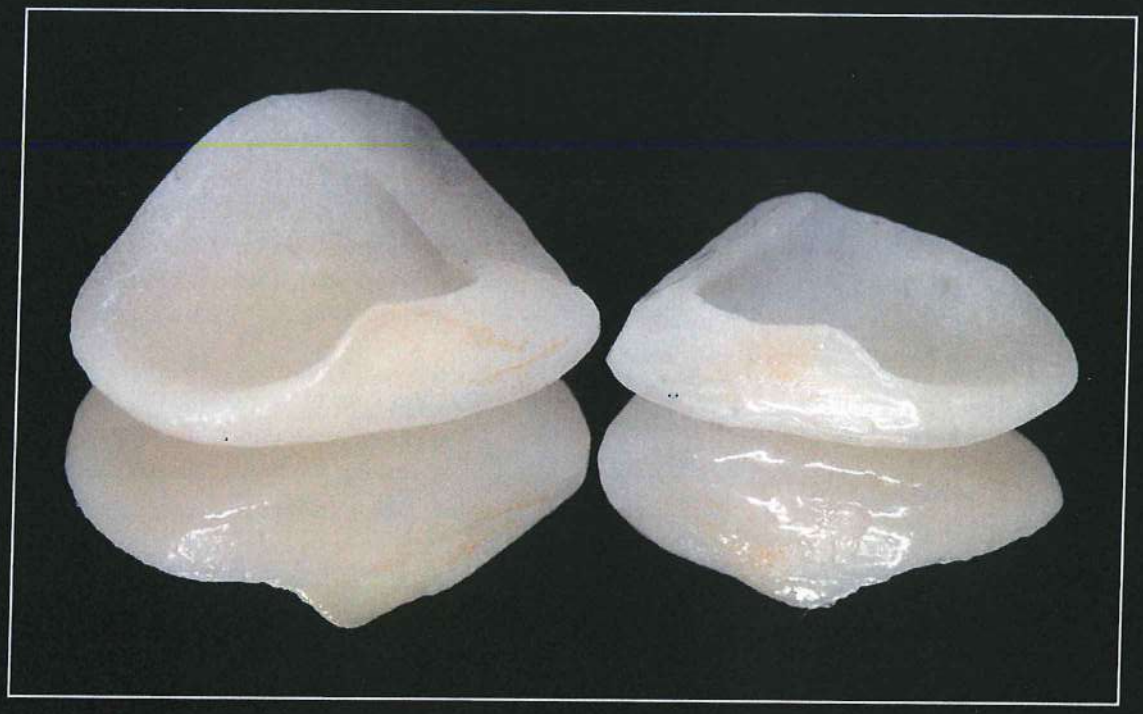



6-56



t.me/Dr_Mouayyad_AlbtousH

### Pressed ceramic[204]

Derived from an original idea to make PFMs in the 1970s,[205] pressed ceramic gained popularity in the early 1990s.[206] Most systems—eg, IPS Empress (Ivoclar, leucite glass-ceramics) and IPS e.max Press (Ivoclar, lithium disilicate glass-ceramic)—offer two elaboration modalities: ***The reinforced pressed glass-ceramics is used to fabricate either the entire restoration or only a core.*** This last option allows esthetic improvements and characterization by additional ceramic firing. Esthetic characterization, however, remains limited compared to the full-thickness layering that can be applied with the refractory die technique.

### Machined ceramic

Unlike pressed ceramics that require first the fabrication of a wax pattern of the restoration and an investment mold for the pressing, machined ceramics are designed digitally. These systems, even though originally intended for chairside use, have become more popular for laboratory use. Resulting BPRs suffer from shade uniformity and rather simplistic anatomy, unless additional porcelain firings are carried out (Fig 6-57).

In both cases (pressed or milled ceramics), the laboratory workflow is much simpler than veneers made on refractory dies, making these techniques much more cost-effective.



6-57a



6-57b



t.me/Dr_Mouayyad_AlbtousH

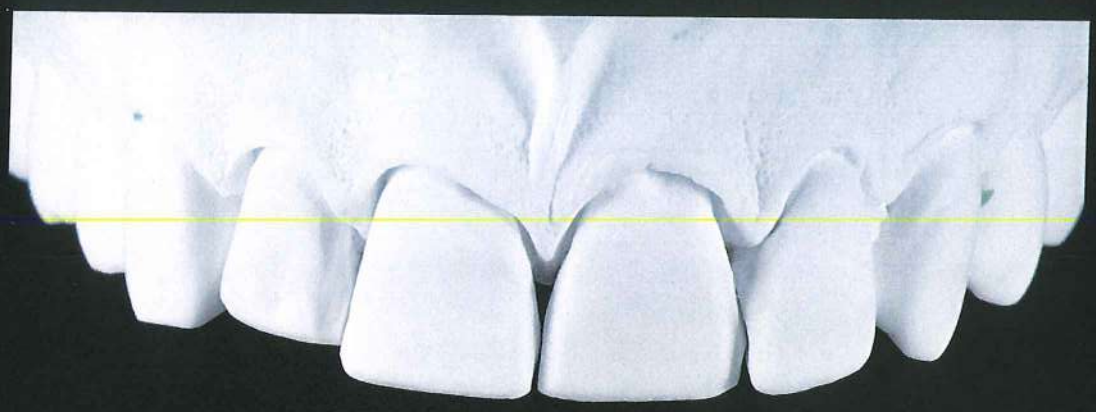

6-57c




6-57d

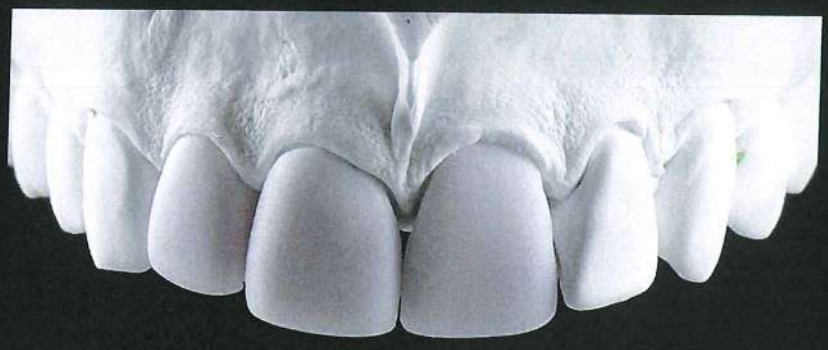

6-57e

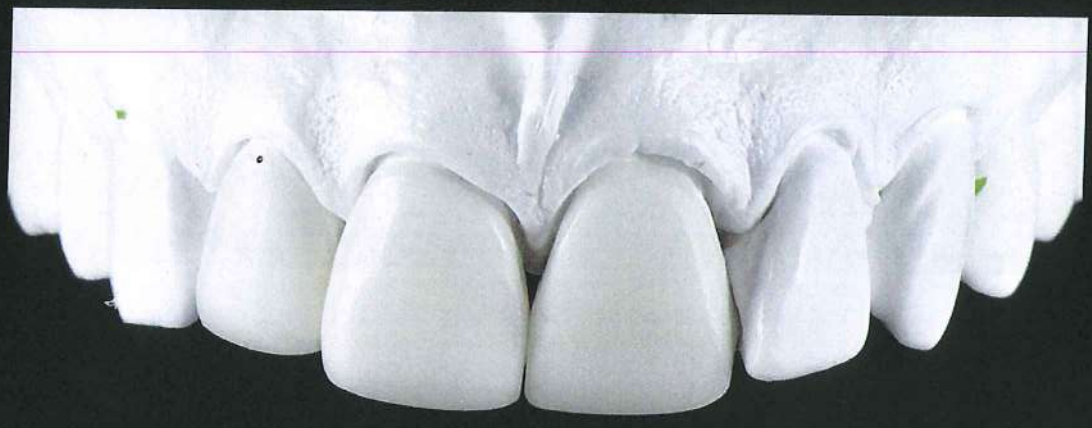

6-57f

**FIG 6-57 e.max CAD glass-ceramic veneers with cutback.** *(a and b)* This patient presented with biocorrosion lesions on her central incisors and right lateral incisor. Following wax-up/mock-up stages and mock-up–driven minimally invasive preparations *(c,* master cast), the three veneers were designed with the Cerec system by mock-up Biocopy and milled using e.max CAD LT B1 blocks *(d).* The label LT means low translucency. e.max CAD is milled in its precrystallized form (purple block). Each restoration was seated on the master model, and the surface was reduced to create clearance for the layering porcelain *(e),* followed by a crystallization firing at 840°C, providing the material with its final optical properties and strength *(f).* (Patient treated in collaboration with Dr Mehrdad Razaghy; laboratory work/images by Dr Jair Rodriguez Ivich, Guadalajara, Mexico.)



t.me/Dr_Mouayyad_AlbtousH

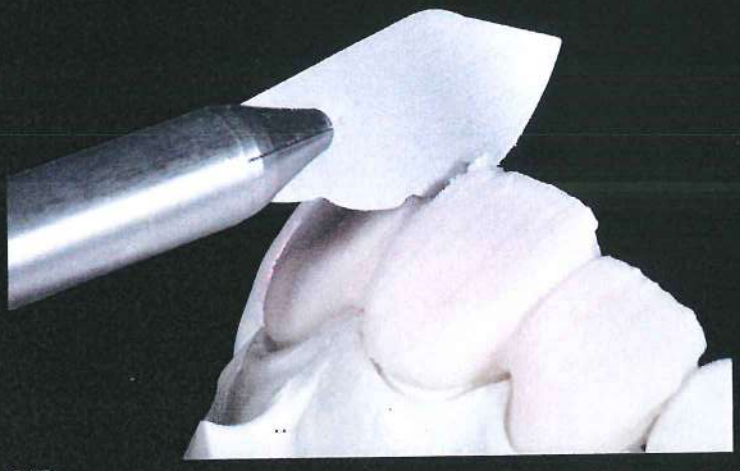

6-57g



6-57h



6-57i



6-57j

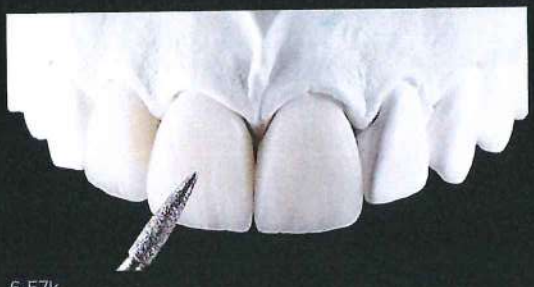

6-57k



6-57l



6-57m

**FIG 6-57** *(cont)* Additive layering. Dentin porcelain was added and histoanatomically reduced *(g)* and completed with transparent "blue" enamel (linguoincisal edge) and dentin mamelon effects (labioincisal surface) *(h,* note extended volume to anticipate firing shrinkage). Following firing at 650°C (under vacuum; *i),* a last enamel skin was applied all the way to the labioincisal edge *(j)* and fired again at the same temperature. Final shape and surface morphology were refined with burs *(k)* before final glazing at 710°C and mechanical polishing *(l and m).*


t.me/Dr_Mouayyad_AlbtousH

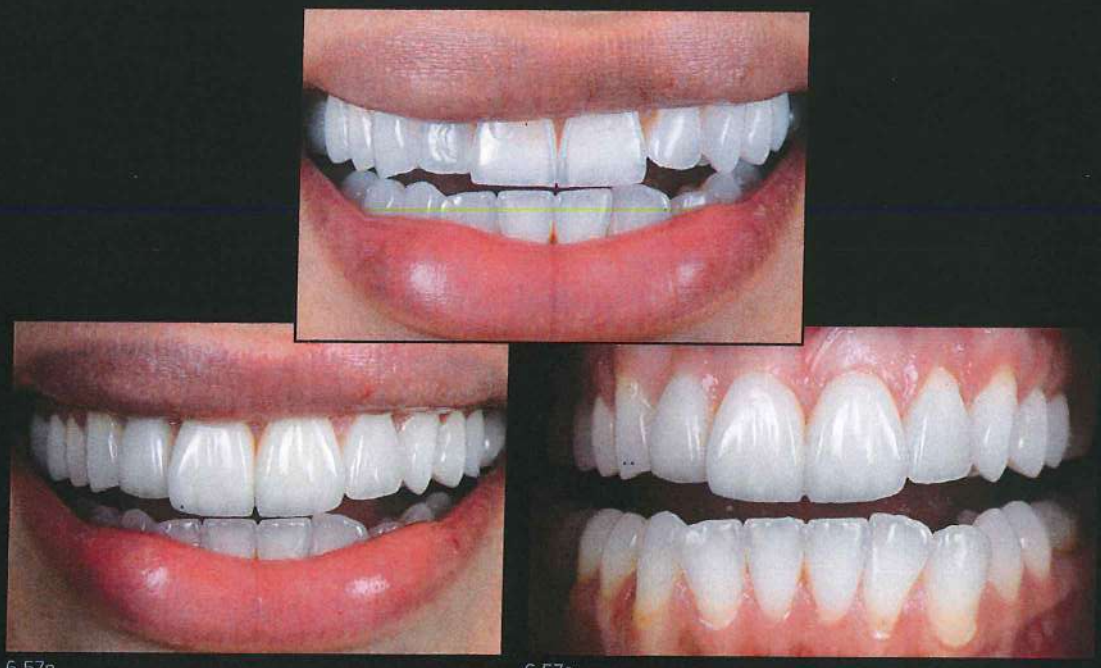

6-57n

6-57o



6-57p

**FIG 6-57** *(cont)* Postoperative views. *(n and o)* Final clinical views following adhesive delivery (preoperative view of the smile in overlay). *(p)* Note the beautiful facial integration. A direct composite resin restoration was placed on the left lateral incisor to increase its length and restore an anatomical defect (concavity) at the mesial aspect of the cementoenamel junction. Some aspects of tooth preparation of this case are presented in Fig 6-28. (Patient treated in collaboration with Dr Mehrdad Razaghy; laboratory work/images by Dr Jair Rodriguez Ivich, Guadalajara, Mexico.)



t.me/Dr_Mouayyad_AlbtousH

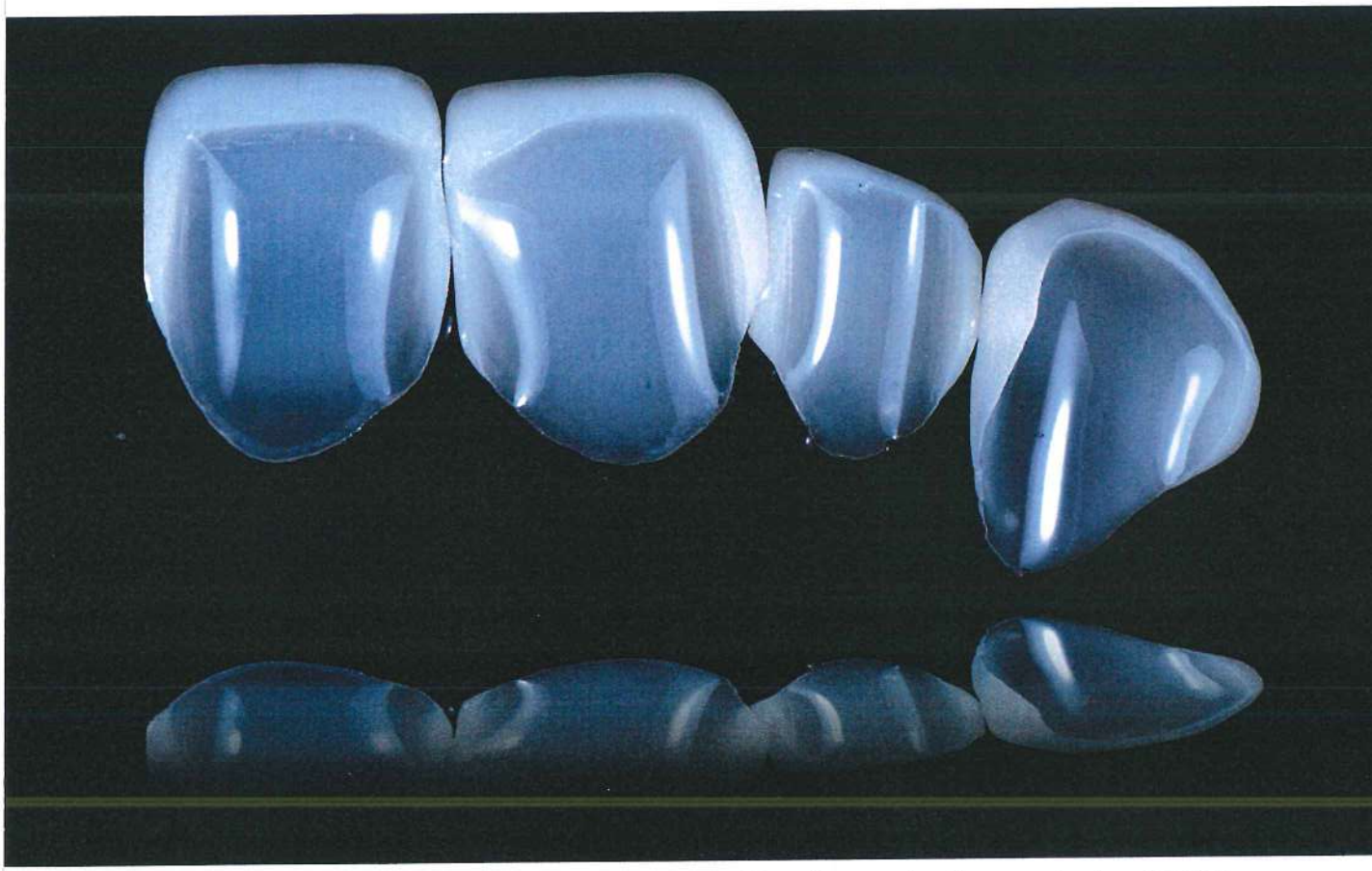

**FIG 6-58 Contact lens veneers.** Extremely thin restorations (0.2 mm) become almost transparent and are therefore highly dependent on the color of the substrate to which they are bonded.

## Types of ceramic veneers based on optical properties

There are three types of veneers, especially when considering full layering approaches.

1. **The so-called contact lens veneer (Fig 6-58).** Described in 1995 by Materdomini and Friedman,[207] this restoration is extremely conservative, thin, and translucent enough to show through the color of the underlying tooth substrate. Contact lens veneers are mostly made of enamellike porcelain. Partial veneers and fragments, because they are inherently thin, also display the contact lens effect.

   ***Here are some cautions about contact lens veneers: (1) They are extremely brittle and delicate. (2) They can be easily broken during delivery, because their technique sensitivity is very high. (3) Due to the above, they need to be delivered with flowable composite resin; such resins, alike dual-cure ones, do not have optimal properties as highly filled composite resins.[208,209] (4) The color of the luting composite will directly influence the color of the contact lens veneer; by the same token, if the underlying tooth structure is changing color over time (eg, due to aging), those changes will become visible through the veneer. Bleaching is still possible through the lingual[28] but is also more lengthy.*** In view of the aforementioned, composite resin materials, rather than porcelain, are more indicated to be used in extremely thin layers due to their resilience and ease of



t.me/Dr_Mouayyad_AlbtousH

manipulation. Whether in the form of CAD/CAM or direct application, they too will display the contact lens effect.

2. **The autonomous veneer.** This type of restoration is made of a combination of dentinlike and enamellike porcelains. This includes CAD/CAM veneers milled with a low-translucency block. As such, it requires slightly more preparation; however, the restoration's color is more independent from the underlying substrate. Due to the substantial underlying dentin buildup, the color of the tooth-restoration assembly is more influenced by the veneer than by the substrate to which it is bonded.

***Here are the advantages of autonomous veneers: (1) They are intrinsically stronger than contact lens veneers, hence (2) the delivery and manipulation are easier. (3) Due to the above, they can be delivered with the thermomodified technique using a preheated, highly filled restorative material (superior physicochemical properties when compared to flowable composite resins). And (4) changes in the underlying tooth structure will not necessarily be visible through the restoration; by the same token, the choice of color for the luting composite resin is not so critical.***

3. **The masking veneer.** A further step toward opacity after the autonomous veneer is the masking veneer, which is discussed toward the end of this chapter (see concept of selective intrinsic masking; Fig 6-70).

The sections following in this chapter (ie, layering, luting procedures, etc) are focused on the use of autonomous veneers, which have been used by the author and his ceramist brother for more than 28 years.

## Master casts in the refractory die technique

Addition silicone impression materials are ideal for the refractory die technique: They are elastic, they are resistant to tearing, and, above all, they allow accurate multiple pours, which is essential to the fabrication of master models.[37,178,180] A definite sequence in the fabrication of master models is explained in Fig 6-59. This technique[210] is a variation of other protocols proposed by Sheets and Taniguchi[201] and Chiche and Pinault.[202]

The production of quality refractory BPRs can be related to the use of multiple models resulting from three consecutive pours of the same final impression, each cast being used for only one precise purpose (Fig 6-59). Multipurpose models are not indicated because each use would result in a progressive deterioration of the cast.

### 1. First pour—Single dies

A very accurate production sequence must be respected, which is summarized in Fig 6-60.

**Stone dies.** Single dies are made of vacuum-mixed improved stone (eg, Fujirock EP, GC); they must be carefully handled because they represent the most accurate reproduction of the preparation. Margins are immediately trimmed, marked with a red pencil, and coated with cyanoacrylate hardener (eg, Margidur, Benzer Dental). Further trimming must be performed to reproduce a root form with two antirotation grooves (Figs 6-60a and 6-60b).

These original dies must be kept untouched because they will be used to verify the final fit of the restorations (control dies).



t.me/Dr_Mouayyad_AlbtousH

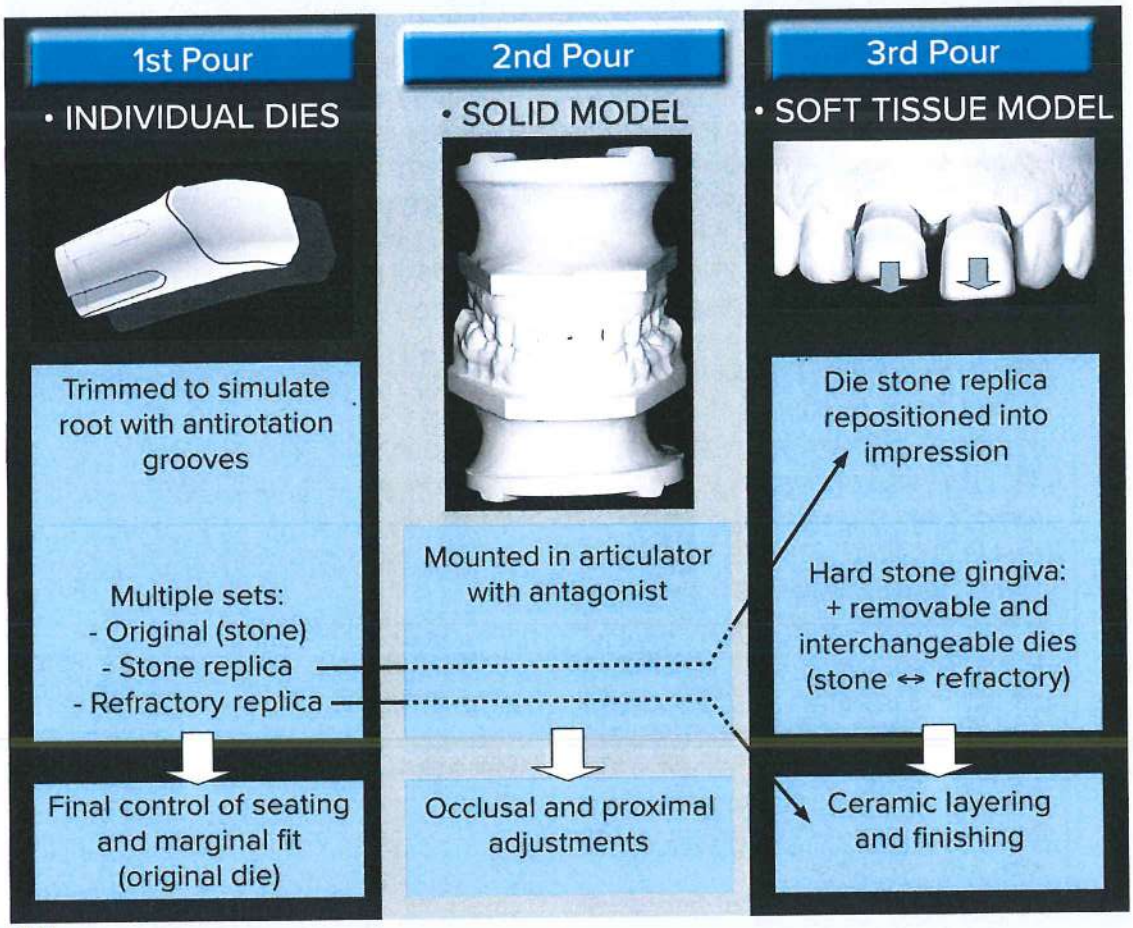


**FIG 6-59 Summary of sequence in the fabrication of casts—consecutive pours of the final impression** (modified from Sheets and Taniguchi[201] and Chiche and Pinault[202]). One set of casts is used for a single purpose, as indicated at the bottom *(white arrows)*. Stone and refractory replicas of individual dies are required to generate the soft tissue model *(dotted arrows)*. Details in the fabrication of each cast are presented in the following figures.

**FIG 6-60a Sequence for single die fabrication and duplicating.** Design and configuration of the original hard stone die include a conical root shape and two lateral slots. The first step involves producing a high-precision silicon mold of this die (duplicating impression I). A replica is poured using the same hard stone (stone replica #1), and die spacer is applied 1 mm short of the margin *(red area)*. A high-precision silicon mold of the stone replica with die spacer is produced (duplicating impression II). Two sets of dies are ultimately generated: one set in refractory material poured in the duplicating impression II and one set in hard stone (stone replica #2) poured in the duplicating impression I. The second stone replica does not include the die spacer and will be repositioned into the original impression for the fabrication of the soft tissue model (see Fig 6-62a).


t.me/Dr_Mouayyad_AlbtousH

# MULTIDIE TECHNIQUE

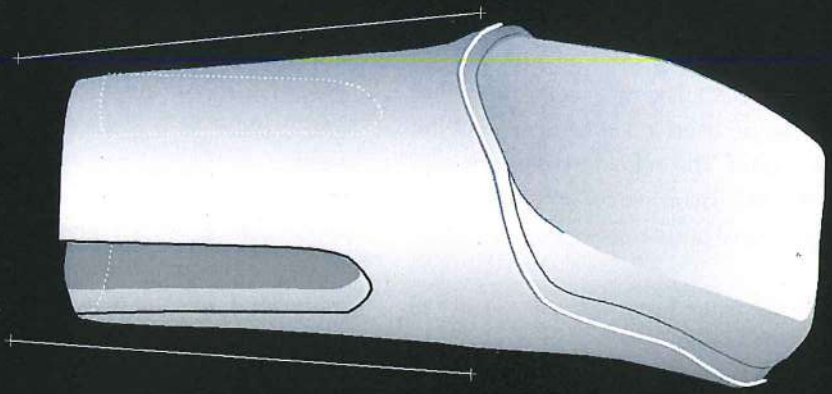

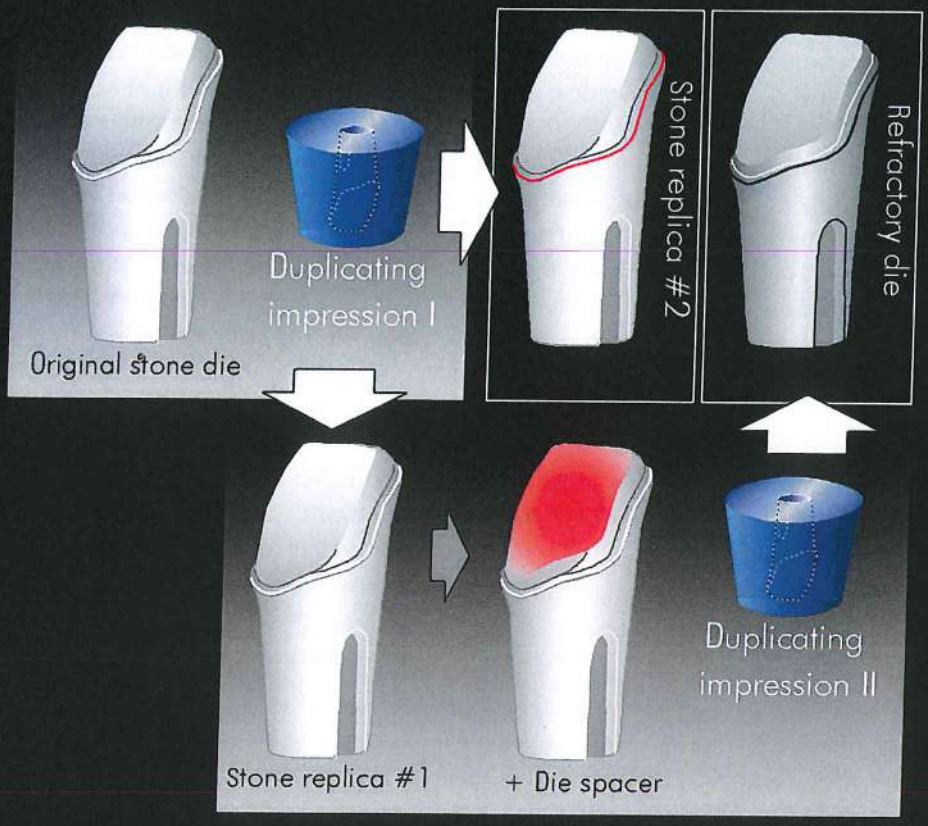


6-60a



t.me/Dr_Mouayyad_AlbtousH

**Refractory dies.** The control dies are immediately duplicated using high-quality laboratory silicones. Two sets of replica are poured in stone. One set is coated with die spacer 1 mm short of the margin and then duplicated to generate a set of refractory dies (eg, G-Cera Orbit Vest for crowns/veneers, GC). The other set of replicated stone dies will be used in the fabrication of the soft tissue model. The refractory dies will also integrate the soft tissue model but still need to undergo additional preparatory steps as follows:

1. Margins are marked with a special pencil that is resistant to firing.
2. A dehydration firing is carried out (1100°C with 5-minute hold).
3. A coating of fine-grain porcelain paste (eg, Connector Paste, GC) is applied 1 mm above the margins and fired (970°C with 1-minute hold).

Step 3 can be repeated until a smooth, even surface is achieved. The fine-grain connecting porcelain is an essential ingredient for the final fit of the restorations; it acts both as a sealer of the refractory surface and as an adhesive (anchored to the die) toward which the firing shrinkage should occur. ***For large teeth, the root portion of refractory dies can be slightly shortened because experience has indicated that the smaller the die, the better the marginal fit.***

***Tedious trimming is avoided because all sets of dies (including refractories) have an identical root portion, which constitutes the exact replica of the original single dies.***

## 2. Second pour—Solid model

The same improved stone is used for the pouring of a full arch. This model must be trimmed and mounted in an articulator (Fig 6-61). Similarly to the diagnostic models, all the working models should be trimmed or fabricated with a flat base using a horizontal reference plane, eg, through a facial analyzer (see chapter 2, Fig 2-14, Ditramax system).

***Because the solid cast represents a good reference for intertooth relationships, it will be used for the final check of occlusion (intra- and interarch contact points).***

The use of a mounting table allowing arbitrary hinge axis transfer on a semiadjustable articulator is recommended.[211] Following this method, a more accurate stabilization can be expected. Numerous errors can be generated during the mounting of maxillary models with a facebow[212]; as a result, the latter yields no profitable improvement of occlusal accuracy. ***In any case, articulator mounting techniques become even less significant due to the fact that, during the fabrication of the BPRs, the ceramist should be mainly guided by the design of the mock-up (through silicon indexes), which was itself tested in vivo under the "true articulator" (ie, the patient).***

Posterior teeth must feature adequate occlusal relationships, allowing the mandibular cast to be positioned in maximum intercuspation without registration material. A soft silicon bite should be utilized only in case of unstable position; it is important to realize that vertical error at the occlusal plane and at the condyle of an articulator can be generated in the presence of a recording material.

**FIG 6-60b Individual dies.** Example of precision silicon mold in a plastic ring *(inset)*. Two different molds have been used to generate stone replicas of the original dies *(left)* and a refractory set *(right)*. Margins of refractory dies have been marked with a refractory pencil followed by dehydration firing at 1100°C. A connecting porcelain paste has been applied over the entire preparation and slightly above the margins *(arrows)*; it produces a glossy surface following firing at 970°C. Each set of dies features the exact same configuration and design (root form with antirotation grooves). (Courtesy of Michel Magne, MDT.)



t.me/Dr_Mouayyad_AlbtousH

# INDIVIDUAL DIES



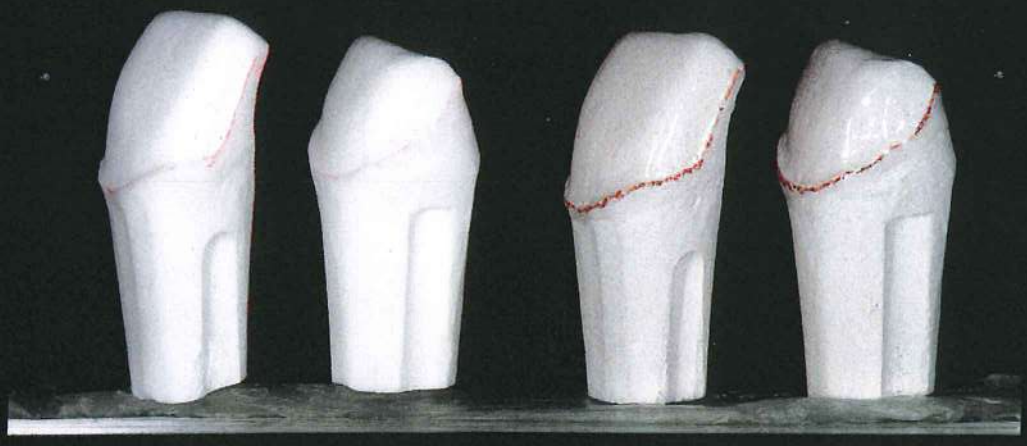

STONE REPLICA #2

REFRACTORY

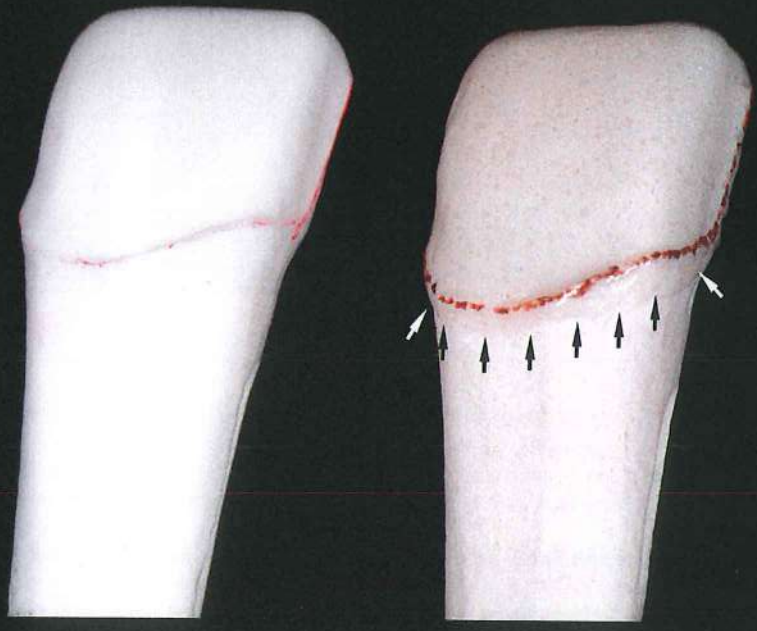

6-60b



t.me/Dr_Mouayyad_AlbtousH

### 3. Soft tissue model (also called the *alveolar model*)[210]

To generate this cast, stone replicas of original individual dies are carefully repositioned into the impression, stabilized (Fig 6-62a), and the root portion isolated. Stone is poured around the dies, resulting in a model base with accurate gingival contours and artificial alveoli conforming to the original shape of the dies (Fig 6-62b). The major advantage of this model is that stone dies and refractory dies can be inserted and interchanged due to the identical design of their root portion, which have the same antirotation grooves (Fig 6-62c). This cast is mainly used during the ceramic layering process and can be mounted in the articulator as a gross guide for occlusion. The soft tissue model should not be considered precise and therefore should not be used for fine occlusal adjustments. For fabrication of multiple veneers, stone dies replicating the wax-up can be inserted to guide the application of porcelain (Fig 6-63).

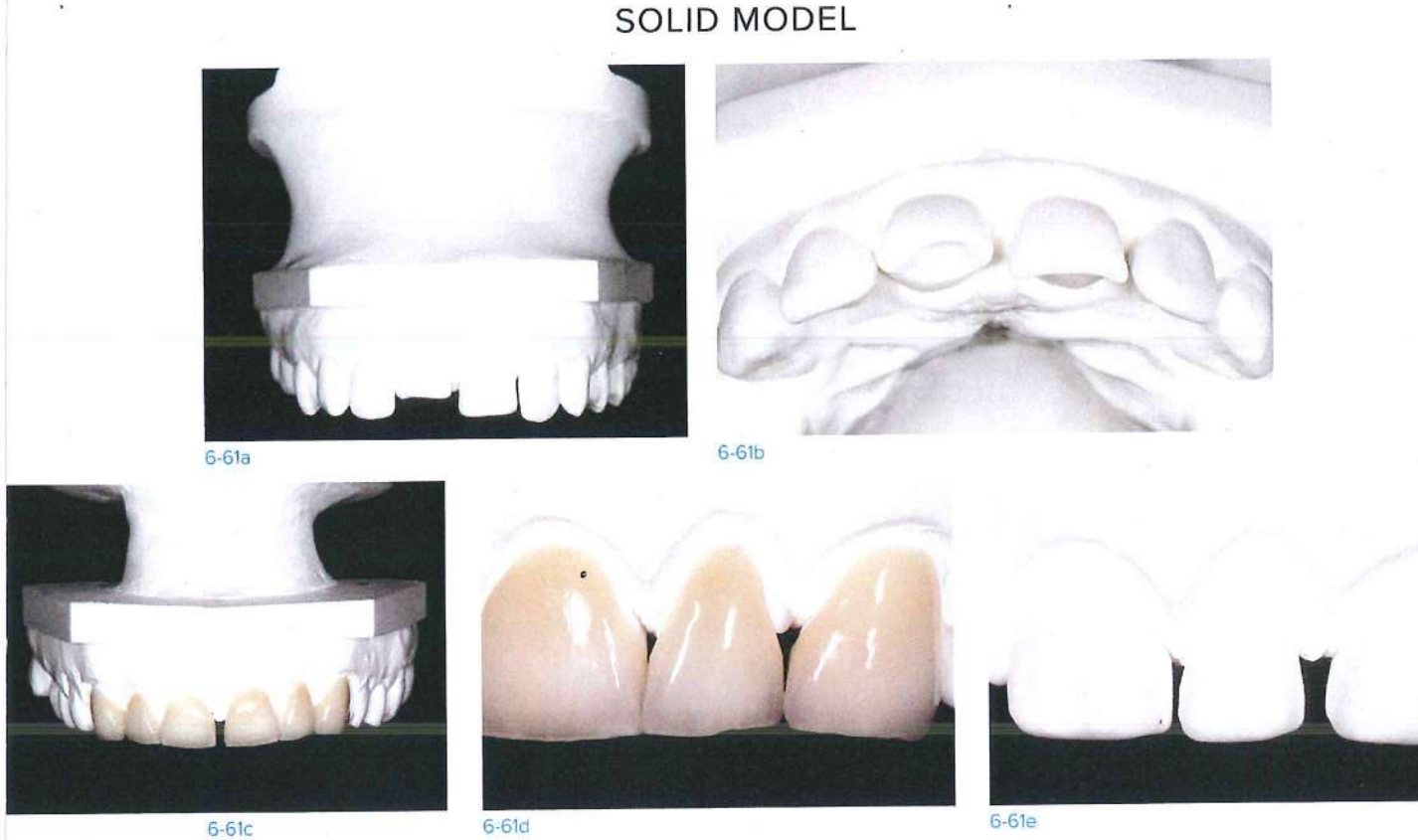


**FIG 6-61 Solid model.** *(a and b)* This one-piece cast with a flat horizontal reference base is the only model that must be mounted in the articulator. *(c to e)* The stone gingiva can be trimmed around the margin of the abutment teeth to ensure the perfect seating of the final restorations. The completed veneers will be checked for interdental contacts and then spot-bonded with some stick glue or wax to check the interarch and dynamic occlusion.

**FIG 6-62 Fabrication of the soft tissue model.** *(a)* Stone dies are repositioned in the impression, stabilized with pins and sticky wax, and finally isolated and sealed with a thin layer of wax using a hot electric spatula (not shown). A first amount of stone is poured around the dies, the cast base being poured in a second step after removal of the pins. *(b)* The soft tissue model features standardized alveolar sockets, hence it is also called the *alveolar model.*[210]



t.me/Dr_Mouayyad_AlbtousH




**FIG 6-62** *(cont)* Advantage of interchangeable dies for fabrication of multiple veneers. *(c)* The antirotation grooves of individual dies are reproduced and allow fine positioning of either stone dies (a), refractory dies (b), or dies reproducing the wax-up (c). The ceramic layering technique for this case can be seen in Fig 6-65; the preparatory steps and additional final views are shown in chapter 5, Fig 5-4; and tooth preparations are shown in Fig 6-31. (Parts *a* to *c* courtesy of Michel Magne, MDT.)



t.me/Dr_Mouayyad_AlbtousH

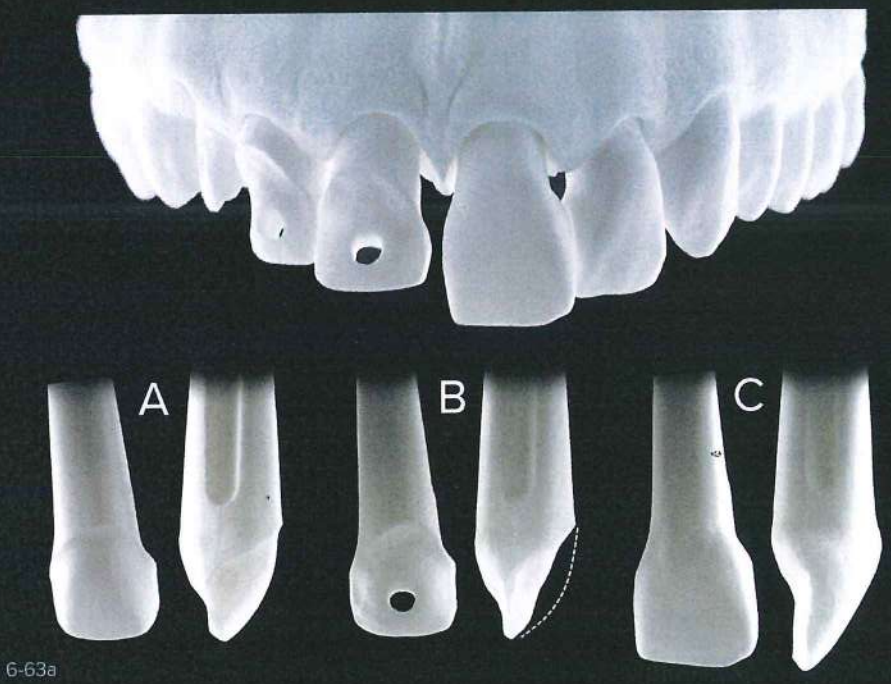


6-63a



6-63b



6-63c



6-63d



6-63e

**FIG 6-63 Replication of the wax-up on the alveolar model.** A silicon matrix of the wax-up or mock-up is used to reproduce the diagnostic wax-up on the stone dies of the soft tissue model. *(a)* For this purpose, an additional set of dies (A) is trimmed and perforated (B). This extra set of dies is placed in the alveolar model, and hot wax is injected through the lingual surface *(b)*, producing a set of dies replicating the wax-up/mock-up (C). *(c)* The same alveolar model can be loaded with the refractory dies. *(d and e)* Waxed dies can be inserted selectively during ceramic stratification to guide elaboration of proximal surfaces and to respect the particular dimensions of each tooth. (Parts *a* to *e* courtesy of Michel Magne, MDT; parts *a* and *b* reproduced with permission from Magne et al.[213])


t.me/Dr_Mouayyad_AlbtousH

### Printed models in the refractory die technique

The aforementioned workflow using stone casts is quite tedious and has been one of the major limitations of the refractory die technique. However, ***digital technologies have developed around the same workflow to produce 3D-printed models with identical characteristics and purpose (single dies, solid model, and soft tissue model).*** With the ever-increasing quality and time-efficiency of 3D printing methods, the workflow will be significantly improved and may result in a resurgence in popularity of the refractory die technique. While the precision of the scanning devices (whether intraoral or in-lab) and printed models/dies is deemed appropriate, the main challenge is the fabrication of the soft tissue model. Several software programs (eg, Model Creator by Exocad; Model Builder, 3Shape) produce alveolar models with tapered alveoli and corresponding removable dies. The duplication of the printed dies into refractory material and subsequent repositioning into the alveolar model, however, can be challenging and require some tuning and adjustments. Figure 6-64 presents printed master models for the refractory die technique produced with this novel approach.[214]

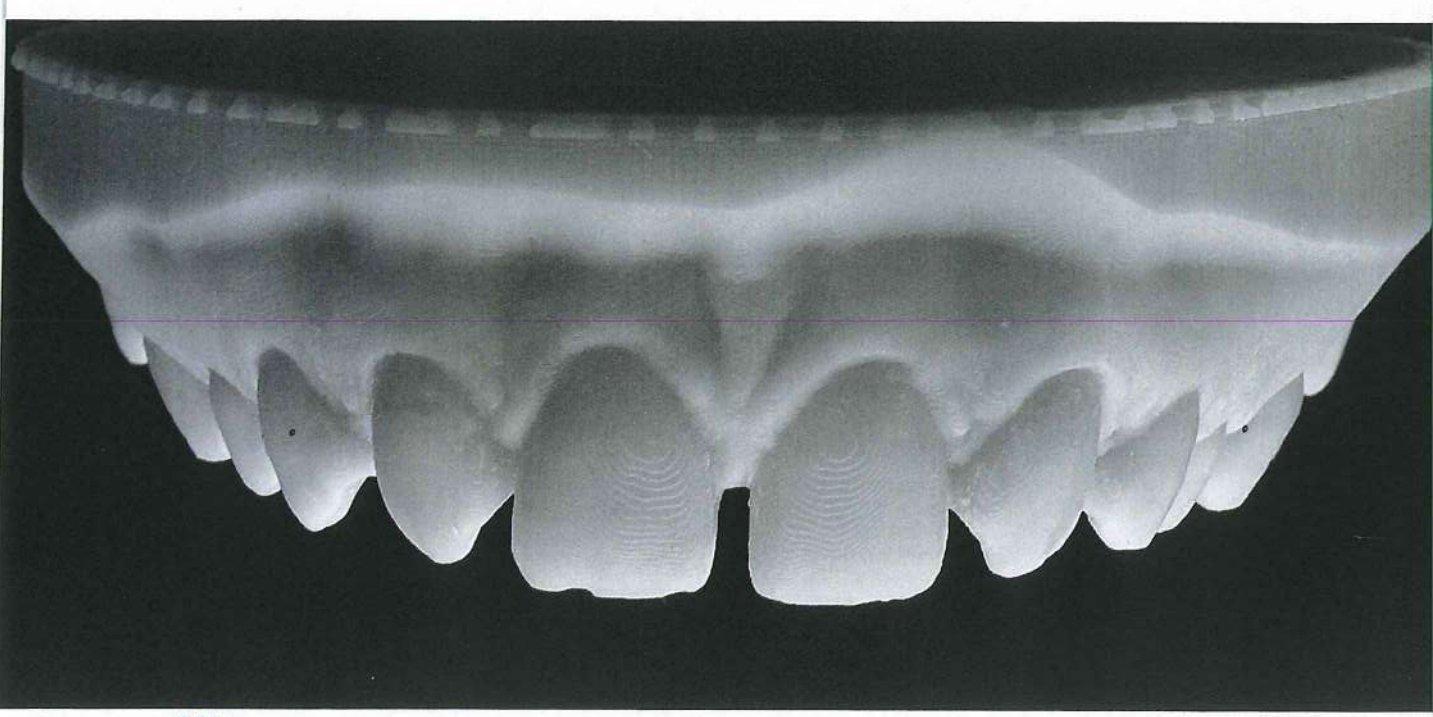

6-64a

**FIG 6-64 Printed models: solid model.** *(a)* Example of printed model using SHERAprint 30 (SHERAdigital), with the resolution set to the maximum (50-micron layer size, 34-micron XY resolution). Printing time for such a model is about 45 to 50 minutes. (Courtesy of Miladinov Milos, Timisoara, Romania.)



t.me/Dr_Mouayyad_AlbtousH

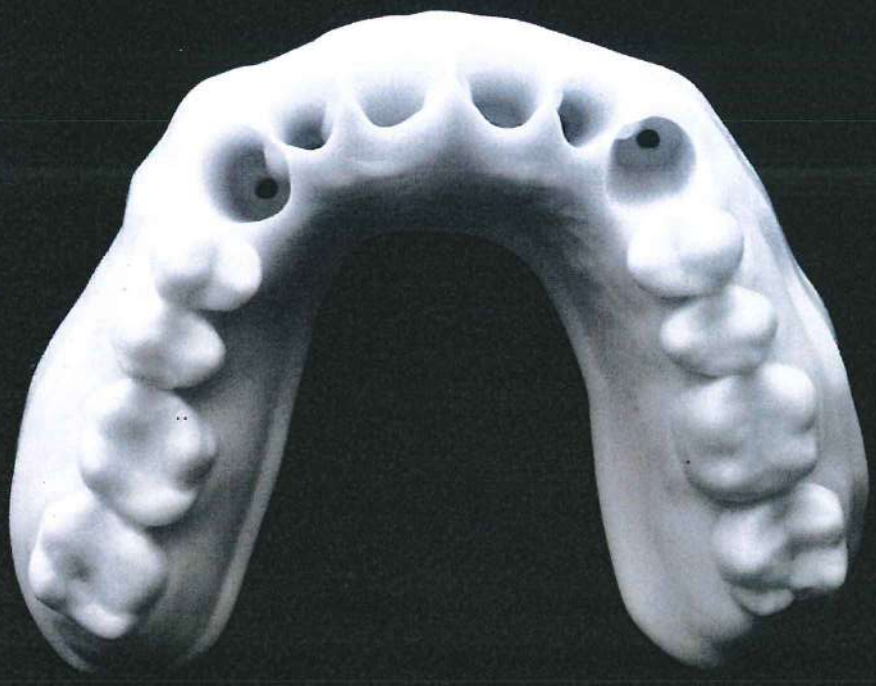

6-64b

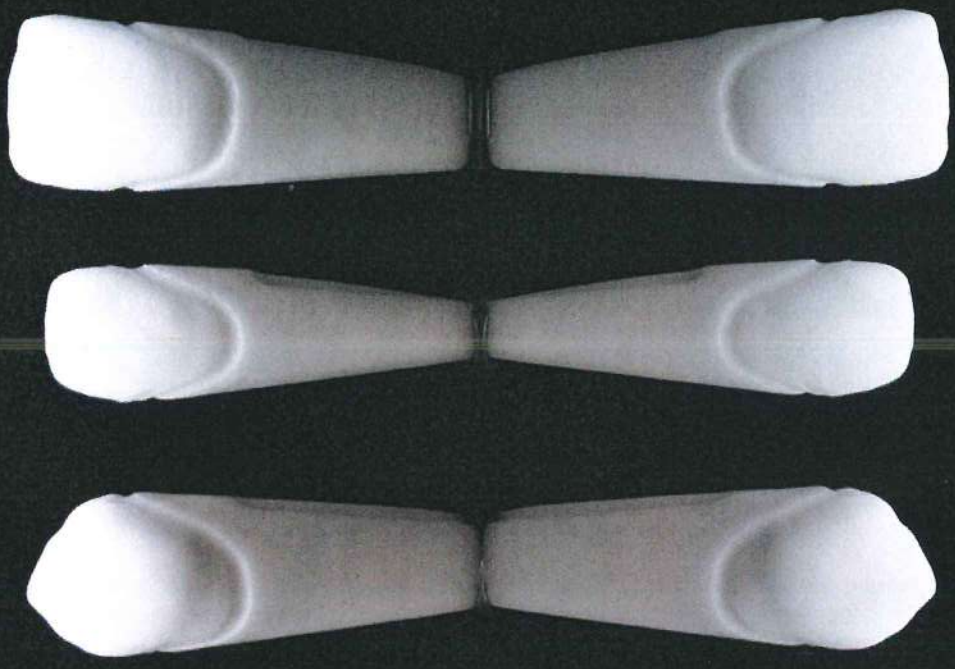

6-64c


t.me/Dr_Mouayyad_AlbtousH

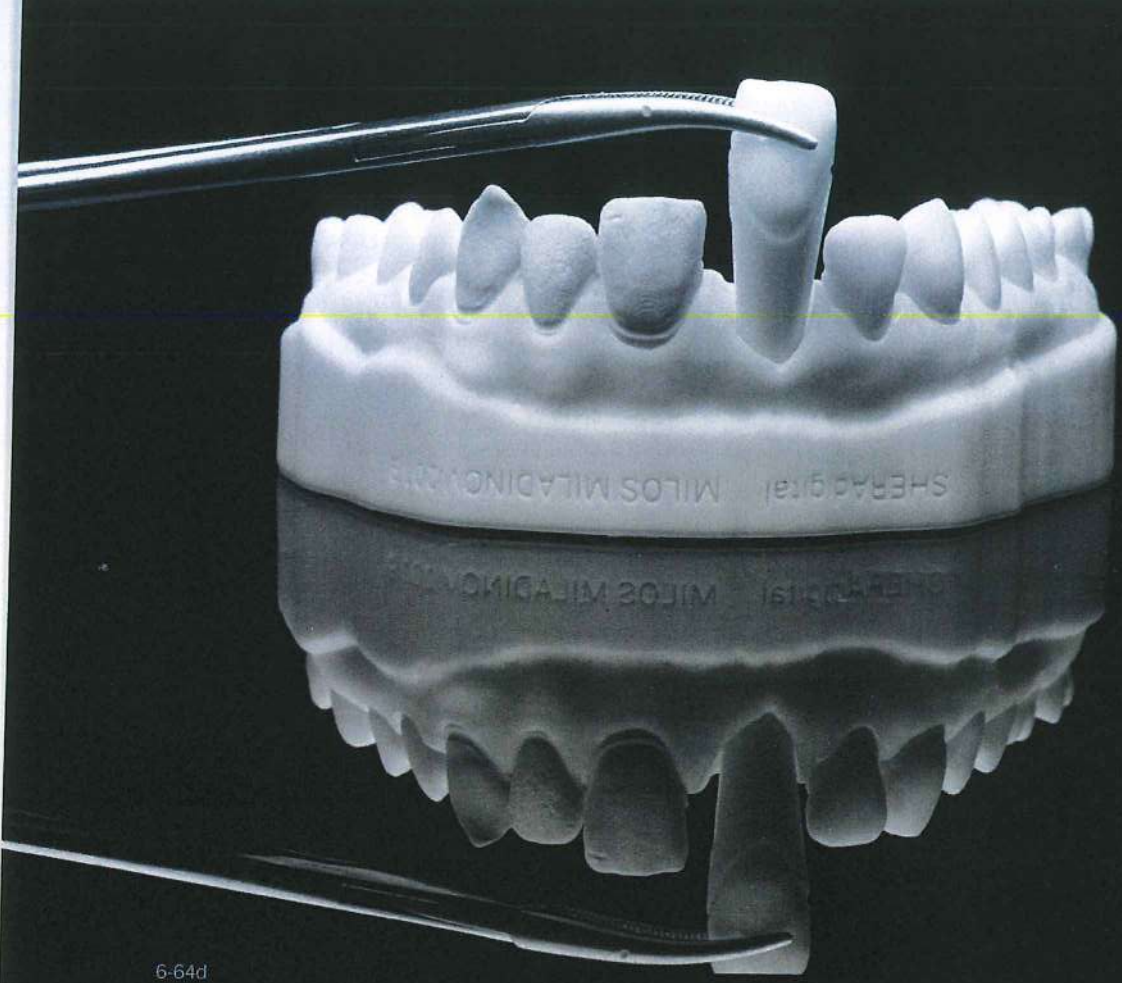

6-64d

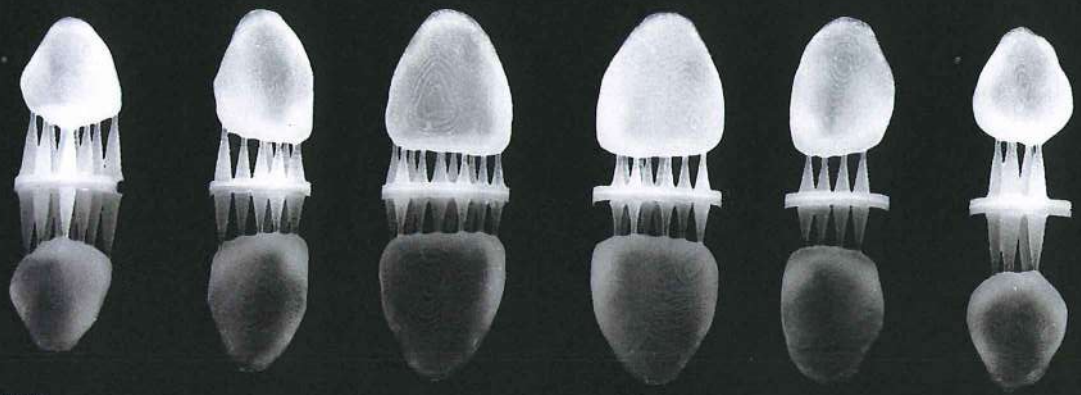

6-64e

**FIG 6-64** *(cont)* **Printed models: alveolar model.** Both the soft tissue base *(b)* and the single dies *(c;* both Smoky White by SHERA) have been designed in the software (Model Creator). Printed dies can be duplicated with the exact same method used for analog models in order to obtain refractory dies (duplicating silicon Sheraduble by SHERA and refractory material Sherarefract by SHERA). *(d)* The resulting model is very similar to that obtained by the analog method, but the process is less tedious. *(e)* The digital workflow also allows the printing of digitally designed trial veneers or mock-ups. (Courtesy of Miladinov Milos, Timisoara, Romania.)



t.me/Dr_Mouayyad_AlbtousH

## Porcelain layering and finishing

### Principles of stratification for autonomous veneers

Elaborate stratification methods have been proposed by the most distinguished ceramists around the globe. For clinicians, understanding the principles of ceramic layering will result in an improved evaluation and appreciation of the ceramic workpiece. Unattainable goals and unrealistic corrections are often requested by clinicians with insufficient dental technique awareness. On the other hand, those who have developed their comprehension of ceramic stratification will directly benefit from this knowledge by *(1)* improving the way they handle the ceramic pieces and *(2)* strengthening their own intraoral layering techniques while performing direct composite resin restorations.

The method presented here is a rational and didactic adaptation of the dentinoenamel layering found in nature. ***This layering is based on the use of a feldspathic porcelain and can be used either for veneering metal/ceramic cores or for direct application on refractory dies (veneers, inlays and onlays).*** It consists of two to three consecutive firings followed by glazing (Fig 6-65):

1. The opaque dentin firing (only for discolored or fractured teeth and interdental wings)
2. The dentinoenamel core firing
3. The outer "enamel skin" firing

The finishing procedure and mechanical polishing will also be discussed. A typical firing schedule is given in Table 6-2 (located at the end of this section).

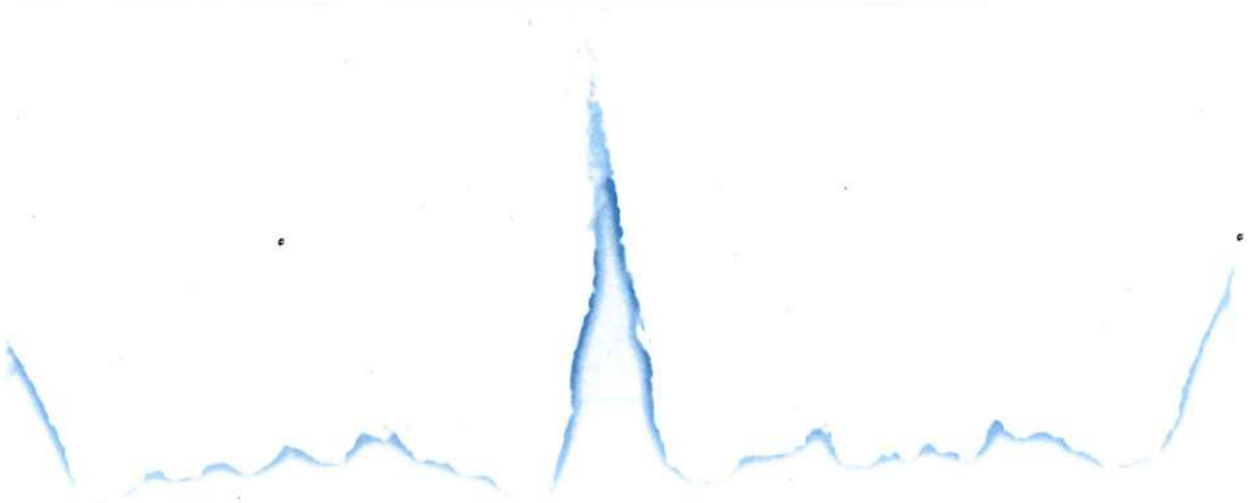

**FIG 6-65 Step-by-step porcelain stratification.**[1] *(a and b)* Preoperative and immediate postoperative views of a patient with mixed indications for BPRs (type IIB + IIC + IIIA; see preparatory steps and additional final views of this case in chapter 5, Fig 5-4; tooth preparations in Fig 6-31; and master models in Figs 6-59 to 6-62). *(c to e)* The first bake will generate an opaque dentin core on the fractured tooth. It is followed by the application of a core of regular dentins *(f)* and more translucent incisal enamels *(g)*. *(h)* Modified dentins are infiltrated to simulate inner characteristics of the incisal edge. An inner translucent enamel skin covers this buildup *(i and j)*, and the second bake can be carried out *(k*, note the shrinkage of coronal volume). (Parts *c* to *q* courtesy of Michel Magne, MDT.)

[1]Some ceramic powders have been artificially colored to allow a better perception of the buildup technique. Pink: regular dentins; bluish: incisal enamels; orange: modified dentins; unstained: shaded enamels and enamel skins.



t.me/Dr_Mouayyad_AlbtousH

6-65a





6-65b

BASELINE



6-65c

OPAQUE DENTIN



6-65d

**BAKE 1**



6-65e

DENTIN BUILDUP



6-65f

INCISAL WALL



6-65g

INTERNAL STAINING



6-65h

INNER ENAMEL SKIN



6-65i



6-65j

**BAKE 2**



6-65k



t.me/Dr_Mouayyad_AlbtousH

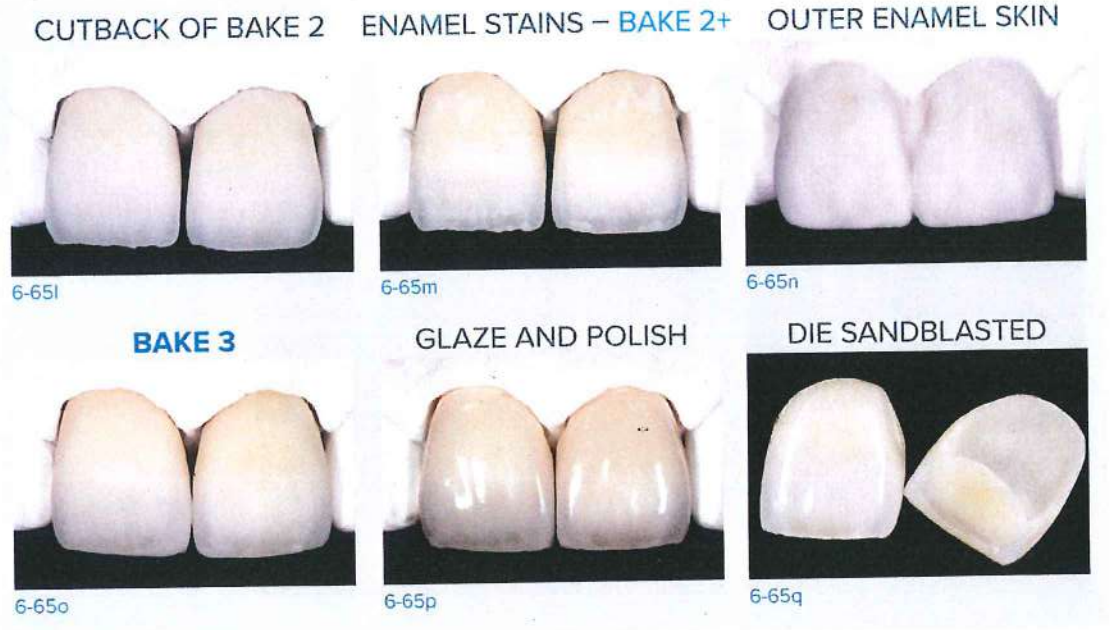


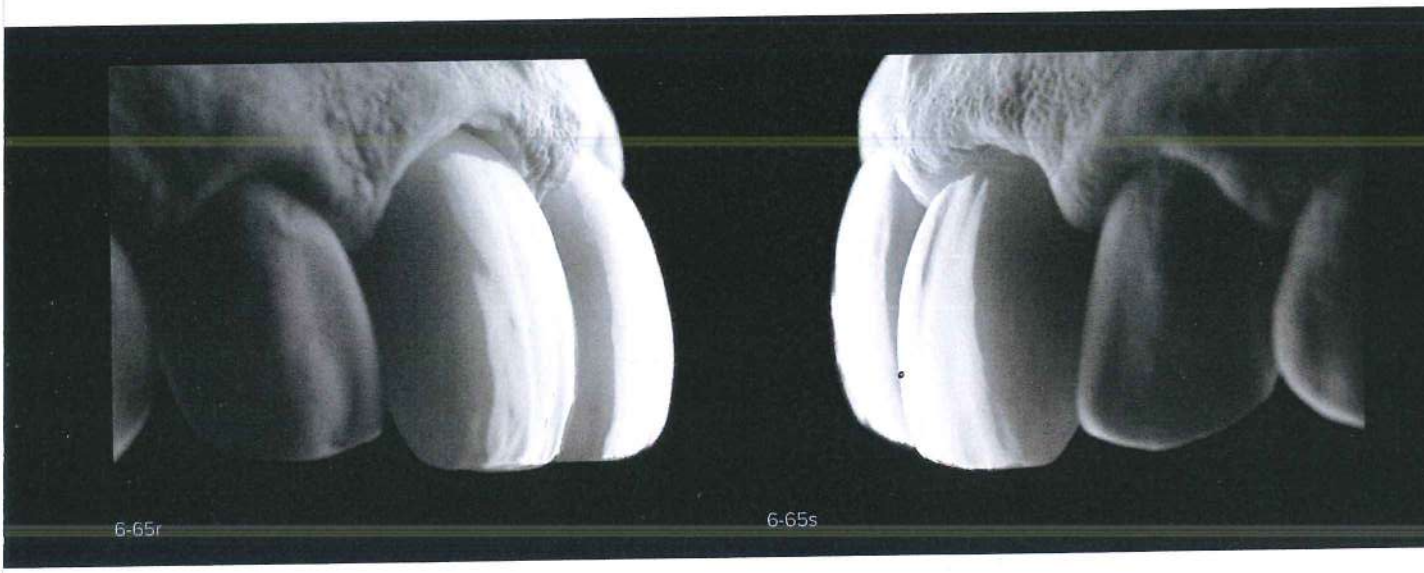


**FIG 6-65** *(cont)* A slight cutback *(l)* should allow the application of superficial enamel stains followed by a low-temperature (800°C) fixation bake *(m)*. The final volume of the restoration can be accurately obtained through the application of a thin enamel skin *(n)* and its subsequent firing *(o)*. *(p)* Glazing and mechanical polishing are combined to obtain the final surface texture and gloss. *(q)* The refractory material is removed by air abrasion with 50-micron glass beads at 1.5 bar (22 psi) only after completion of surface finishing procedures. Note the well-defined vertical lobes *(r and s)*, natural emergence, architecture, and gloss of the facial surface *(t)*. Because of the structured dentin buildup (opaque plus regular dentins), no transition can be seen between the tooth-supported part of the restoration and the freestanding incisal porcelain edge *(u)*, the ultimate esthetic integration of the BPR being only possible in the presence of adequate gingival contour (note perfect distal gingival seam) and favorable periodontal response *(v)*. The diagnostic and preparatory steps of this specific case are illustrated in chapter 5 (Fig 5-4), and tooth preparation is shown in Fig 6-31.



t.me/Dr_Mouayyad_AlbtousH

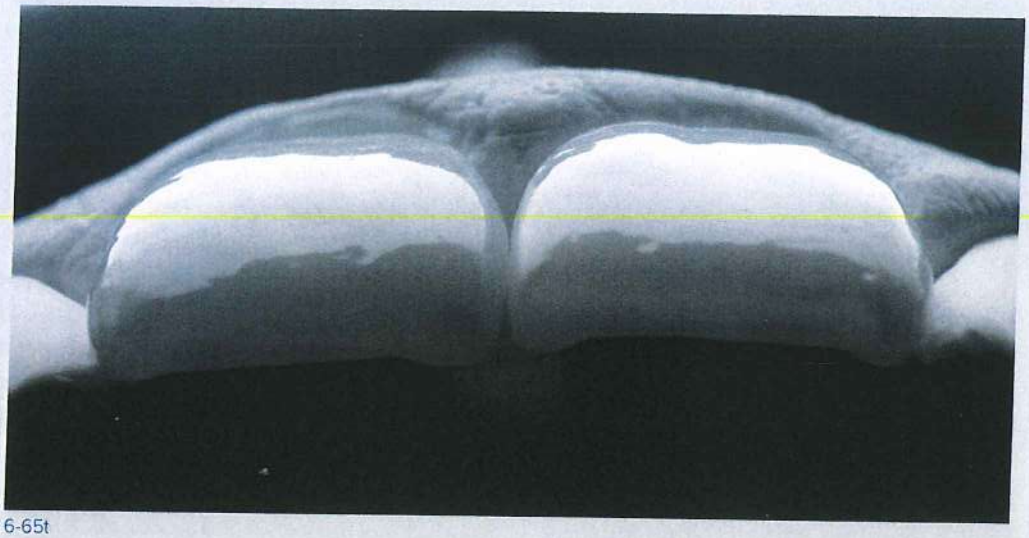

6-65t



6-65u



6-65v



t.me/Dr_Mouayyad_AlbtousH

Figures 6-66a to 6-66c show the postoperative and tooth preparation views, respectively, of a case developed with the stratification details in the following paragraphs.

**1. Opaque dentin buildup.** Three typical situations require the use of modified opaque dentin:

- Diastemata/miniwings: The black triangles and gap between teeth requires blocking of the light.
- Masking of discolored teeth (see section "Masking effects" and Fig 6-70).
- Fractured incisal edges: ***The lack of sufficient supporting natural dentin must be compensated by a special buildup of opaque dentin that reproduces a similar outline for all preparations*** (Figs 6-66d to 6-66f). The absence of opaque dentin would result in increased light absorption at the level of the missing natural dentin. Similarly with discolored tooth preparations, the absence of a thin modified opaque dentin liner would result in insufficient masking ability of the veneers. Higher-value dentin can be used for this purpose.

**2. Dentin buildup.** Unless a special preliminary opaque buildup is required (mentioned above), stratification can normally start with the application of dentin powders using the base shade dentin (usually several shades with higher chroma in the cervical area and higher value in the incisal area). ***A full-size tooth is built in dentin using the palatal silicon index of the wax-up as a mold*** (Figs 6-66g and 6-66h).

**3. Cutback.** This basic form is then reduced, especially at the incisal and incisoproximal level, to generate space for other powders (6-66i). ***The cut-back dentin should reproduce the natural incisal dentin core as described in chapter 1 (see Fig 1-2a).*** For central incisors, this architecture typically includes three basic vertical lobes, or mamelons. The wax-up is constantly used as a reference (in the form of a palatal silicon index) for the placement of the different masses.

**FIG 6-66 Layering of dentin, dentin effects, and inner enamel skin.**[1] *(a to c)* Final view of the case that will be developed and the corresponding tooth preparations (the black-and-white analog photograph is shown to allow a better perception of the final brightness and value). *(d)* All of the layering will be performed on the soft tissue model; refractory dies have already been dehydrated, coated with the connecting porcelain, and sintered. *(e)* In fractured teeth, the first increments are made with opaque dentin powders that restore the missing dentin; *(f)* they are immediately sintered. *(g and h)* The tooth is then fully built with dentin powders. *(i)* The volume is reduced incisally and proximally by creating concave surfaces. Both views in *e* and *i* are directed down to the incisal edge to improve perception of the relationship between the buildup and the silicon index. (Part *a* reproduced from Magne.[85])

[1] Some ceramic powders have been artificially colored to allow a better perception of the buildup technique. Pink: regular dentins; blue: incisal enamels; yellow: modified dentins; unstained: shaded enamels and enamel skin.



t.me/Dr_Mouayyad_AlbtousH



6-66a



6-66b



6-66c

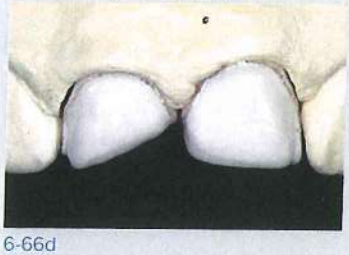


6-66d

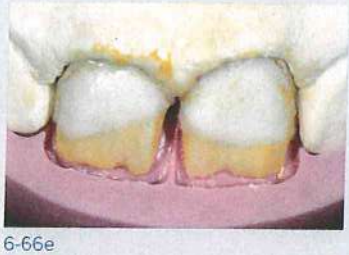


6-66e

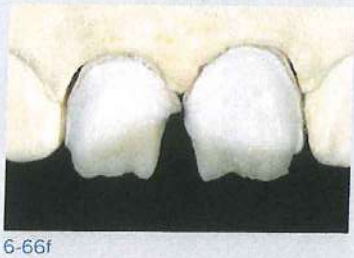


6-66f




6-66g



6-66h




6-66i



t.me/Dr_Mouayyad_AlbtousH

**4. Enamel incisal wall.** Two distinct "horns" of pure enamel are placed at the mesial and distal aspects of the incisal edge (Figs 6-66j and 6-66k). Their exact location and length are guided by the palatal silicon index (Fig 6-66l). These mesial and distal incisal horns define the frame of a palatal incisal wall resulting from the placement of other vertical enamel increments (Figs 6-66m and 6-66n). ***The lifelike appearance of this wall is achieved by alternatively using enamel powders with various translucencies and chroma.*** Fully transparent incisal ceramic can be mixed to the original enamel powders to generate a wide range of values. Shaded enamel powders can also be used. The incisal wall must be slightly oversized (approximately 0.5 mm longer and wider than the silicon index) to anticipate the firing shrinkage.

**5. Dentin characterization.** The incisal wall is used as a substrate for the infiltration of dentin powders that have been modified with intensive stains (Fig 6-66o). Various internal effects within the incisal edge are created by the balanced application of fluorescent and nonfluorescent stains (6-66p to 6-66r). Fluorescent stains may be used to highlight dentin "mamelons"), whereas nonfluorescent stains tend to reduce the effect (Fig 6-66r). These distinct internal characteristics and effects must be defined accurately using a photograph of an intact reference tooth. The same procedure is applied when layering the lingual surface.

**6. Enamel covering and first bake.** The characterized dentin wall is still thin (Figs 6-66s and 6-66t). ***The next step is the application of an inner enamel shell; the entire facial surface is covered with a combination of other translucent and opalescent powders specially designed to simulate shaded enamel.*** The cervical third, middle third, and incisal third of the facial surface are covered separately. Special cervical transparent enamels are applied first (Fig 6-66u), followed by the definition of a central "belt" covering the middle third (Fig 6-66v).

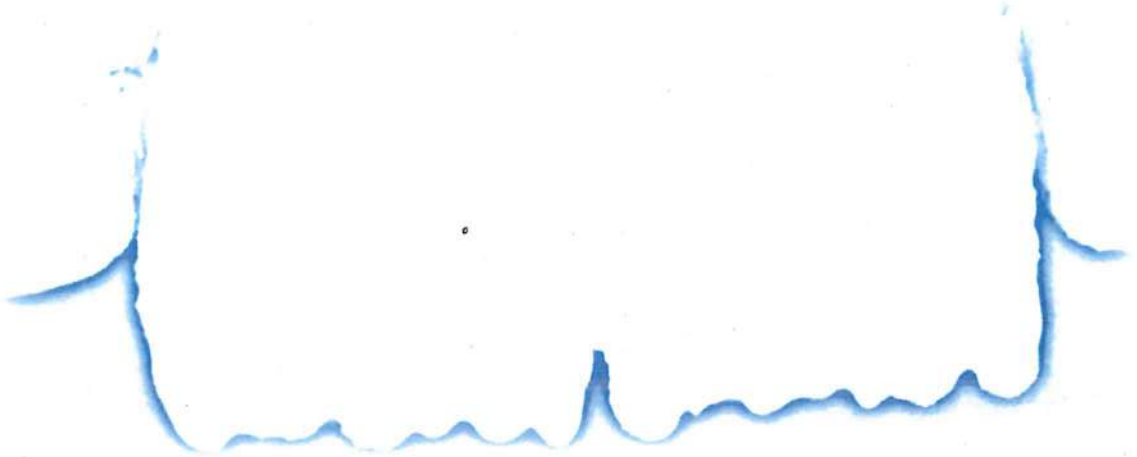

**FIG 6-66** *(cont) (j and k)* The incisal wall is defined first by the placement of mesial and distal increments or incisal "horns." *(l)* Their initial length conforms to the silicon index. *(m and n)* Vertical increments of enamel with various translucencies and chroma are used to build the rest of the wall, the final length of which should be approximately 0.5 mm oversized. The labial surface of the wall is then infiltrated with tinted dentins *(yellowish area in o)* to produce special internal effects of the incisal edge (dentin mamelons). *(p)* These dentins are modified with fluorescent stains (eg, In Nova, Creation CC Willi Geller) and nonfluorescent stains (eg, Make Up, Creation CC Willi Geller); both types of stains have a wide range of colors. *(q)* Black light emphasizes the different behavior of each type. *(r)* Even "dark" In Nova colors can feature a good support of brightness by fluorescence, while bright Make Up stains can appear "black" under luminescent conditions. *(s)* The thickness of the characterized incisal laminate must be kept thin. *(t)* The same steps are applied to the lingual surface. *(u to w)* A preliminary enamel covering (inner skin) is applied using shaded enamels. The tooth must be oversized because of subsequent firing shrinkage. (Courtesy of Michel Magne, MDT.)



t.me/Dr_Mouayyad_AlbtousH

## INCISAL WALL



6-66j

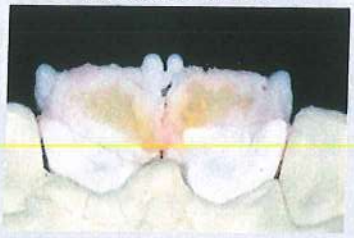

6-66k

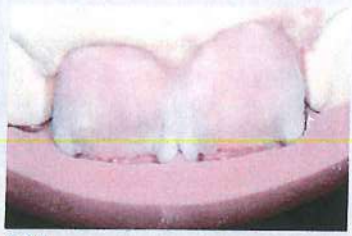

6-66l

## INCISAL WALL + INTERNAL STAINING



6-66m



6-66n

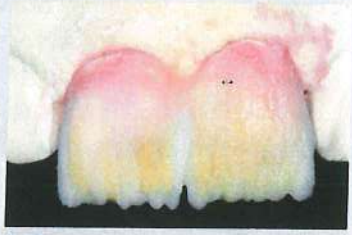

6-66o



6-66p




6-66q



6-66r

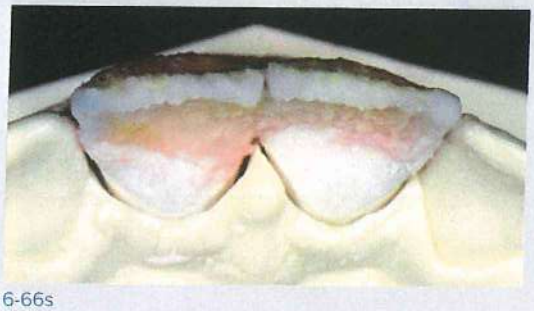

6-66s

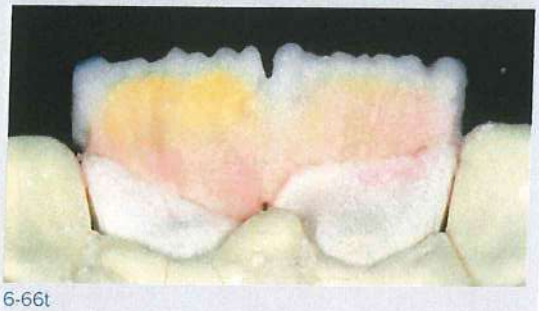

6-66t

## INNER ENAMEL SKIN



6-66u



6-66v



6-66w



t.me/Dr_Mouayyad_AlbtousH

Different combinations of shaded enamels are used according to the type of tooth (dark versus bright), but they are always applied alternatively in tiny vertical increments (Fig 6-66v). Special blue translucent enamel powders can be applied at the incisoproximal level when required. Finally, the remaining incisal window is covered with enamel powders that can integrate some opalescence (Fig 6-66w).

The subsequent firing (second bake in the case of fractured teeth) is carried out and should reveal three characteristic areas with well-defined values: high-value middle third, average-value cervical third, and low-value incisal third (Figs 6-67a and 6-67b). This distribution of values is found in 60% to 70% of natural teeth (see chapter 2, Figs 2-11c to 2-11e).

**7. Characterized enamel skin and firing.** At this stage, volumes should be slightly underbuilt (Fig 6-67a). It might be necessary to cut back the surface slightly to leave a thin and uniform space for the application of the outer enamel skin (Fig 6-67c). The application of this matte layer is usually preceded by the placement of enamel characteristics, eg, in the form of white spots and cracks (Fig 6-67d). A low-temperature firing (800°C) allows the fixation of these stains before the final covering with the outer translucent enamel skin. Here again, different powders must be used alternatively in vertical increments (Figs 6-67e and 6-67f). Translucent/transparent opalescent enamels are indicated at this stage. ***Because this last layer is thin, only minor firing shrinkage will occur, allowing fine control of the ultimate shape and volume.*** The last firing reveals the internal staining and structure of the buildup (6-67g and 6-67h).

**8. Contouring.** Because most special effects (eg, stained dentin, enamel characteristics) have been embedded within the previous layers, surface adjustments can be performed without altering these essential characteristics. ***The final contouring is facilitated when the landmarks of crown shape are marked with a pencil (Figs 6-67i and 6-67j).*** Lobes and transition line angles can be either softened or accentuated with diamond burs.

**FIG 6-67 Enamel characteristics, outer enamel skin, and finishing.** *(a)* The previous bake should generate a tooth with reduced volume, featuring all internal effects and dentin characteristics. *(b)* The lingual view reveals the low-value incisal edge and uniform opaque dentin underneath. *(c)* The first enamel skin must be slightly undersized to allow its characterization and subsequent coverage. Grinding is often necessary to increase space at the incisoproximal level *(arrowheads in c)*. *(d)* Tiny white spots and craze lines can be painted on the reduced surface (visible at the distal incisal edge of the left central incisor, *arrowhead*). *(e)* After a low-temperature firing, these effects are finally covered with the outer enamel skin. *(f)* The final shape of the tooth must be attained by this layer. *(g and h)* Following the last firing, the main tooth shape should be almost definitive. (Courtesy of Michel Magne, MDT.)



t.me/Dr_Mouayyad_AlbtousH

## BAKE 2

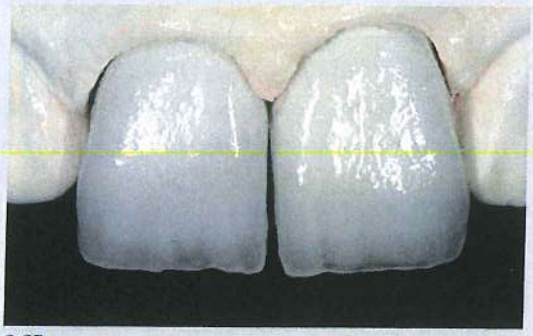

6-67a



6-67b

SLIGHT CUTBACK OF BAKE 2

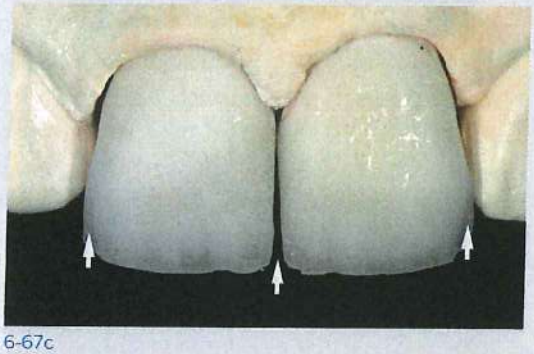

6-67c

ENAMEL STAINS – BAKE 2+

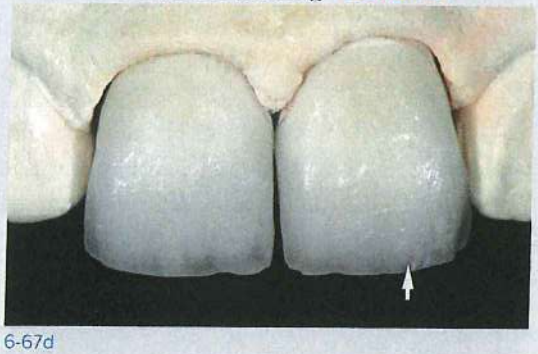

6-67d

OUTER ENAMEL SKIN

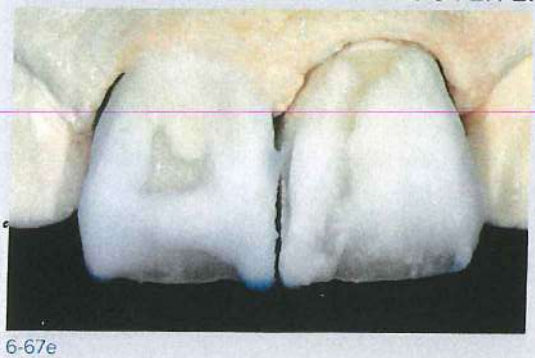

6-67e

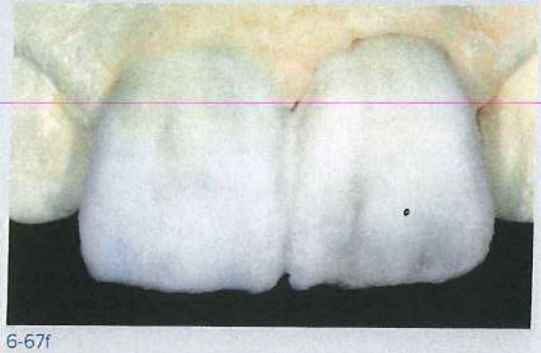

6-67f

## BAKE 3



6-67g

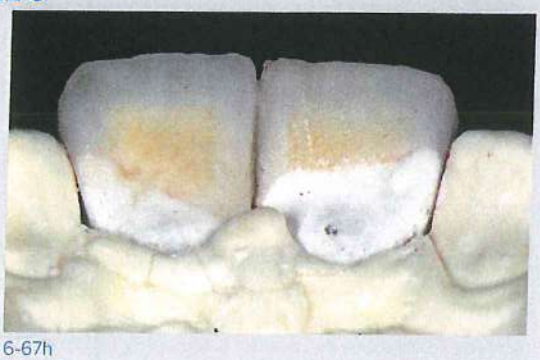

6-67h



t.me/Dr_Mouayyad_AlbtousH

Alike what was explained for composite resin restorations (as well as in chapter 2, criterion 10: surface texture), adequate surface morphology must be achieved (especially the line angles and vertical developmental lobes) before the elaboration of the surface texture. Tiny horizontal developmental grooves should be produced (when required) only at the last stage, sometimes even after glazing. Any type of contouring should be carried out with relatively new diamond instruments. Ceramists must be aware of the possible problems related to the use of old burs: Diamond particles being sheared off not only cause the premature wear of the bur but also possibly increase smearing of the metallic binder onto the porcelain surface. The smearing of nickel on ceramic substrates has been demonstrated.[215] As a consequence, new diamond burs characterized by a pure diamond cutting surface without metallic binder between crystals have been proposed.[215]

**9. Glazing and surface finishing.** A number of mechanical polishing techniques are described in the literature and were compared to the gold standard given by the original glaze. Some authors initially demonstrated the superior smoothness of glazed porcelain.[216,217] Others, however, favor mechanical polishing.[218–221] Haywood et al even concluded that intraoral polishing of porcelain can equal or surpass the smoothness of glazed porcelain.[222,223] Today, it is recognized that improved esthetic results are obtained by polishing.[224] ***However, the degree of success of any polishing technique is still dependent upon having a well-condensed porcelain and adequate firing conditions, because porosity in the porcelain is not completely eliminated by polishing as it is in natural glaze firing.[219] Therefore, the combined use of glazing and polishing can be advocated to improve both esthetic and surface characteristics.***

Mechanical polishing usually begins with diamond-silicon wheels (Figs 6-67k and 6-67l), followed by overglazing (with addition of glazing liquid) or autoglazing, knowing that overglazing usually softens the surface texture. Highly reflective surfaces are finally achieved with pumice and calcium carbonate (eg, Sigolin, Thompson Siegel). Calcium carbonate is a common abrasive material used in dentifrice as well as in cleaning liquids for chrome, steel, and ceramic. It is softer and finer than pumice and allows excellent finishing of the porcelain surface. It is used with brushes and felt tips (Fig 6-67m) at different rotating speeds; long-hair brushes used at rather high speed are ideal to finish smooth surfaces and convexities, whereas short-hair brushes used at low speed are best to finish wavy surfaces and concavities.

**FIG 6-67** *(cont) (i)* Transition line angles, lobes, and superficial grooves are marked with a pencil to assist the optimization of surface morphology and contours (inset shows black-and-white analog). *(j)* The porcelain restorations must remain on the refractory dies during mechanical contouring and finishing. *(k)* Silicon-diamond wheels, felt tips, and diamond paste can be used for preliminary finishing. *(l)* Facial view of the veneers before glazing. *(m)* After glazing, a compact pear-shaped felt tip and pumice can be used. *(n and o)* The final gloss is obtained with brushes and calcium carbonate abrasive. (Courtesy of Michel Magne, MDT.)



t.me/Dr_Mouayyad_AlbtousH

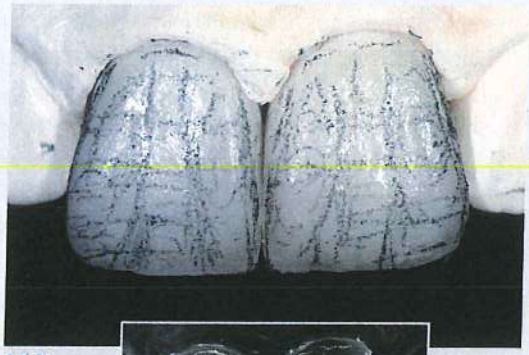

6-67i





6-67j

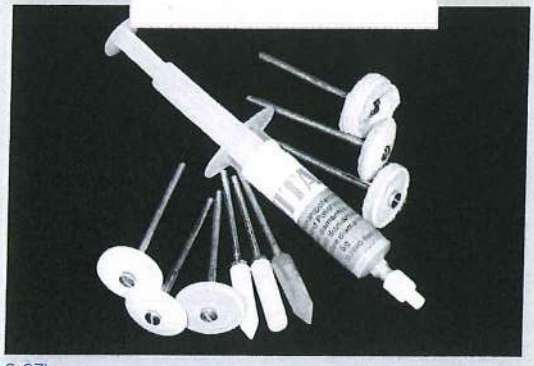

6-67k

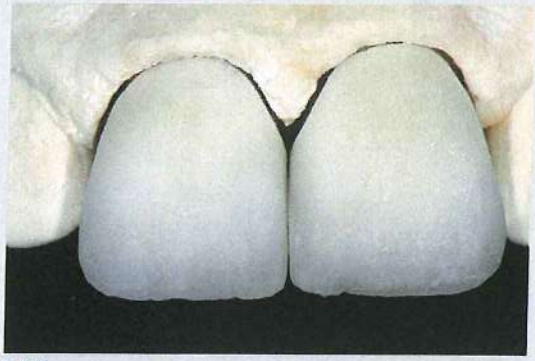

6-67l

## GLAZE AND POLISH



6-67m

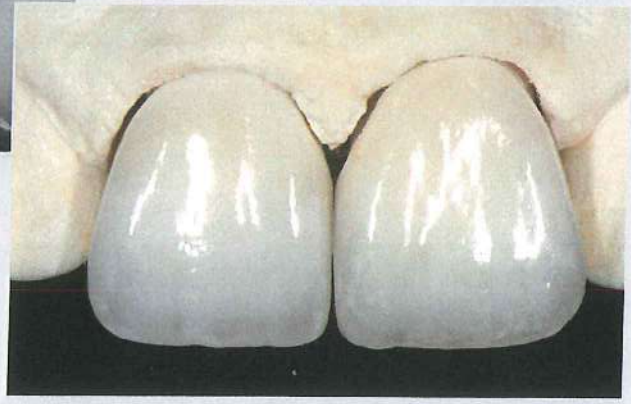

6-67n



t.me/Dr_Mouayyad_AlbtousH

At this stage of the procedure, the restoration is still attached to the refractory die (Figs 6-67n and 6-67o).

***The refractory material should be removed by airborne-particle abrasion only with 50-micron glass beads at 1.5 bar (22 psi) after completion of surface finishing procedures.***

Mechanical polishing requires the physical support of the underlying refractory material, and premature removal would result in high risks for fracture while handling the ceramic piece. The air-abraded porcelain workpieces (Fig 6-67p) can be repositioned on the stone dies (Fig 6-67q), but final control of proximal contacts is ideally achieved on the solid model.

The clinical try-in should not reveal need for major corrections, especially when appropriate diagnostic steps have been followed. Because at this particular stage, the restoration is no longer physically supported by the refractory die, eventual correction firings must be carried out only with low-fusing ceramics, unless it is placed on a new refractory die (using glazing liquid but without connecting porcelain). No corrections were required in the case of Fig 6-67. Final views show adequate opacity of the ceramic core owing to the use of opaque dentin (Figs 6-67r and 6-67s). The right amount of luminescence was obtained as well (Fig 6-67t) because fluorescent stains were adequately integrated into the buildup. The final touch is given by the characteristics and internal staining of the enamel skin, which simulates the opalescence and natural imperfections of enamel (Fig 6-67u).

**TABLE 6-2** Example of firing schedule (based on Creation CC Willi Geller porcelain)

| | Idle (°C) | Heat rate (°C/min) | High temp (°C) | Dry (min) | High temp hold (min) | Vacuum start (°C) | Vacuum stop (°C) |
|---|---|---|---|---|---|---|---|
| Die dehydration | 575 | 55 | 1100 | 9 | 5 | – | – |
| Connector | 550 | 55 | 970 | 6 | 1 | 620 | 970 |
| Dentin | 580 | 55 | 935 | 6 | 0 | 620 | 935 |
| Colorants fixation | 550 | 80 | 800 | 2 | 0 | 620 | 800 |
| Enamel skin | 580 | 55 | 935 | 6 | 0 | 620 | 935[e] |
| Glazing with no glaze | 580 | 55 | 920 | 3 | 0 | – | – |
| Glazing with glaze | 300 | 55 | 905 | 6 | 0 | – | – |
| Corrective low-fusing Duceram LFC | 300 | 55 | 700 | 3 | 0.5 | 380 | 700 |

Courtesy of Michel Magne, MDT.

**FIG 6-67** *(cont) (p)* Final view of the restorations after removal of the refractory material. *(q)* Because the soft tissue model is not accurate for occlusal relationships, repositioning of the veneers onto the original stone dies might not be possible *(arrowhead* showing incomplete seating of the restoration). The solid model must be used instead. *(r and s)* Both direct light and transillumination show the successful work of the ceramist: The full incisal bulk of the porcelain does not differ from the tooth-supported cervical part of the restoration, and it is impossible to distinguish these two areas despite the very different underlying substrates (note view of tooth preparation inset in *r*). (Parts *o* to *q* courtesy of Michel Magne, MDT.)



t.me/Dr_Mouayyad_AlbtousH

DIE SANDBLASTED



6-67o

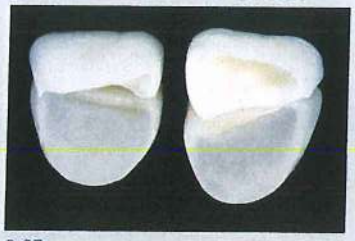

6-67p

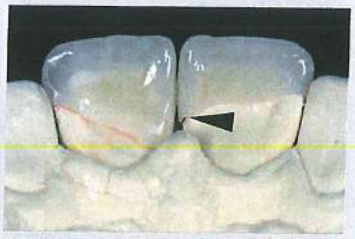

6-67q





6-67r



t.me/Dr_Mouayyad_AlbtousH

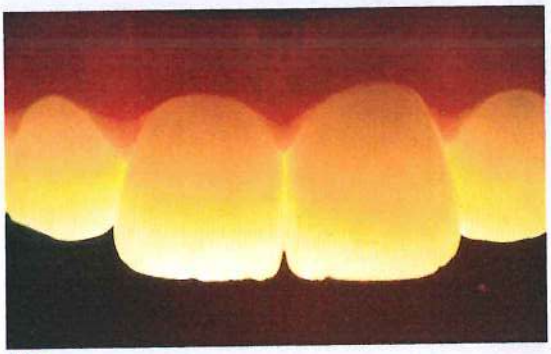

6-67s

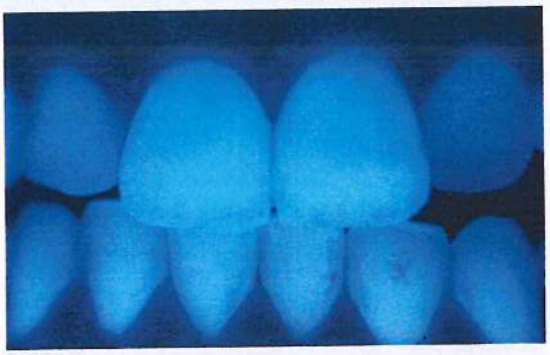

6-67t



6-67u

**FIG 6-67** *(cont) (s and t)* A black light used to evaluate the fluorescence reveals a balanced use of the various pigments. *(u)* Use of lipstick can make teeth appear brighter and emphasizes enamel characteristics. *(v to x)* Final general views showing satisfactory integration with mandibular teeth. (Parts *r* to *t* reprinted with permission from Magne and Magne.[58])


t.me/Dr_Mouayyad_AlbtousH



6-67v



6-67w



6-67x



t.me/Dr_Mouayyad_AlbtousH

## Special effects

### Shape effects

As can be learned from chapter 2 (criterion 8: basic features of tooth form) and chapter 5 (section 5.5: "Diagnostic Wax-up Step by Step"), special features of the facial architecture can be used to create the illusion of a shorter tooth or a wider tooth. These effects must be integrated into the initial diagnostic wax-up.

The use of vertical and horizontal segmentation using the line angles and facial curvature are the main tenets of shape effects.

Figure 6-68 depicts a case where crown length had to be substantially increased to conform to the lower lip contour and restore the cohesive forces of the smile. Horizontal segmentation of the facial surface and external positioning of the mesial and distal transition line angles were used to make the teeth appear shorter than they really are. The opposite effect (to make the tooth appear "longer") would have been obtained by flattening the facial surface and bringing the transition line angles closer to the center of the tooth (Fig 6-69). Schematic illustration of the possible "optical" alterations of tooth shape is given in Figs 6-68g to 6-69d. Other useful tricks for special effects can be found in classic works published by Lombardi[39] and Goldstein.[225]

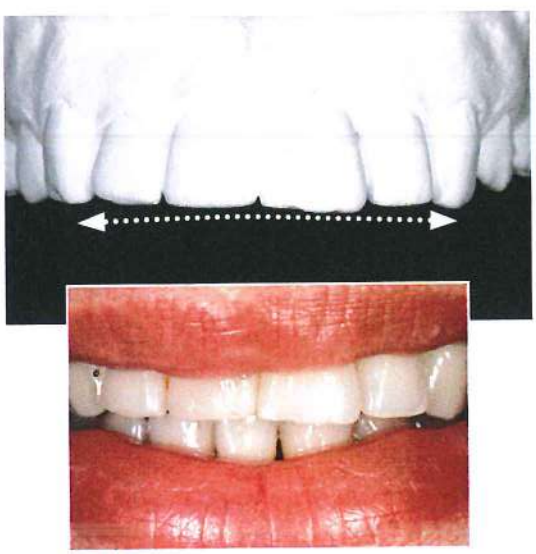

6-68a

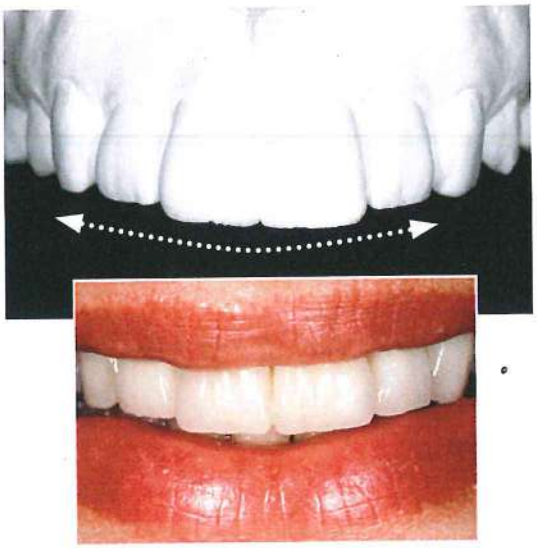

6-68b

**FIG 6-68 Special effects compensating for tooth length and width.** The patient presented after a combined orthognathic/orthodontic treatment (see chapter 5, Fig 5-17). *(a)* The initial situation demonstrates worn incisors and an inverted smile line. *(b)* Significant increase of incisor length was planned, allowing the progressive recovery of a cohesive incisal curve conforming to the lip contour. *(c)* To optically compensate for the increased length of the central incisors, the facial surface of the porcelain restoration was divided in several horizontal segments representing different planes. *(d to f)* Postoperative intraoral views. The light of the camera flash system can only reflect one segment at a time *(e; lines and arrows* indicate at least three segments), giving the illusion of a shorter tooth. The explanation of such an illusion is given in *g*: I, II, and III represent the different horizontal segments of the facial surface. A tooth that appears "too long" (or "too narrow") is corrected by bringing the transition line angles closer to the proximal surface and dividing the facial in at least three distinct segments. (Parts *b* and *e* reproduced with permission from Belser et al.[20])



t.me/Dr_Mouayyad_AlbtousH



6-68c



6-68d

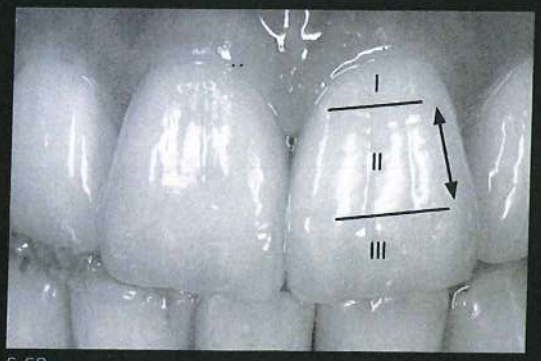


6-68e

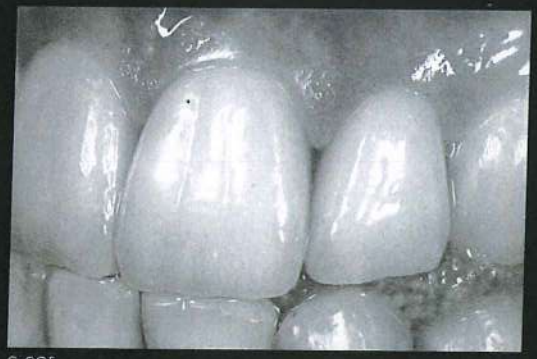

6-68f

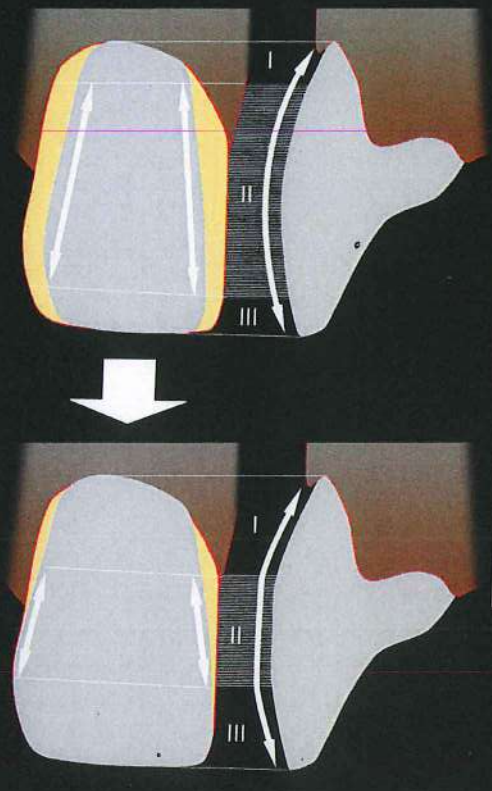


6-68g

## "TOO LONG" TOOTH CORRECTED

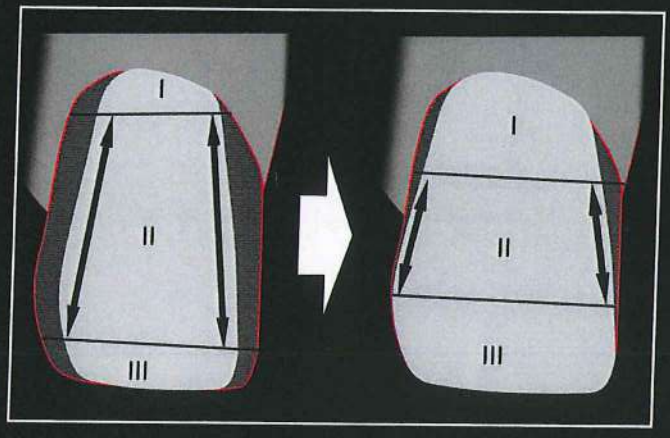




t.me/Dr_Mouayyad_AlbtousH




6-69a



6-69b

**FIG 6-69 Other special effects for shape.** *(a)* "Too wide" tooth corrected. The "too wide" tooth (or "too short" tooth) can be corrected by bringing the transition line angles closer to the center of the tooth and flattening the facial surface to obtain a large central segment. *(b)* The central incisors *(top)* are the same width. The image was digitally modified by slightly moving the mesial line angles, distally for the right central incisor and mesially for the left central incisor; as a result, the left central incisor appears wider and closer *(bottom)*. *(c)* Line angles can also be used to influence the perception of tooth shape and typal form. *(d)* When the position of the line angles is maintained, variations in the proximal shape are not likely to generate major changes in the apparent width of the crown; this principle is used for the closure of diastemata and combined with other effects—eg, the interdental extension of porcelain is made of a more saturated rootlike porcelain.


t.me/Dr_Mouayyad_AlbtousH

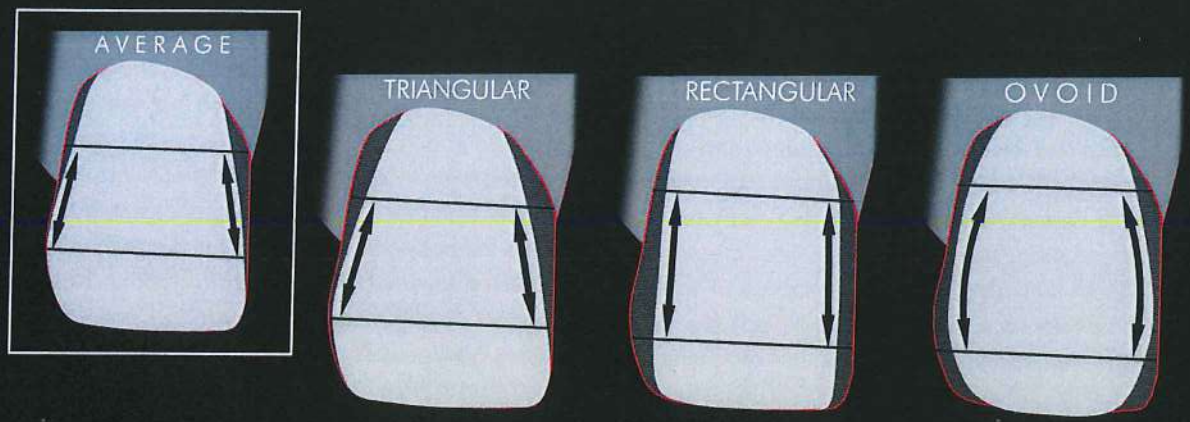


6-69c

## DIASTEMATA CLOSURE

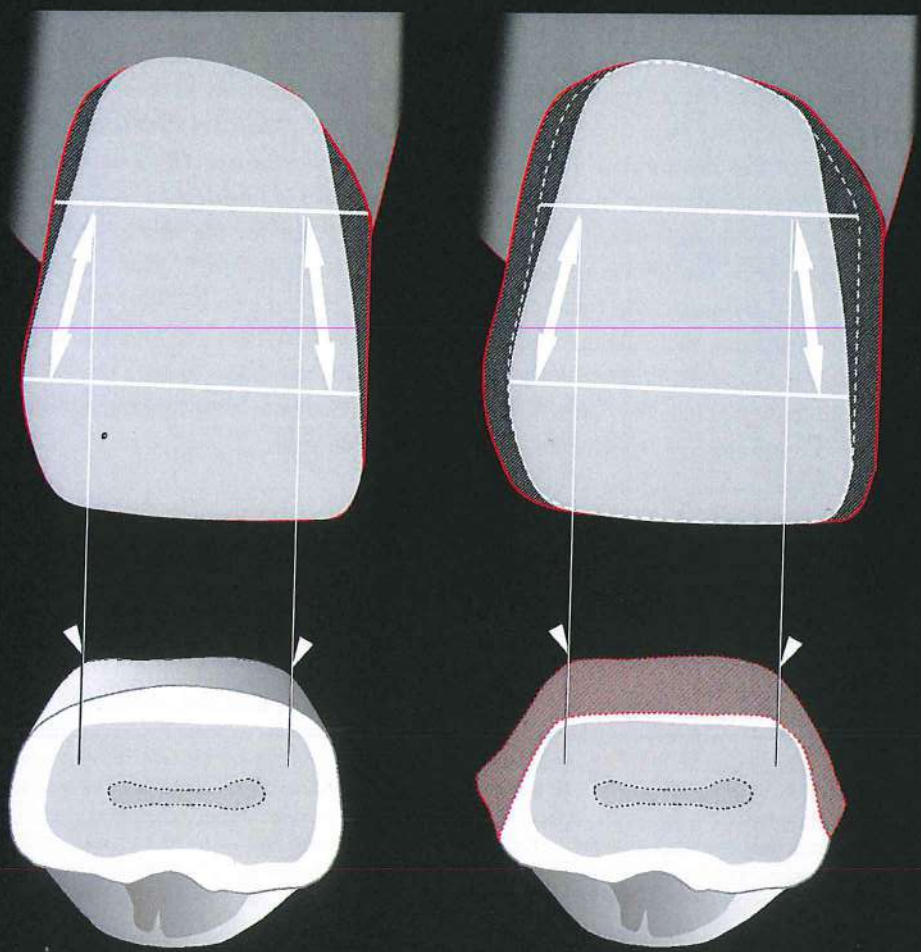

6-69d



t.me/Dr_Mouayyad_AlbtousH

## Masking effects—concept of selective intrinsic masking

Following tooth preparation, residual bleaching-resistant discoloration of enamel and dentin might still impair the final optical integration of the ceramic workpiece. Different methods have been proposed to mask discolored areas of the tooth substrate during the process of veneering. Superficial and localized defects (eg, white enamel spots) can be removed mechanically during tooth preparation. Eventual undercuts and dentin exposures created during this procedure can be immediately treated with a bonding agent (and additional application of composite resin, if needed) to reestablish an adequate preparation contour. This approach, however, remains very limited due to the poor masking ability of regular composite resins. On the other hand, application and mixing of opaque masking resins (eg, Kolor + Plus Opaque A2, Kerr) with the dentin adhesive resin is possible, but it should be limited to small surfaces because of the poor bond strength.[226] If large areas of the preparation need to be masked by a resin opaquer, the "separate layer" technique is recommended instead (apply separately and polymerize the dentin adhesive first, then apply and polymerize the resin opaquer on top of the adhesive, not mixed).[226] All of the above, however, present a significant risk: Thick layers of bonding agent or luting composite resin underneath thin veneers will increase the ceramic crack propensity (see next section "Configuration of the ceramic workpiece").

In these cases, as well as for extensive discoloration (Fig 6-70), another conservative approach is recommended: The discolored substrate is maintained and the masking effect is obtained by integrating a certain degree of opacity into the ceramic workpiece. ***The refractory die technique offers the possibility of incorporating a thin and localized layer of opaque ceramic within the deepest (first) layer of the restoration.*** Ceramics have a greater ability to mask than do resins. As illustrated in Fig 6-70c, the ceramist proceeds to selective application of an opaque ceramic liner; it should never cover the entire prepared surface, unless required by the extent of discoloration. It is particularly important to limit the area of opaque liner when cervical and marginal surfaces are not discolored; intraoral photographs (Fig 6-70b) are used as topographical maps to localize the discolored areas.

***Custom shade tabs not only help determine the exact intensity of color to mask but are also used for a "parallel stratification" (Fig 6-70c) to determine the exact thickness of opaque porcelain that is needed to reach an appropriate foundation for the rest of the stratification.***[164] The eLAB system[227] (see chapter 5, Figs 5-34 to 5-36) can also be used to create acrylic dies (eg, PMMA) with a stump shade that simulates the discoloration to help the ceramist test the final outcome in the laboratory before delivering the veneers.

**FIG 6-70 Compensation of residual tooth substrate discoloration by selective intrinsic masking.** The patient originally presented with a generalized dysplasia of enamel and existing full-coverage crowns on the maxillary anterior teeth. *(a)* Following a complex preparatory phase (see Fig 6-15), second-generation provisional crowns were placed on the maxillary teeth, while the mandibular incisors and premolars were prepared for bonded ceramics. *(b)* Several intraoral photographs of the prepared surfaces were taken during the wet stage, including an image with a custom shade guide matching the discoloration. *(c)* Another custom shade tab was also used to apply and bake masking porcelain incrementally to determine the exact thickness required for masking. *(d)* The ceramist used the photographs as topographical maps to place distinct patches of opaque porcelain wash/liner onto the refractory dies. *(e)* Translucent powders were used cervically and incisally because these areas were not discolored. *(f)* The inner surface of the final veneers displays a well-defined intrinsic opaque zone *(arrowheads)*. *(g)* Clinical situation just before the try-in. *(h and i)* Veneers were tried alternatively to control the masking effect; a neutral translucent glycerin jelly can be used as a try-in paste. (Parts *b* to *e* courtesy of Michel Magne, MDT; part *c* reproduced with permission from Magne et al.[164])



t.me/Dr_Mouayyad_AlbtousH



6-70a

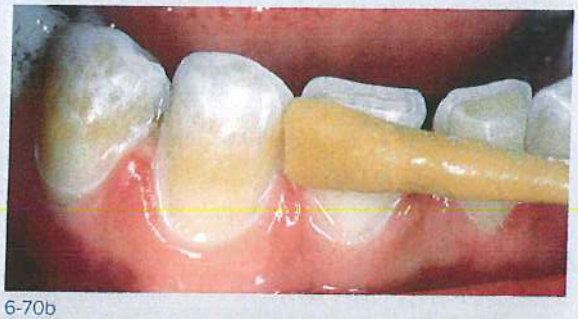

6-70b




6-70c



6-70d



6-70e

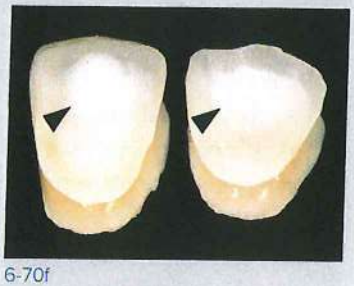

6-70f



6-70g



6-70h



6-70i



t.me/Dr_Mouayyad_AlbtousH

With selective instrinsic masking, the final veneers (Fig 6-70f) will behave optically like regular veneers, especially in their relationship with the marginal gingiva (no umbrella effect, optimal light redistribution, no opaque "white lines," etc) and simultaneously feature localized opaque zones masking only the discolored areas of the teeth.

When the selective intrinsic masking concept is followed, the porcelain restoration inherently masks the discoloration, which is noticeable at the try-in stage (Fig 6-70i). The main advantage is that regular composite resins can be used for luting (no need for opaque resins).

Selective intrinsic masking contrasts with other common techniques used to hide discoloration, for example consisting in ignoring the discoloration until the final luting of the restoration; the ceramic being devoid of masking ability, an opaque liquid resin must be painted at the inner surface of the ceramic workpiece. The result is totally unpredictable because these organic opaque liners cannot be cured before seating the restoration (preliminary curing would risk altering the fit of the restoration). As a result, the final thickness and extent of the "painted" resin is too unpredictable.

***When required, the porcelain should integrate an intrinsic opaque liner to compensate for residual discoloration of the tooth. The use of opaque luting agents should be avoided because they could be responsible for "white line" effects at the restoration margins, unnecessary uniform opacity of the ceramic workpiece, and unfavorable light distribution with the surrounding soft tissues (umbrella effect as explained in Fig 6-19d).***

When treating teeth for unsuccessful bleaching, any bonding procedures should be delayed for at least 3 to 4 weeks after the end of bleaching because oxygen remnants can inhibit the bond strength. Nightguard vital bleaching beneath existing porcelain restorations is always possible and valuable[28]; it might not change the color of the porcelain, but it can still enhance the apparent color of the teeth in the case of recurrent discoloration under contact lens type veneers.

## Preventive intrinsic masking of nonvital teeth

Nonvital teeth are characterized by their unstable color. However, because BPRs can be placed without invading the palatal surface, internal bleaching is still applicable on pulpless teeth with existing porcelain veneers. A preventive approach consists of anticipating the potential relapse by applying a uniform and moderate opaque liner to the ceramic workpiece at the time of fabrication.

To obtain uniform results when simultaneously veneering vital and pulpless teeth, the same stratification technique (including the opaque liner) should be applied to all teeth.

**FIG 6-70** *(cont) (j)* The mandibular restorations are bonded, but PMMA provisionals are still in place on the maxillary anterior teeth; a separate impression will be made to fabricate the final maxillary crowns. Despite the underlying residual discoloration on the mandibular teeth (overlay image), the restorations were bonded with a regular composite resin (not opaque); the ceramic integrates well because of the selective intrinsic masking. *(k)* No opaque liner was required at the cervical level, optimizing optical interaction with the surrounding tissues. Another case of selective intrinsic masking is presented in Fig 6-2.



t.me/Dr_Mouayyad_AlbtousH



6-70j



6-70k

## Configuration of the ceramic workpiece

### Composite resin–ceramic interactions

The structural performance of brittle dental materials cannot be directly correlated to their strength values.[228] Standard ceramic properties (flexural strength, fracture toughness) are not sufficient to explain the presence of failures in a clinical situation. Configuration factors of the restoration also play a key role, and among them, thickness might be the most relevant because the operator (either dental technician or clinician) can objectively control it. In fact, it is often asked whether there are rational guidelines defining the minimum possible thickness of an anterior BPR. At present, there are no magic numbers fixing the limit at which the ceramic workpiece becomes intrinsically too weak. The structural integrity of the restoration results from its bonding to the tooth substrate. The theoretical risk of failure must therefore include all elements of the tooth-restoration complex, including the luting composite. The term *crack propensity* instead of specific material properties has been proposed to characterize the structural performance of the global restorative system.

***Experimental-numerical trials have demonstrated that the porcelain crack propensity could be related to the respective thickness of luting composite resin (CPR) and ceramics (CER).***[62,63]

Measurements of CER and CPR were performed at different locations of the restoration (facial, incisal, proximal). When considering the ratio of these values (CER/CPR) for each location, significant differences were observed: Most cracked porcelain veneers exhibited a facial ratio below 3.0, while most not-cracked specimens had a facial ratio above this value. The CER/CPR ratio appears to have a relevant influence on the stress distribution in porcelain laminates due to both the curing contraction of the luting composite and the thermal expansion coefficient mismatch of the two restorative materials involved.



t.me/Dr_Mouayyad_AlbtousH

These important findings are summarized in Fig 6-71a, which also helps to explain which elements can directly affect the CER/CPR ratio and therefore the crack propensity—ie, a luting composite that is too thick (> 200 microns) and a ceramic veneer that is too thin (< 600 microns). Their combination logically leads to the highest risk of failure (Fig 6-71a, D). Direct implications arise for both the ceramist and the clinician:

- When the porcelain is meant to reproduce the preexisting contour of the tooth (without additive contour) or when the tooth is insufficiently prepared, the ceramic must be thinner and the CER/CPR ratio is compromised. In this situation, only a very precise internal fit of the restoration (< 100 microns) will prevent the CER/CPR ratio from dropping below the recommended value of 3.0 (Fig 6-71a, B). The importance of a controlled and uniform tooth reduction must be pointed out because a minimal and homogeneous thickness of ceramic will provide the restoration with a favorable configuration (high CER/CPR ratio). In the case of worn enamel surfaces, it is essential to reestablish the original volume of the tooth. ***The use of additive diagnostic wax-up/mock-up and mock-up–driven preparation approach is imperative in this regard because it increases the potential thickness of ceramic (Fig 6-71a, A and C).***
- It is essential to obtain a precise fit of the restoration, especially at the labial surface of the preparation, which often presents the lowest ceramic thickness. During laboratory procedures, the die spacer should be carefully applied to avoid an excessive luting composite thickness at this particular location.[61] ***The improved quality of both the preparations (smooth contours, absence of undercuts) and the final impressions will significantly facilitate the work of the ceramist, leading to minimal use of die spacer.***

## Ceramic firing shrinkage

Another critical element that can be involved in pre- and postbonding crack development of layered porcelain restorations is the firing shrinkage produced by the fusion and sintering of the glass. Linear shrinkage can reach 12% (> 30% by volume), which is a considerable amount and requires special attention during layering. Full feldspathic veneer crowns (type IV BPRs) require a particular fabrication approach due to the restricted circumferential shrinkage around the refractory die (Figs 6-71b to 6-71g). ***Significant residual tensile stresses are generated unless decoupling techniques are used.***

**FIG 6-71a Possible range of restorative material thickness and corresponding crack propensity.** The thickness of ceramic (CER) and composite (CPR) was varied to simulate four clinically relevant cases (A to D). The CER/CPR ratio (R) is given along with the average thickness of restorative materials in parentheses (in microns). The four tooth preparations are identical. Veneers A and C are thicker (900 and 825 microns, respectively) to simulate an additive contour, whereas veneers B and D were kept thin (525 and 425 microns, respectively) to reproduce the original contour of the tooth. Luting composite resin thickness is 100 microns in A and B and 200 microns in C and D. Minimum risks of failure are found for thick veneers (> 600 microns) with thin luting composite resins (< 200 microns), a configuration that maintains a high CER/CPR ratio (> 3.0).



t.me/Dr_Mouayyad_AlbtousH

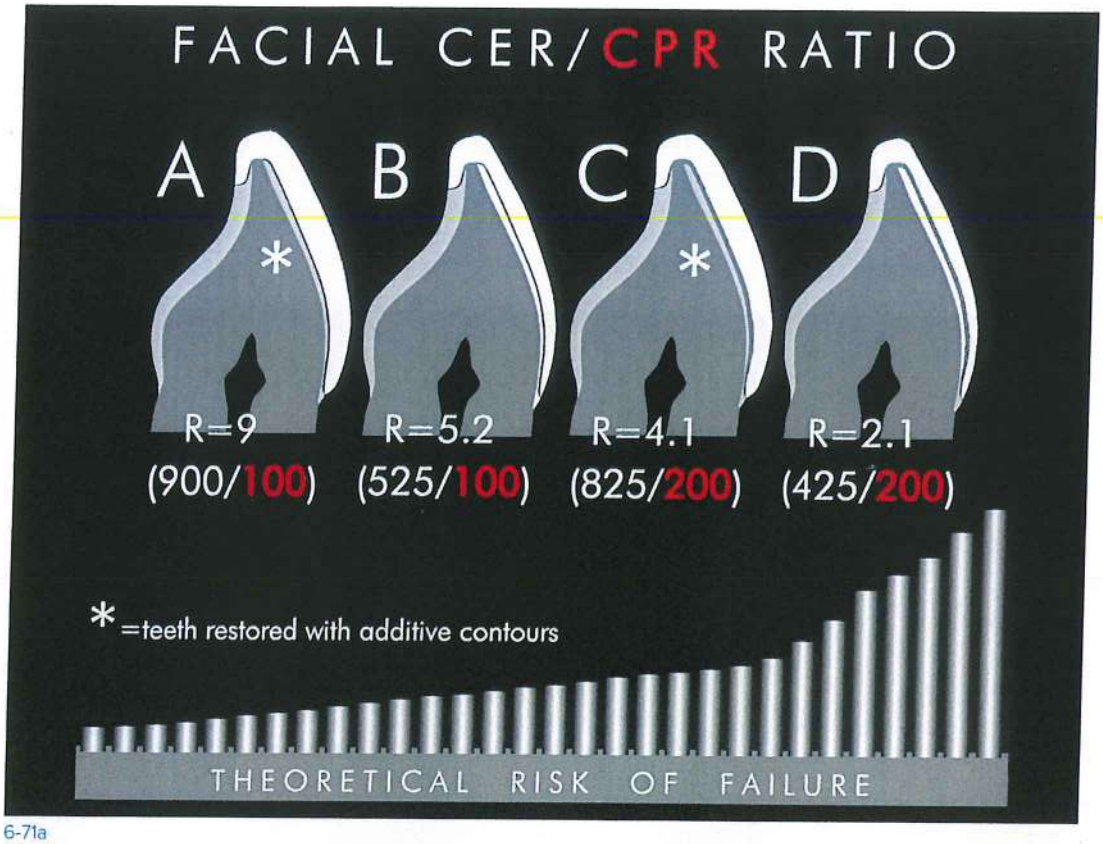


6-71a

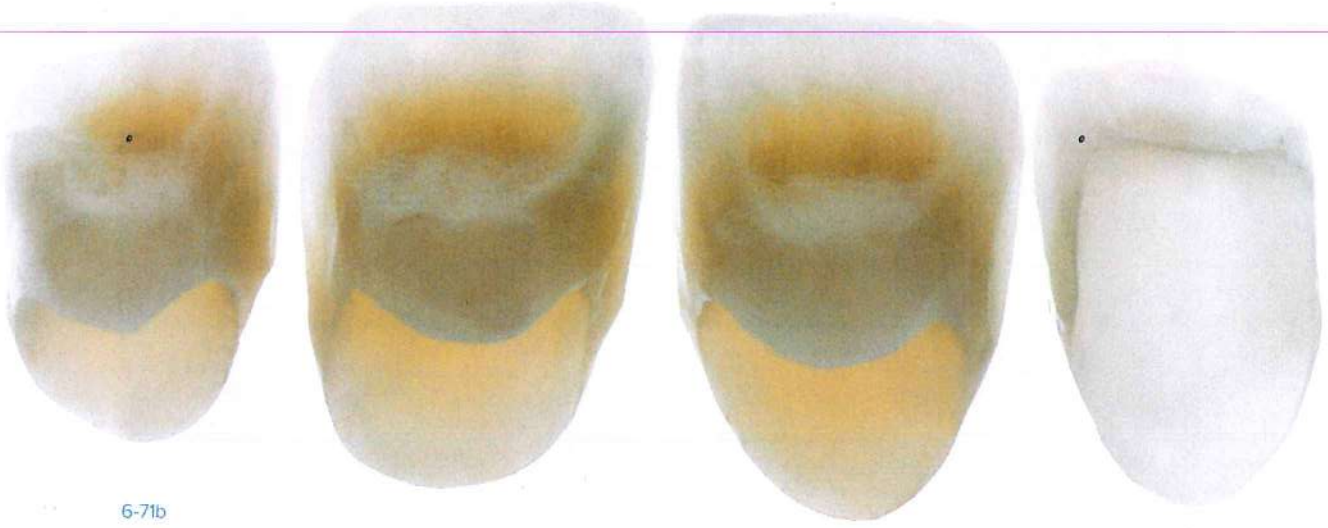

6-71b

**FIG 6-71b Prevention of firing shrinkage–induced cracks in type IV full veneer jacket crowns.** The three feldspathic jacket crowns represent a significant challenge during layering and firing (restricted peripheral shrinkage around the refractory die) compared to the type IIC labioincisal veneer *(right,* shrinkage against the refractory die).



t.me/Dr_Mouayyad_AlbtousH

***Fabrication of jacket feldspathic crowns (type IV BPRs) using the refractory die technique requires segmentation (vertical separations) of the opaque/regular dentin buildup to allow the decoupling of the firing-induced shrinkage stress (Figs 6-71c and 6-71d).***

Omitting the separation cuts would result in restricted shrinkage and crack formation during sintering. Consecutive firings are used for filling the decoupling grooves and continuing the enamellization of the restoration (Figs 6-71e to 6-71g).



6-71c

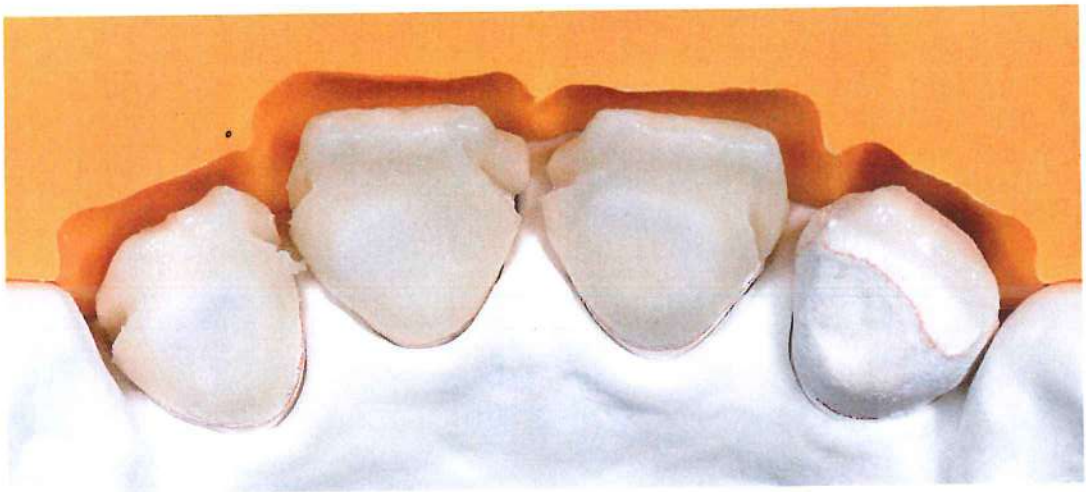

6-71d

**FIG 6-71** *(cont) (c)* The three jacket crowns are shown on the refractory dies (Creation CC porcelain and Orbit Vest refractory material) just after the first dentin firing. *(d)* Note the segmented parts (vertical separations) of the opaque dentin and regular dentin buildup to allow the decoupling of the porcelain shrinkage. Subsequent firings are used to close the gaps *(e)* and develop dentinoenamel characteristics *(f). (g)* The result features not only optical consistency but also mechanical integrity (absence of cracks) due to the careful fabrication process. The clinical aspect of this case is presented in Fig 6-17. (Parts *b* to *g* courtesy of Michel Magne, MDT, and reproduced with permission from Magne et al.[102])



t.me/Dr_Mouayyad_AlbtousH

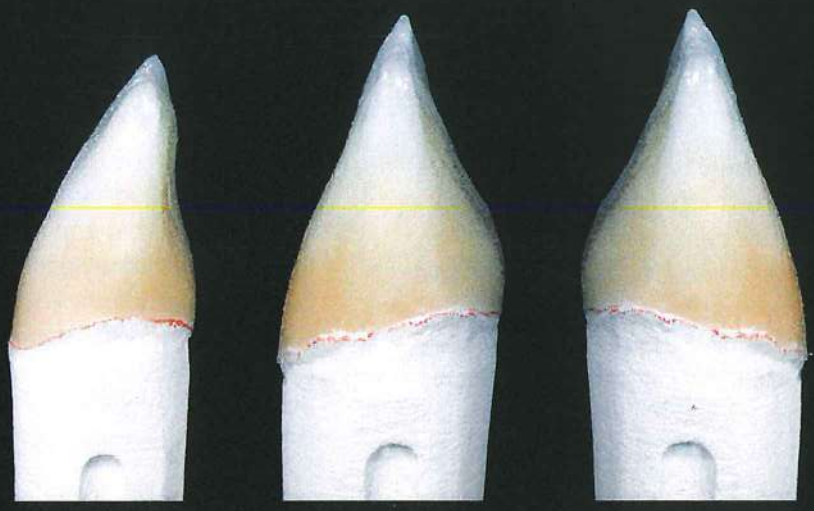

6-71e

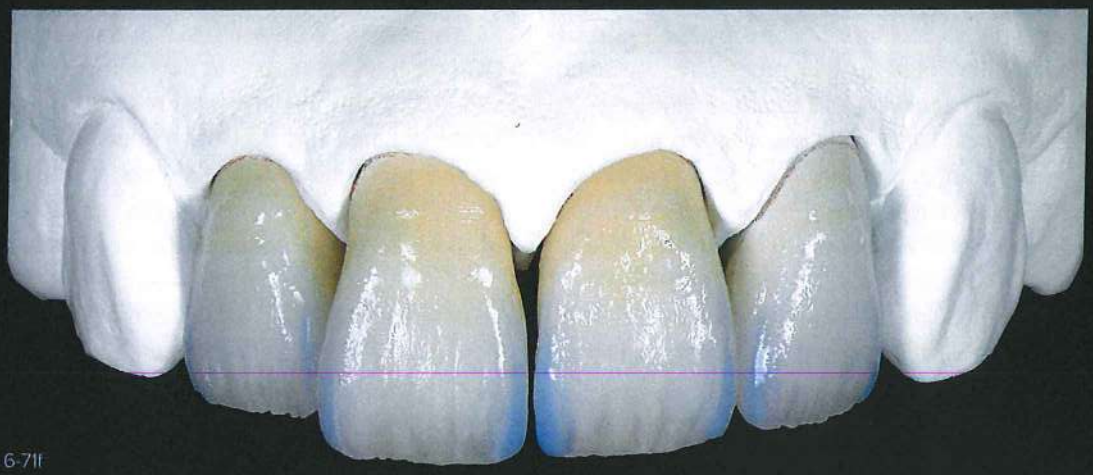

6-71f



6-71g



t.me/Dr_Mouayyad_AlbtousH

# 6.13 TRY-IN AND ADHESIVE LUTING PROCEDURES

The structural integrity of the intact tooth has been explained in part by the structure property relationship at the dentinoenamel junction (DEJ). Enamel and dentin considered alone do not have outstanding mechanical properties. Nevertheless, when assembled at the DEJ, they constitute a unique structure that can ensure optimal function and stress transfer for a lifetime. The exact same statement can be claimed for BPRs, and the DEJ sets the reference for the ceramic–to–composite resin–to–enamel/dentin restorative complex (see chapter 1, "The trinity of resin bonding," Fig 1-17g). Successful bonding of the ceramic workpiece can be obtained by the rigorous application of sequential procedures including specific conditioning of the surfaces involved—ie, the ceramic surface (etching, cleaning, and silane application) and the mineralized dental tissues (IDS, surface roughening, etching of the enamel). This chapter addresses in detail each step of the luting procedures. Additional considerations include the special approach in dentin bonding, the possible effects of composite resin shrinkage, and the porcelain crack propensity.

## Choice of luting composite resin

As far as the success of the final bonding is concerned, it relies on the adequate preparation and conditioning of the surfaces involved. This conditioning should ultimately provide a durable bond between the substrate (tooth or porcelain) and the luting composite resin. The materials and most important luting principles are similar for anterior and posterior BPRs (semi-direct and indirect) and have been presented in detail in chapter 4, section 4.7 ("Luting Procedures in Posterior Teeth"). Due to its convenience and its ability to flow and autopolymerize, the dual-cure (DC) composite resin is mistakenly preferred (especially when delivering fragments or extremely thin anterior restorations) over the solely light-curing (LC) and more viscous restorative composite resin.

> A number of studies, however, have demonstrated the superiority of LC restoratives as luting agent because of their reduced linear shrinkage and better color stability, wear resistance, strength, and seating accuracy, especially with the thermomodified luting technique (see chapter 4, pages 418–419).[208,209,229–231]

In addition, none will disagree on the fact that a sufficient working time is essential to the correct positioning of the restoration and careful elimination of excess resin. In this regard, DC cements are subject to controversy: Their self-curing ability is inversely related to their working time, and their flowability renders excess resin removal extremely difficult. Another dilemma of DC composite resins, especially in the anterior dentition, is the compromise between their degree of conversion and their color instability due to tertiary aromatic amine degradation.[229] DC cements are also unstable due to the combination of antagonistic ingredients (BPO and bis-GMA). Light activation of DC materials then becomes critical for adequate polymerization. Finally, simplified dentin bonding systems, because of their acidic monomers, may be incompatible with DC materials,[232] which can be resolved by using IDS and resin coating techniques (see chapter 4, section 4.4). Indications for DC products remain limited to extremely opaque veneers (ie, in cases of severe discoloration) and thick endocrowns.

In view of all the above, ***LC restorative microhybrid composite resins have been used as luting agent for porcelain veneers and for ceramic inlays for over 25 years***[233,234] (Fig 6-72). It was demonstrated that DC resins had no advantages vs solely LC products with respect to polymerization rate, provided that each proximal restored surface is cured for at least 120 seconds at > 600 mW/cm$^2$.[233] This luting protocol has been used successfully for about



t.me/Dr_Mouayyad_AlbtousH

25 years, even in cases of anterior BPRs with extensive incisal edge spans of ceramic.[24] Using higher-intensity modes (eg, 800–1200 mW/cm²) and reduced polymerization times of 60 to 90 seconds per surface are sufficient especially in the case of anterior BPRs, for which access with the light is much more direct. For contact lens veneers, a rather neutral composite resin should be selected. ***For autonomous veneers, either enamel (eg, Herculite XRV) or dentin (eg, ENA HRi) shades can be chosen, depending on the composition and brand, but usually a shade matching the dentin base of the porcelain is used; dentin shades will tend to sustain better the brightness of the restoration but lack opacity for masking purposes (masking should be achieved by the restoration alone, not the luting agent).***

Even though they might be included in the same class, there are large differences in the viscosity of restorative composite resins.[235] The viscosity of the composite resin decreases as temperature increases. However, each brand reacts in a different way, with a decrease ranging from 40% to 92%.[236] Some brands even seem to start polymerizing when stored more than 15 minutes in the heating device.

***Hence, many composite resins are not appropriate for luting as their viscosity is not optimized even after preheating.[237] Traditional microhybrid materials should be favored. Other materials may not be indicated if they include large prepolymerized resin complex, clusters, or macroparticles*** *(see filler types and classification of materials in chapter 3, Fig 3-32 and Table 3-3).*



6-72a


6-72b


6-72c

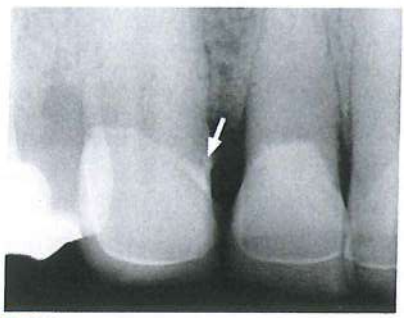
6-72d


6-72e

**FIG 6-72 Light-polymerizing restoratives as luting agents.** *(a)* Regular light-curing restorative materials can be used as luting agents for anterior BPRs. *(b)* A material can be tested for quality and film thickness consistency by pressing it between two glass slides (electronic caliper can be used to measure the thickness with and without composite resin). *(c)* Some batches may present numerous air voids, which make them unsuitable for luting anterior veneers. *(d and e)* The use of radiopaque composite resin and adhesive resin (here OptiBond FL) is essential to be able to detect excesses and resin flashes on postoperative radiographs and remove them with scalpel blade #12.


t.me/Dr_Mouayyad_AlbtousH

## Try-in and preparatory steps

Final insertion of the ceramic piece must be preceded by a meticulous try-in (Fig 6-73). Following removal of the provisional, a soft silicon cup (Hawe-Neos) and a fluoride-free abrasive paste can be used to clean the prepared surfaces. When provisionals have been secured by spot-etching, a scaler or abrasive disks (at low speed) must be used to remove the adhesive resin from the spot-etched area of the tooth. The following try-in sequence is recommended:

1. The restorations must first be checked on their original stone dies (seating, marginal fit) and solid model (interdental contacts and seating sequence).
2. Each restoration is then individually placed in situ to check the adaptation with an explorer. Note that incomplete seating is rarely due to internal fit problems but typically results from interdental interferences (strong contact, debris, etc).
3. All restorations are then placed in adjacent groups to verify proximal relationships.
4. Once fitted together in situ, the restorations can be shown to the patient with a mirror for the verification of esthetic attributes and to make sure that the diagnostic template has been respected. An additional approach is to take photographs and have the patient evaluate the photographs. Mirrors display an inverted image of the smile, which may lead to misunderstanding between the clinician and the patient regarding esthetic perceptions (see "Beware of the mirror" in chapter 2, page 140). At no moment should the patient be allowed to totally close the bite (risk of fracture).

***Teeth should be kept wet during the entire try-in, because dehydration of reference teeth can alter the color evaluation. Glycerin, because of its refraction index of 1.45 (enamel is 1.62) should be used to seat the veneers and establish optical continuity with the tooth. No shaded try-in paste is required considering that autonomous or masking porcelain workpieces should feature sufficient intrinsic optical properties.*** Porcelain surfaces contaminated with try-in products must be carefully cleansed with resin solvents (acetone, ethanol, methanol, or methylene chloride) before starting adhesive conditioning.[238,239]

***Cleaning the fitting surface of thin ceramic restorations by air abrasion with aluminum oxide particles is absolutely contraindicated because it may cause damage and postbonding cracks*** ***(see example in chapter 7, Fig 7-9)******. Only 50-micron glass beads at 22 psi/1.5 bar should be used.***

When it is fabricated with the refractory die technique, the veneer cannot be easily corrected for color. Hence, the restoration should be finished/polished as much as possible before the first try-in while it is still attached to the refractory die (no bisque bake try-in). In most cases, the try-in procedure is a confirmation of the diagnostic mock-up/provisional design and is immediately followed by final luting.

> Beware the insertion sequence of a group of restorations, which must be rehearsed on the solid model, especially in presence of overlapping teeth. Once bonded to a tooth slightly shifted buccal, a veneer might prevent the insertion of the next veneer on a more palatally placed tooth.

**FIG 6-73 Try-in and isolation.** In cases of spot-bonding, removal of the provisionals *(a)* reveals unfilled resin covering the internal surface of the veneer except for the spot-etched area *(arrowhead in b)*; the unfilled resin must be removed at the corresponding location on the tooth surface using a scaler or abrasive disks at low speed *(c)*. *(d)* Tooth preparations are then cleaned with a fluoride-free abrasive paste and a rubber cup. *(e to g)* The restorations must first be checked on the stone casts individually, then in adjacent groups. *(h to k)* The same procedure is carried out in the mouth.



t.me/Dr_Mouayyad_AlbtousH



6-73a

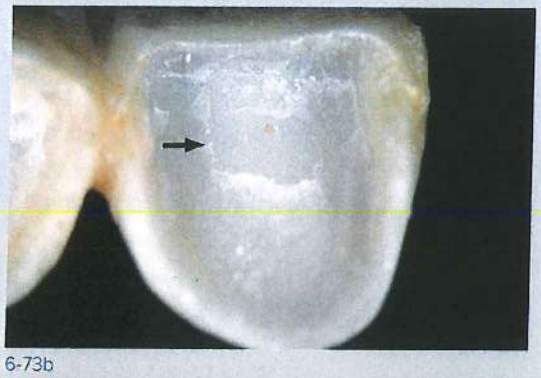

6-73b



6-73c



6-73d



6-73e



6-73f



6-73g



6-73h



6-73i



t.me/Dr_Mouayyad_AlbtousH

> Try-in always results in some kind of chemical contamination of the surfaces to be bonded and thus a potential reduction of the future bonding; consequently, ceramic and enamel surface conditioning should be systematically carried out after try-in, not before.[197]

As for all adhesive techniques, the definitive insertion of the restorations has to be preceded by an optimal isolation of the working field using rubber dam or at least with deflection cords if the application of rubber dam proves extremely difficult. A last try-in must be carried out under rubber dam. Additional information for final seating can be found later in this chapter under the section "Interdental adjustments during luting procedures." The entire bonding process is performed after segments of transparent matrices and interdental wedges have been placed. The latter precaution protects neighboring teeth from the etchant, guides and facilitates the insertion of the restoration to its final position, and ultimately prevents the accumulation of the excess luting composite resin in the interproximal area. An alternative technique is to use Teflon tape to wrap and protect the neighboring teeth (Figs 6-74a and 6-74b).

***For optimal control of all procedures, restorations/preparations are ideally conditioned and bonded one tooth at a time. Two-by-two bonding, however, while more challenging, is also possible with modified clamps (Fig 6-74c).***



6-73j



6-73k

**FIG 6-73** *(cont)* Seating of BPRs must be evaluated by trying the restorations in adjacent groups *(j and k)*. Fine adjustments, however, must be carried out after placement of rubber dam. *(l)* The latter is placed over the teeth to be bonded, including at least one additional tooth on each side of the related segment; luting of four incisors implies placing rubber dam from canine to canine and clamping the first premolar. *(m and n)* An optimal operatory field can be obtained by placing an additional clamp (eg, #212 Hu-Friedy) on the first tooth to be bonded *(solid rectangle in m)*; the clamp is moved to the next tooth as cementation proceeds *(dotted rectangles in m)*. *(o)* Following each delivery, the next restoration is tried again for final adjustments; *(p)* wooden wedges and a matrix are then inserted to protect neighboring teeth from contamination by chemicals and luting agents. The same case can be seen in Figs 6-48 (final impressions) and 6-53 (provisionals). (Patient treated in collaboration with Dr Nikolaos Perakis, Bologna, Italy.)

**FIG 6-74 Alternate methods for luting.** *(a and b)* Isolation of neighboring teeth during restoration delivery can also be achieved with Teflon tape *(a*, etched preparation; *b*, restoration seated before removal of excess composite resin). Some teeth have marked scalloping of the gingival outline that requires bending of the clamp for better adaptation (overlay image). *(c)* Two-by-two delivery is much more challenging but also more time-efficient. It is possible by using modified clamps (overlay image, clamps #9 and #212, opposite sides sectioned).



t.me/Dr_Mouayyad_AlbtousH



6-73l

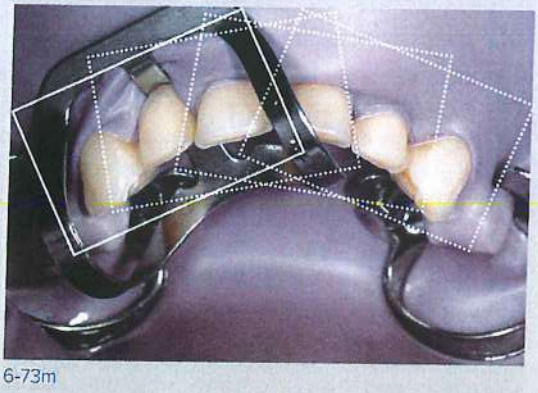

6-73m



6-73n



6-73o

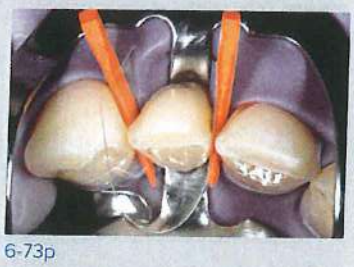

6-73p



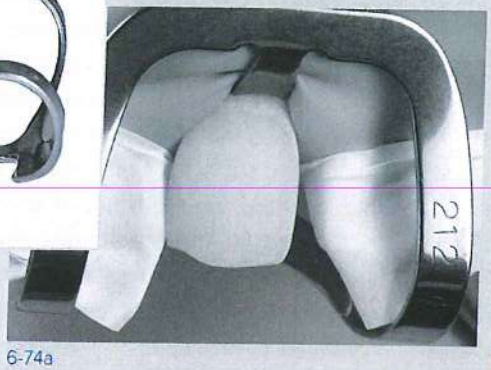


6-74a

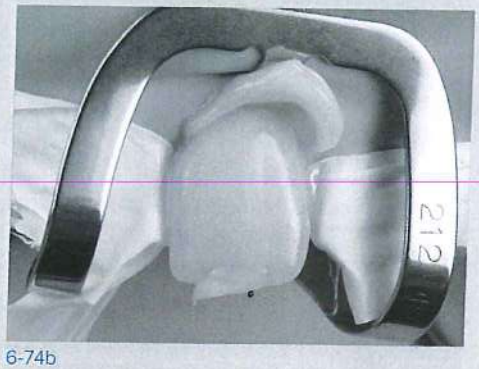


6-74b








6-74c



t.me/Dr_Mouayyad_AlbtousH

## Conditioning of the porcelain surface

***It has been clearly established and confirmed that the combination of micromechanical interlocking (hydrofluoric acid [HF] etching) and chemical coupling (silanization) is required to obtain the most effective and durable resin bond to feldspathic porcelains.***[240–242] Careful handling of the restoration is required during the conditioning steps. Soft periphery wax can be used to hold the ceramic workpiece at the tip of a flat instrument (Fig 6-75c), for example an old large amalgam condenser.

### Micromechanical interlocking: HF acid etching

The standard protocol for porcelain is to apply 9.6%–10% HF for 90 seconds to the inner surface of the restoration (Fig 6-75). This procedure has to be performed under strict protective measures comprising rubber gloves, mask, and protection glasses. ***Other types of ceramics require different acid concentrations and etching protocols (see chapter 4, Table 4-5).***

Caution is advised while rinsing the HF because HF gel attacks quartz, silicate, and borate glasses as well as sanitary ceramics and various metals and alloys (eg, high-grade steel). Nickel, copper, polyethylene, PVC, and Teflon are resistant to HF. The following neutralization protocol must be used: *(1)* Fill half a plastic cup with water, and rinse the HF etching gel from the restoration into the cup. *(2)* To neutralize the diluted solution of etching gel and water, add the neutralizing agent (Ivoclar Neutralizing Powder or sodium carbonate) and let it react for 5 minutes. One measuring spoon of IPS Ceramic Neutralizing Powder is suitable to neutralize the quantity of IPS Ceramic Etching Gel required for a large mesio-occlusodistal inlay. *(3)* After the reaction



6-75a

time, pour out the neutralized solution and rinse with copious amounts of water.

Due to the abundant glassy matrix surrounding the crystalline phase, feldspathic porcelains offer an ideal substrate for HF acid conditioning: Dissolution of the glassy matrix ultimately leaves retentive holes and tunnels between the acid-resistant crystals (Fig 6-75i). Postetching cleaning, especially ultrasonic cleaning, is essential to enlarge and enhance access to these undercuts.[98] Energy-dispersive spectroscopy analyses have shown that the crystalline precipitates on the etched surfaces, which are not readily soluble in water, are the reaction products of Na, K, Ca, and Al. The precipitates remain on the surface after acid application; they can only be removed by ultrasonic cleaning and cannot be removed by rinsing.[99,100,243]

***After rinsing (Fig 6-75c), one must eliminate ceramic residues and eventual remineralized salts[97] (Fig 6-75d). One method is precleaning with a microbrush and phosphoric acid for 30 seconds, followed by immersion in distilled water or 95% alcohol in an ultrasonic bath for 2 to 4 minutes (depending on the amount of residues).***

**FIG 6-75 Etching and cleaning of the porcelain workpiece.** *(a)* All acid must be rinsed off the restoration in a separate plastic cup containing neutralizing powder (courtesy of Ivoclar Vivadent). *(b and c)* HF 10% is applied to the ceramic internal surface for 90 seconds and rinsed; the ceramic workpiece can be easily handled using a flat-end instrument (eg, large amalgam condenser) and periphery wax. *(d and e)* Even abundant rinsing proves insufficient to clean the porcelain, which is often contaminated by a white residue or deposit (scanning electron micrograph, original magnification ×1,200). *(f and g)* The latter are selectively removed by placing the restorations in an ultrasonic bath (in 95% alcohol or distilled water) for 2 to 4 minutes.



t.me/Dr_Mouayyad_AlbtousH




6-75b

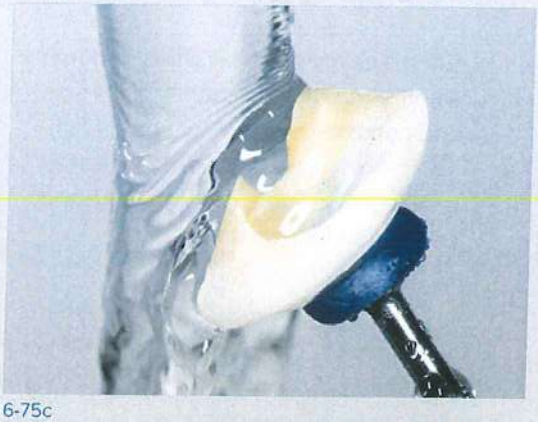

6-75c

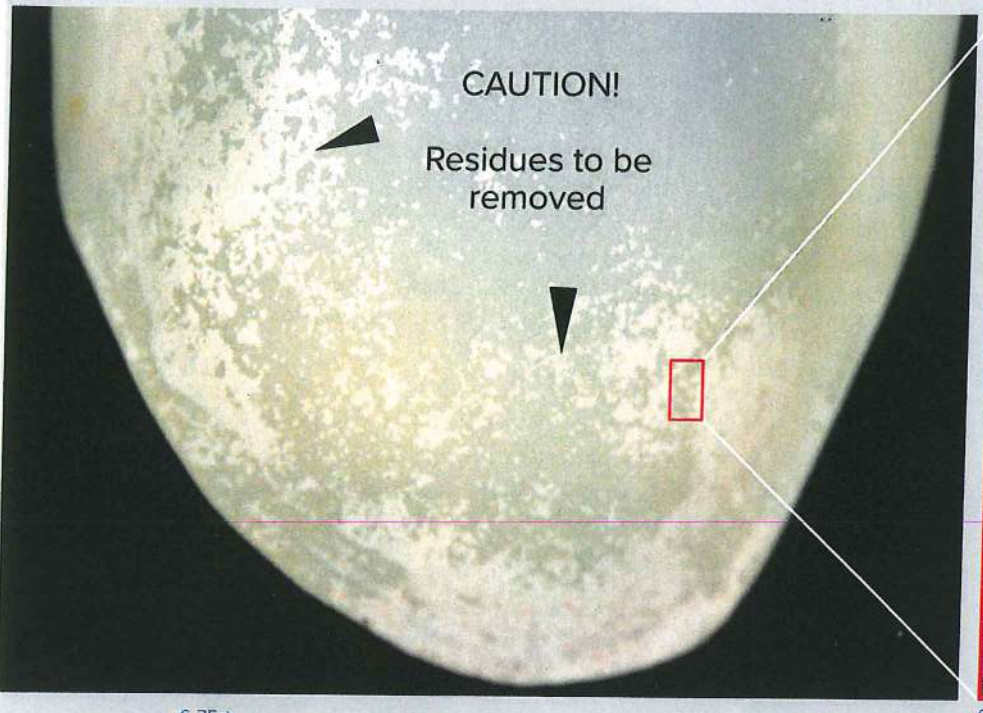


6-75d



6-75e

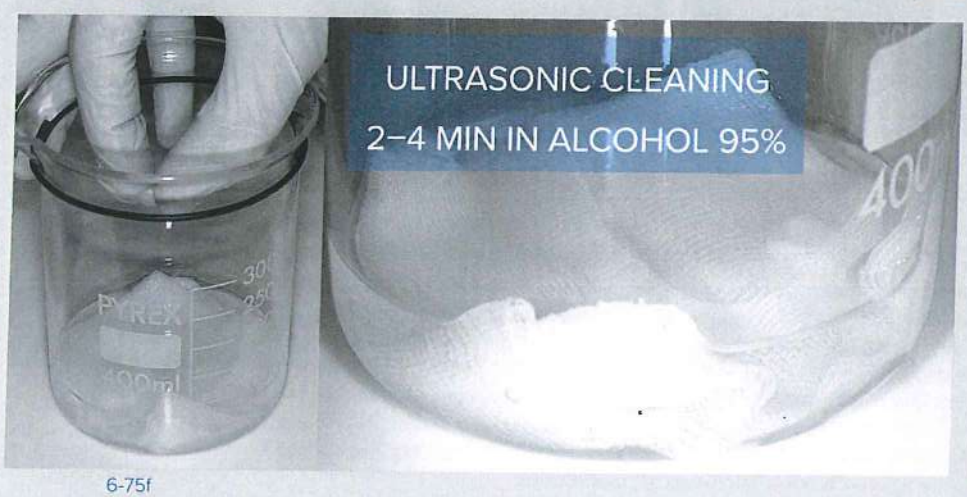


6-75f



6-75g



t.me/Dr_Mouayyad_AlbtousH

Clinicians must be extremely prudent when using different brands of HF acid and conditioning other types of ceramics. The resin bond strength is controlled primarily by ceramic microstructure and ceramic surface treatment.

Different types of ceramic respond differently to the same acid concentration. Other etchable types of materials are discussed in chapter 4, section 4.7 and Table 4-5. In addition, for a given HF acid concentration, different brands of acids may have different compositions and may not be similarly effective on a given type of ceramic.[244] ***When in doubt, a common-sense approach is therefore to use the HF acid of the same brand of the ceramic, when available. HF conditioning is unable to generate a retentive surface on crystalline ceramics with limited or inexistent glassy matrix (eg, alumina and zirconia reinforced ceramics).*** Surface-modification techniques are required for these ceramics to present decent resin bond strength. Some approaches generate positive mechanical interlocking, for example through the sintering of silica particles[245] or by selective infiltration etching.[246] Others aim at chemical modifications by silicoating and silane application, or by alumina air abrasion plus chemical bonding with organophosphate monomers such as found in MDP-containing resins.[247]

## Chemical coupling—silanization

To avoid contamination, the final try-in of the restoration must always precede HF etching and subsequent silanization. Because of the silica content of feldspathic porcelain, a chemical bond can be potentially achieved between the porcelain and the luting resin. This bond requires coupling molecules, ie, g-methacryloxypropyl trimethoxysilane (3-MPTMS), also called *organofunctional silanes*. They are typically used as adhesion promoters between inorganic substrates and organic polymers (Fig 6-76a).

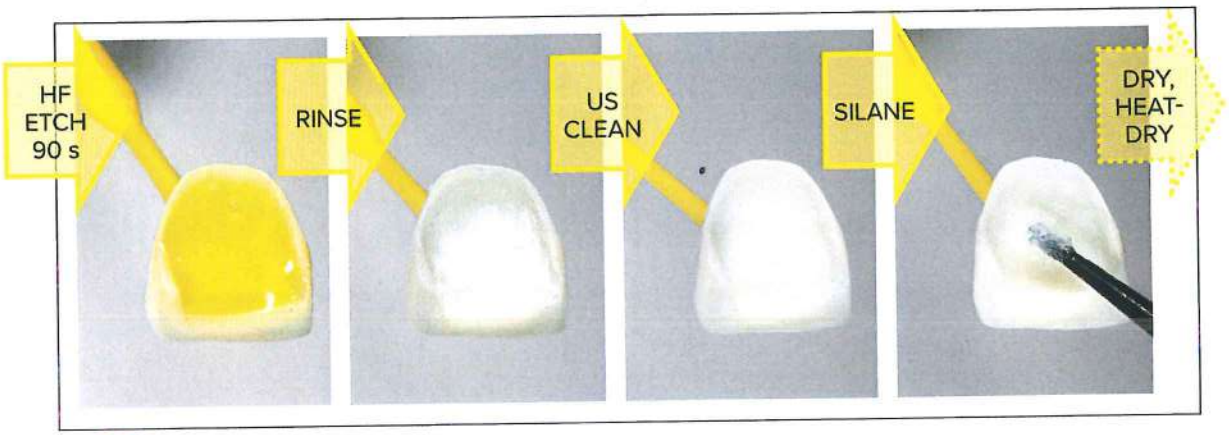


6-75h

**FIG 6-75** *(cont) (h)* This veneer was etched with HF 9.6% for 90 seconds *(left)* and rinsed abundantly. Note the strong white residues (crystalline precipitates) that are not readily soluble in water *(center left)* but require removal by ultrasonic (US) cleaning in distilled water or 90% ethanol. Note the clean sonicated surface *(center right)* ready for silane application and heat-drying *(right)*. The silanated/dried surface should still have a dull/matte finish. *(i)* Scanning electron microphotographs of feldspathic porcelain (original magnification ×1,200): *(left)* high-magnification view of porcelain surface after simulated removal of refractory material by microparticle air abrasion with glass beads (50-micron distance at 22 psi). The retentive character of this surface is insufficient, and no deep undercuts are observed. *(right)* Same porcelain surface after etching with 10% HF for 90 seconds and ultrasonic cleaning. The surface is highly retentive and shows numerous connections ("tunnels") between microporosities.



t.me/Dr_Mouayyad_AlbtousH

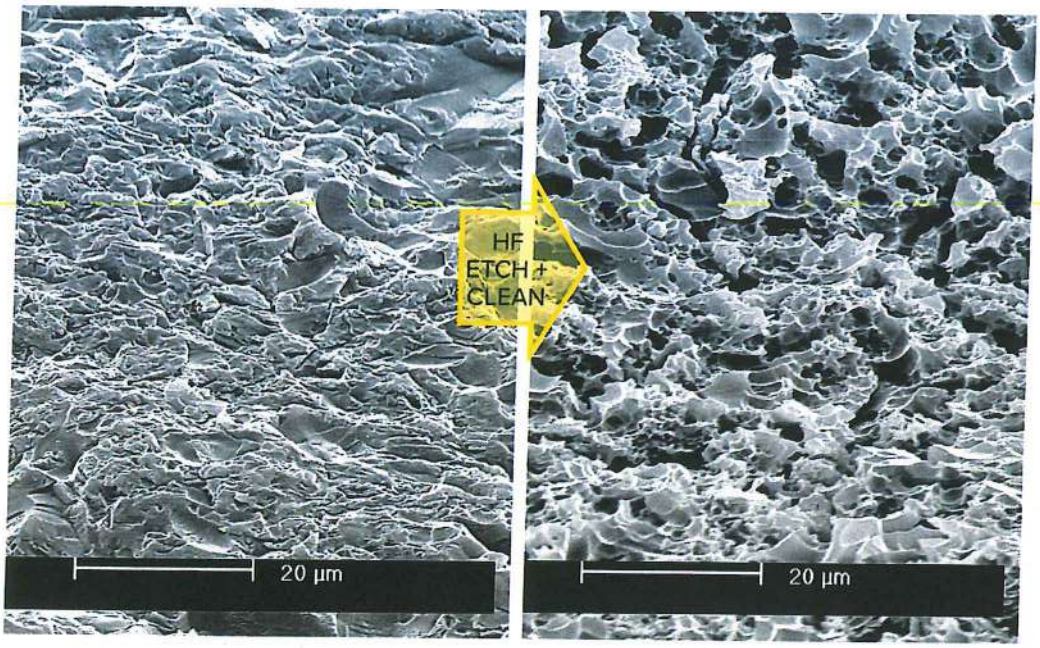


6-75i

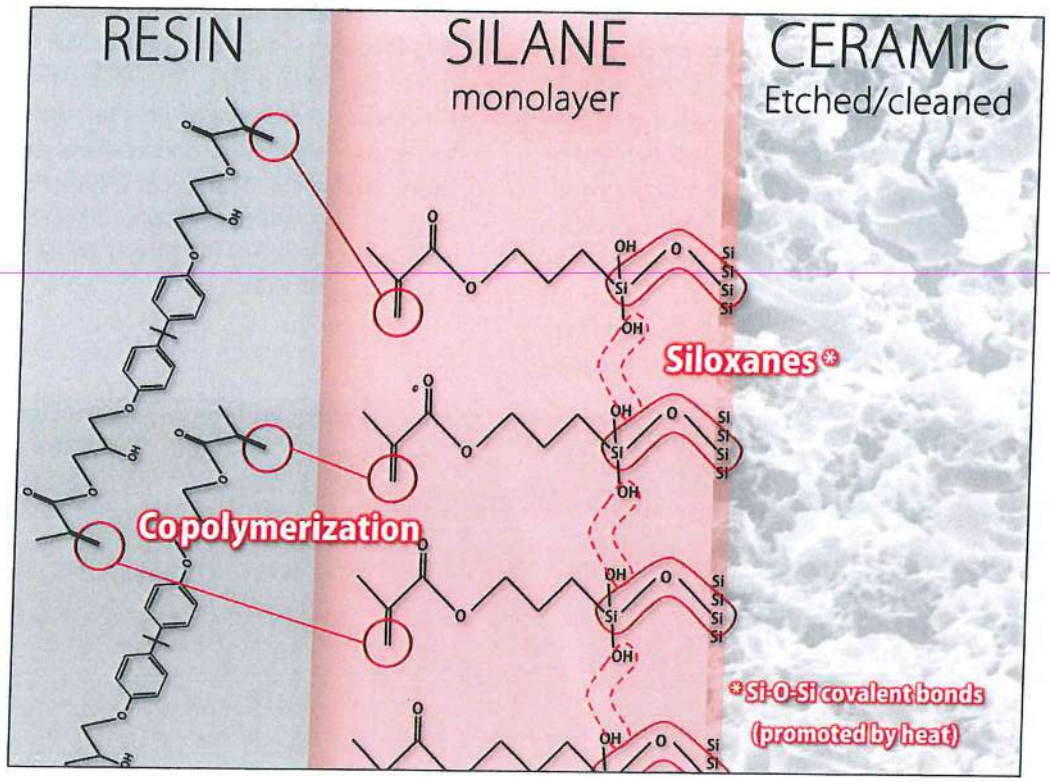


6-76a

**FIG 6-76 Resin-to-porcelain chemical coupling.** *(a)* 3-MPTMS *(center)* is a bipolar molecule. Its methacryloxy end (hydrophobic, organic) can copolymerize with the organic resin matrix (eg, bis-GMA, *left).* The reaction is initiated by the initiator in the adhesive resin. The other end of the silane molecule features hydroxyl groups (hydrophilic) that will react with each other and with the hydroxyl groups at the surface of the porcelain to form siloxane bonds (Si-O-Si). Hot air promotes that reaction. More details about this reaction are explained in *c* and *d*. Through the silane, the hydrophilic surface of the etched porcelain is turned into a hydrophobic surface with improved wettability for the adhesive resin.



t.me/Dr_Mouayyad_AlbtousH

Silane-treated porcelain offers an improved resin wettability as well as methacrylate groups that can form a bond with the methacrylate groups in the resin (Fig 6-76).

***Ceramic silanization is a rather delicate and sensitive procedure and must be performed in accordance with scientific and established guidelines[248,249]:***

- Silanes can be purchased in a nonactive (two-bottle systems, indicated for nonfrequent users) or active state (one-bottle system, indicated for frequent users).
- Silane solutions contain a high volume of solvents (90% ethanol or acetone); inadequately sealed or opened containers will allow rapid evaporation and affect the efficiency of the silane. In two-mix products, one bottle contains an acid (eg, ~5% acetic acid solution), and the other contains a nonhydrolyzed silane to be activated ahead of time (hydrolysis via the acid). Some products require an activation delay to ensure hydrolysis (always check the manufacturer's instructions).
- In an aqueous environment, activated silanes will react with themselves and precipitate out of solution. Hence, one-bottle systems (prehydrolyzed silanes) have a shorter shelf life. Shelf life is improved by pH adjustments (4.0 to 5.0) and refrigeration but may be as short as 6 to 12 months. Clear syringes allow for checking the clarity of the preactivated solution (Fig 6-76b).
- **Application method:** After drying, the etched ceramic surface is covered with the active silane solution. ***Optimal application implies obtaining a monomolecular layer of silane and avoiding the formation of excesses (loosely bound polysiloxane oligomers; Fig 6-76d). Short application times (20–40 seconds) followed by air-drying and heat-drying will unlikely result in an excess: The restoration should still look dull/matte even after the silane is applied and dried.*** High concentrations of silane as well as longer (> 60 seconds) and repeated applications may render the restoration surface still shiny even after heat-drying. This shiny excess reveals that further steps may be required to remove the loosely bound silane oligomers. Ultrasonic cleaning in ethanol bath or by rinsing with boiling water have been suggested to remove the excess silane after heat-drying.[243,249–253]

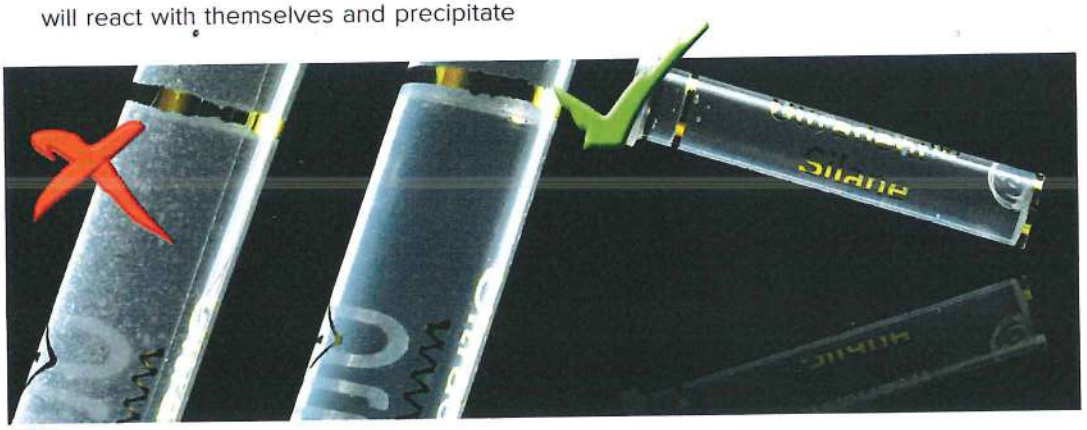


6-76b

**FIG 6-76** *(cont)* Silane chemistry. *(b)* This commercial prehydrolyzed silane (Silane, Ultradent) is conveniently provided in a clear syringe, allowing one to detect that this specific syringe may have been exposed to heat or solvent evaporation *(left)*: There is a cloudy appearance due to the presence of self-condensed molecules. The new syringe of prehydrolyzed silane *(center and right)* looks totally clear and is appropriate for use. Refrigeration prevents condensation and improves the shelf life. *(c)* The active silane (mixed or prehydrolyzed) presents silanol groups (-OH) that can react (condensation reaction) by branching molecules with each other and with the hydroxyl (-OH) groups of the HF-etched porcelain surface.



t.me/Dr_Mouayyad_AlbtousH

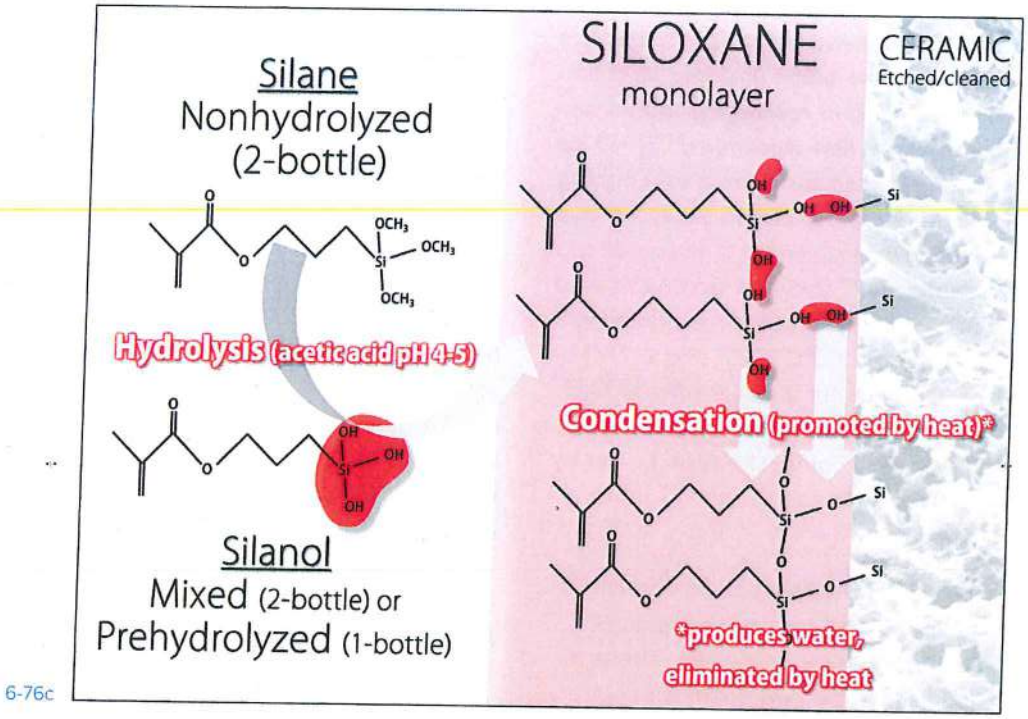


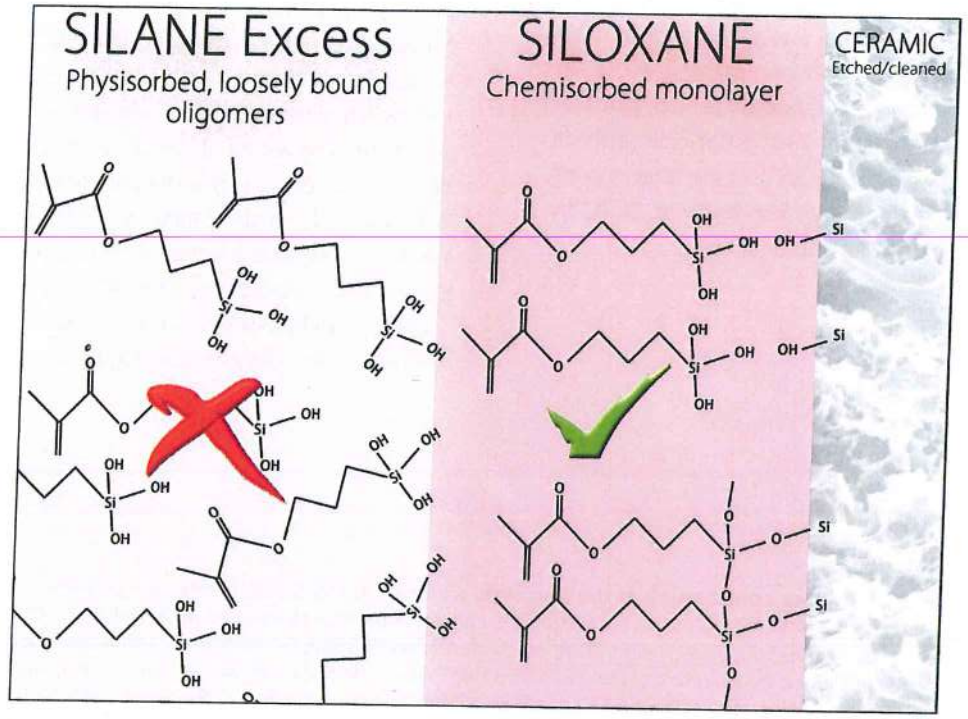


**FIG 6-76** *(cont)* The condensation reaction is promoted by heat (formation of the siloxane bond Si-O-Si) and produces a molecule of water. The role of hot air is multiple: It *(1)* promotes the siloxane bonds (cross-linking and densification), *(2)* eliminates the water, *(3)* eliminates the solvents, and *(4)* decreases the thickness of the silane film. *(d)* Excessive amounts of silane (eg, repeated/long application times) will result in the formation and condensation of silane molecules to form small oligomers on top of the chemisorbed (branched and covalently bonded) monolayer. Following heat-drying, the shiny excess of physisorbed, loosely bound oligomers, when present, should be removed by rinsing with boiling water or ultrasonic cleaning in ethanol, followed by heat-drying again.



t.me/Dr_Mouayyad_AlbtousH

***The heat treatment will significantly enhance the effect of the silane (improve its chemical reactivity and resistance to hydrolysis, decrease film thickness)[197,253,254] by promoting the condensation of the coupling molecules onto the ceramic surface and eliminating the resulting $H_2O$ molecules and other solvents.[231]*** This step can be achieved in 1 minute by placing the restoration in a dry furnace at 100°C/212°F (Fig 6-77e) or with a hair dryer for 2 minutes (Fig 6-77f).[197] The restorations can also be left to dry in the Calset unit (composite resin heater by AdDent) for 5 minutes.

Silane coupling will not be efficient with non–silica-based restorative materials (alumina, zirconia, or metals). Those materials must be pretreated with silicoating techniques (eg, air abrasion with CoJet, 3M) so that siloxane bonds can be formed between silane and the silicoated restorative materials. Another option is to use organophosphate monomers (eg, MDP in the form of primers or cements like Panavia 21 TC by Kuraray) instead of silanes.

### Application of adhesive resin and luting composite resin (preheated restorative)

LC restorative composite resin must be prepared in advance by preheating in Calset (AdDent) or a similar device (Fig 6-77a). The restoration is tried again one last time under rubber dam (6-77b) before conditioning the fitting surface as explained before (Figs 6-77c to 6-77g). A composite resin pad (Fig 6-77h) with a protecting shield (Vivapad, Vivadent) is used to place all light-sensitive products (composite resin, adhesive, etc). The final preparation of the ceramic surface is obtained by applying one coat of adhesive resin to the fitting surface of the restoration (Figs 6-77i and 6-77j), followed by gentle thinning with air. A homogeneous bulk of the preheated microfine hybrid composite resin is then applied to the fitting surface. Particular attention should be paid to avoid the incorporation of air bubbles between composite resin and ceramic. This would create areas of light absorption (gray spots), which can be visible after the cementation. Use of composite resins conditioned in compules (Figs 6-77k and 6-77l), when available, can prevent these problems. The veneer (loaded with the composite resin) can be stored under the light shield (Fig 6-77m) only for a short time to avoid cooling of the resin. For time efficiency, all the aforementioned steps should be performed by the dental assistant while the tooth preparation is being conditioned by the clinician (Fig 6-78).

**FIG 6-77 Step-by-step conditioning of the porcelain surface.** *(a)* The Calset device allows preheating of the syringe and compules. Some materials should not be preheated more than 15 minutes. *(b)* A final check of the restoration's seating is carried out under rubber dam, which must precede surface conditioning: 90-second etching with 10% HF acid *(c)* followed by abundant rinsing and ultrasonic cleaning. Precleaning with phosphoric acid and a brush is optional to remove large debris. The etched porcelain surface must be dried before the silane is applied. *(d and e)* A few layers of hydrolyzed silane should be applied and should not result in the surface turning shiny upon drying. A shiny surface would indicate that an excessive amount of silane was applied. Complete evaporation of the solvent and other contaminants is obtained by heat-treating the porcelain workpiece at 100°C/212°F using a hair dryer for at least 2 minutes *(f;* with the veneer inside a tea ball) or a small calibrated portable furnace for 1 minute *(g;* eg, Coltène DI-500) or in the Calset for 5 minutes. *(h)* Further steps absolutely require a mixing pad with a light shield. *(i and j)* The etched and silane-treated porcelain is then coated with low-viscosity adhesive resin (eg, OptiBond FL Adhesive); the excess adhesive resin can be air-thinned but not polymerized. *(k and l)* It is immediately followed by the loading of the preheated composite resin. *(m)* The loaded porcelain workpiece is safely carried near the tooth under the light shield.



t.me/Dr_Mouayyad_AlbtousH

PREHEAT COMPOSITE RESIN 68°C/155°F FOR 15 MIN




6-77a




Compules

TRY-IN

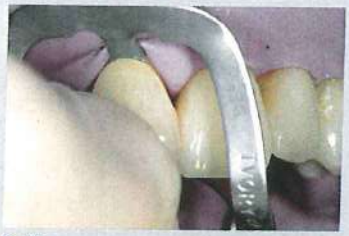

6-77b

HF ETCH + CLEAN



6-77c

SILANIZATION



6-77d

+ AIR BLOW



6-77e

HAIR DRYER 2 MIN



6-77f

or OVEN 100°C 1 MIN



6-77g

APPLICATION OF ADHESIVE RESIN




6-77h

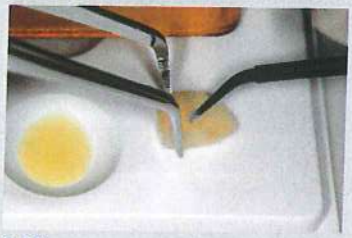

6-77i



6-77j

APPLICATION OF COMPOSITE RESIN



6-77k



6-77l



6-77m



t.me/Dr_Mouayyad_AlbtousH

## Conditioning of the tooth surface

In the early 1990s, different clinical situations were distinguished. When 80% to 90% of the prepared surface was located within the thickness of enamel, surface conditioning was limited to a 30-second etching procedure with 37% phosphoric acid (eg, Ultra-Etch, Ultradent), followed by rinsing and drying. In the presence of a significant dentin exposure, however, a dentin adhesive had to be applied immediately and strictly according to the manufacturer's instructions, which included light-polymerizing the adhesive layer and risking the incomplete seating of the restoration. As already mentioned in chapter 4 (section 4.4: "Immediate Dentin Sealing"; see also section 6.9), such a situation must be anticipated and solved at the time of tooth preparation because a wide array of problems can be prevented by the immediate application and polymerization of the dentin adhesive, prior to taking the final impression.[29,95,135,173,174] This precaution not only results in an enhanced bonding and protection of the pulp-dentin complex but also prevents tooth sensitivity during the provisional phase.

As the patient returns for try-in and final bonding of the restoration, the tooth preparation, including the surface of the existing adhesive, must be meticulously cleansed with pumice. Filled adhesive (eg, OptiBond FL) forms a consistent resin coating that can be efficiently "reactivated" (more than 3 to 7 weeks after it was placed) by roughening with a large-grain diamond bur at low speed[174] or preferably by microparticle air abrasion using fine sand (eg, 30-micron aluminum oxide or CoJet sand; Figs 6-78a to 6-78c).[96] Old existing Class 3 or 4 composite resin restorations should be treated by tribochemical silicoating conditioning and silane (see process in chapter 7, Fig 7-3).[65,255,256] The bonding procedure is then limited to the conditioning of the enamel, ie, phosphoric acid etching (Figs 6-78d to 6-78f) and rinsing (Fig 6-78g), followed by gentle alcohol drying (Figs 6-78h and 6-78i) and application of the adhesive resin (Figs 6-78j to 6-78l).

## Insertion of the ceramic workpiece

The restoration is inserted immediately following the placement of the adhesive resin onto the tooth (and subsequent air-thinning). From that moment on, the working field must be free from any intense light to prevent premature resin polymerization. The restoration is slowly seated with gentle finger pressure along the insertion axis (Fig 6-79a). Gross excess of composite resin is eliminated with the tip of an explorer or with instrument DD1 (Hu-Friedy) previously loaded with adhesive resin (Figs 6-79b and 6-79c). The instrument is guided in a cutting motion parallel to the margin to avoid extraction of composite resin from the margin.

**FIG 6-78 Step-by-step conditioning of the tooth surface.** This tooth presented biocorrosion and extensive dentin exposures revealed at the time of preparation; the entire dentin surface had been sealed immediately before taking the final impression. As a result, the adhesive layer (OptiBond FL), which covers an extensive part of the preparation *(a, dotted area)*, must be reactivated by surface roughening *(b and c*; eg, airborne-particle abrasion with CoJet sand). *(d to f)* The tooth surface can be etched with $H_3PO_4$ for 30 seconds to cleanse the adhesive surface and condition the enamel. *(g)* The etchant is eliminated by abundant rinsing; a dry surface can be obtained by gently spreading alcohol via a cotton pellet *(h*; no scrubbing) and air-drying the preparation *(i). (j to l)* The preparation is then coated with adhesive resin.

**FIG 6-79 Restoration insertion.** *(a)* The excess adhesive resin can be air-thinned but not polymerized. It is immediately followed by the insertion of the restoration. The restoration should be initially inserted while wedges and sectional matrices are in place to prevent large accumulation of composite resin in the interdental area. It is slowly seated by applying finger pressure. *(b and c)* Gross excess is removed using an explorer in a cutting motion, parallel to the margin.



t.me/Dr_Mouayyad_AlbtousH

## SURFACE ROUGHENING (MICROSANDBLASTING)

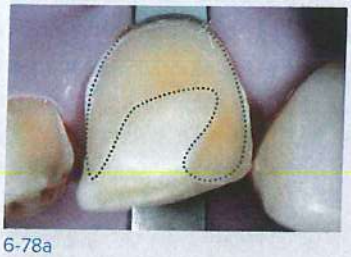
6-78a


6-78b


6-78c

## $H_3 PO_4$ ETCHING 30 SEC


6-78d


6-78e


6-78f

## RINSING AND ALCOHOL DRYING


6-78g

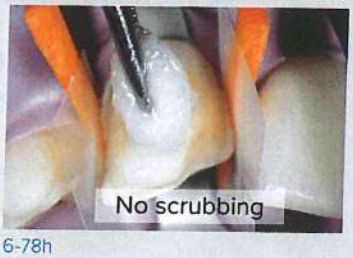

6-78h


6-78i

## APPLICATION OF ADHESIVE RESIN


6-78j


6-78k


6-78l

## INITIAL INSERTION AND GROSS EXCESS REMOVAL


6-79a


6-79b


6-79c



t.me/Dr_Mouayyad_AlbtousH

Finger pressure and excess elimination are alternately repeated. Interdental wedges and matrices are then removed (Figs 6-79d and 6-79e) to allow the complete and passive seating of the restoration, which is objectively confirmed when the finger pressure does not induce any further extrusion of composite resin at the margin (Fig 6-79f). A clean regular brush can be used to eliminate the last excesses of resin (Figs 6-79g to 6-79i). By the time the restoration is fully seated, the composite resin should have cooled down, facilitating excess removal and improving the restoration's stability during cleaning. Interdental flossing must be avoided at this stage because it could either crack, displace, or detach the porcelain workpiece from the tooth; eventual flashes of composite resin in the interdental contact area can be easily chipped with a scalpel after polymerization.

The light polymerization starts at the palatal aspect (Fig 6-79j). For intensities greater than 1,000 mW/cm$^2$, a total of 60 seconds of irradiation per surface will be required, and 90 seconds per surface for restorations thicker than 3 mm. Intermittent curing (20-second increments) must be applied to avoid heating of the soft tissues; in this respect, a protective barrier (eg, OpalDam, Ultradent) can be placed between the rubber dam and the gingiva. Polymerization of the buccal aspect follows for 60 seconds, intermittently, at each interproximal area. Additional polymerization of the margins must be performed after covering them with a layer of glycerin gel (Fig 6-79k; K-Y Jelly, Johnson & Johnson). Due to the oxygen inhibition during polymerization, margins polymerized without glycerin gel show a rapid degradation compared to air-blocked margins.[257] Glycerin is water-soluble and can be easily rinsed off (Fig 6-79l).

Any excess adhesive and composite resin is removed under rubber dam with hand instruments (surgical blade and scaler; Figs 6-79m and 6-79n). Rotary instruments are not recommended for this purpose because they could damage the ceramic margin.

When multiple restorations are to be placed, a serial approach according to the aforementioned sequence is advocated, repeating the process for each tooth (try-in, conditioning of the ceramic, conditioning of the tooth, then insertion). Parallel delivery of two restorations is possible when using the isolation technique described in Fig 6-74c.

**FIG 6-79** *(cont) (d)* Wooden wedges and matrices should be removed before the final seating; *(e)* the restoration must be maintained in position while the matrices are pulled buccally in a rotary motion against the tooth. *(f)* Final seating is obtained with finger pressure. *(g)* As a result, small amounts of composite resin may still extrude from the margins. *(h and i)* These minor excesses are easily removed with a clean regular brush; here again, a motion parallel to the margin is used. *(j)* Polymerization starts at the palatal surface for 20 seconds, followed by 20 seconds mesiofacially and 20 seconds distofacially *(dotted arrows)* and is repeated three times. *(k)* All margins are then covered with glycerin gel and polymerized 10 seconds per surface. *(l)* The glycerin can be easily rinsed off before proceeding to finishing. *(m and n)* With the rubber dam still in place to protect the soft tissues, excess composite and adhesive resin can be easily chipped off with a #12 surgical blade with a cutting motion parallel to the margin. *(o and p)* Final occlusal adjustments can be carried out with ultrafine diamonds/spiral brushes (Brasseler 379 023 and 274 016) and abundant air/water spray and silicon points/spiral brushes (Brasseler W16DG Blue, W16DM Pink, W16D Gray). *(q)* Note the fine palatal surface finish and invisible tooth-restoration interface. Interdental flossing with unwaxed floss is recommended to detect possible resin flashes, as well as a final control radiograph (as seen in Fig 6-72e).



t.me/Dr_Mouayyad_AlbtousH

## REMOVAL OF MATRICES AND FINAL INSERTION



6-79d

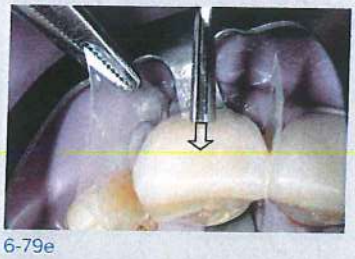

6-79e

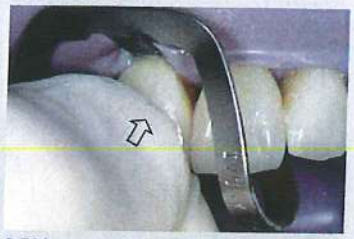

6-79f

## FINE EXCESS REMOVAL



6-79g

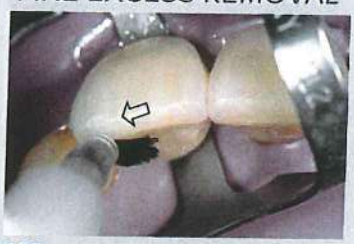

6-79h



6-79i

## LIGHT POLYMERIZATION, AIR-BLOCKING, AND RINSING

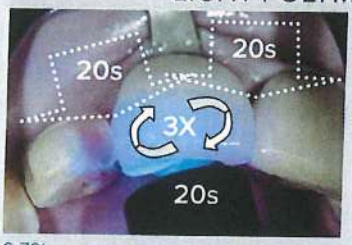


6-79j



6-79k



6-79l

## HAND INSTRUMENT FINISHING



6-79m

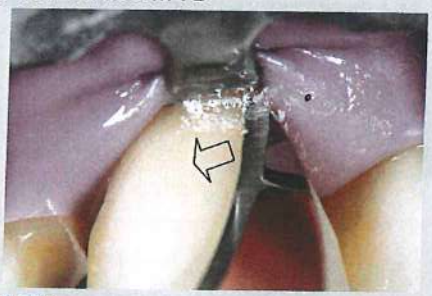

6-79n

## OCCLUSAL ADJUSTMENTS

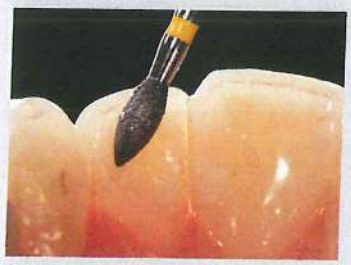

6-79o



6-79p



6-79q



t.me/Dr_Mouayyad_AlbtousH

Various factors can be responsible for the incomplete seating of a restoration: premature polymerization of the adhesive, presence of a polymerized fragment within the composite resin, polymerized resin flashes on the neighboring tooth contact, etc. When light-polymerizing composite resins are used, all these problems are reversible as far as the light has not been applied; the restoration is immediately removed, immerged in acetone, and meticulously cleaned. Resin residues are eliminated from the tooth surface by rubbing a cotton pellet soaked in alcohol. The enamel must be reconditioned by air abrasion and etching, whereas the ceramic only requires reapplication of the silane before proceeding again to cementation.[238]

## Final adjustments and occlusal control

This step should under no circumstances be carried out before the final bonding of the porcelain workpieces, due to a high risk of fracture. Once rubber dam has been removed, the occlusion is immediately adjusted, beginning with maximal intercuspation. Eventual corrections are carried out with fine-grain diamond burs and silicon points (Figs 6-79o to 6-79q). A variety of commercial kits (mainly diamond-impregnated silicon points/spiral brushes) can then be used to improve the intraoral surface finishing of the ceramic.[216,218,258,259] It is often speculated that the rougher surfaces produced by intraoral polishing (compared to intact glazed ceramic) will generate increased enamel wear; it appears that dental porcelains generate an abrasive type of wear, the amount of which is not related to the type of surface finish (eg, glazed vs intraorally polished).[191,260,261]

The functional features of teeth restored with BPRs are considered to be identical to those of intact natural teeth, keeping in mind that a key element in the development of harmonious occlusion is the incisal guidance,[48,49] the steepness of which is not relevant for neuromuscular harmony.[48] BPR-restored central incisors with increased prominence and incisal length therefore contribute to the definition of the ideal occlusion, which refers to both an esthetic and physiologic ideal.[48,50]

***In other words, particular emphasis must be addressed to the maintenance or reestablishment of an adequate and functional anterior guidance during mandibular excursions (Fig 6-80), regardless of whether this guidance involves the new laminate veneer restorations.[24] All the aforementioned should not feel new to the patient as it should just reproduce the occlusal conditions tested and approved by the patient during the diagnostic phase with the mock-up.***

There are no scientific bases indicating that this same goal (occlusal status) is not applicable in previously worn dentitions and in patients with occlusal parafunctions. Walls[19] demonstrated that BPRs placed in worn and fractured teeth in the early 1990s and followed over 5 years compared favorably with traditional porcelain veneers and inlays. This good success rate is empowered by the minimally invasive approach, which is always commendable in this type of patient. A sequential procedure for the luting of BPRs is presented in Table 6-3 and can be used as a checklist.

**FIG 6-80 Ultimate esthetic and physiologic ideal.** Typical indication for BPRs, ie, type IIIB—biocorrosion and wear (same patient as in Figs 6-77 to 6-79). *(a and b)* Preoperative and immediate postoperative views. *(c to e)* Six anterior maxillary BPRs were placed from canine to canine. The functional features of the restored teeth follow those of the intact natural teeth. *(f)* Baseline views before treatment (overlay) and after placement of six BPRs. The success of this rehabilitation lies in the diagnostic approach and subsequent esthetic and functional recovery of anterior teeth. (Patient treated in collaboration with Dr Nikolaos Perakis, Bologna Italy.)



t.me/Dr_Mouayyad_AlbtousH



6-80a



6-80b

## ANTERIOR GUIDANCE



6-80c



6-80d

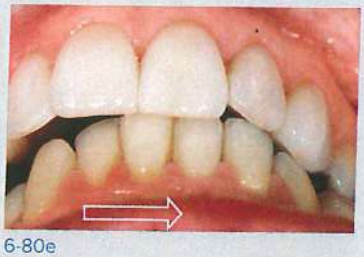

6-80e

## BASELINE



6-80f



6-80g



t.me/Dr_Mouayyad_AlbtousH

**TABLE 6-3** Detailed instructions for adhesive delivery after try-in

| Step | Instruments and methods | Notes |
|---|---|---|
| 1. Composite resin preheating | Turn on Calset (AdDent), select the red flashing light (68°C/155°F), and use **micro-hybrid composite resin** (eg, Herculite XRV Enamel shade or ENA HRi Dentin shade, Micerium) preheated for 5 to 15 minutes. | Select shade based on dentin porcelain used by ceramist. **Caution:** Some composite resin brands may start setting after more than 15 minutes in Calset. |
| 2. Isolation/final adjustments | Place rubber dam with clamp #212 on the treated tooth and test seating of the first restoration to deliver. In case of incomplete seating, place articulating paper proximally and insert the restoration. Hold the restoration and slightly pull the paper to mark the contact. Adjust the contact with a flexible disk or fine diamond bur at low speed. **Insertion must be 100% passive** (no friction or rebound). Repolish contacts with silicon/diamond points. | Strong contacts will result in slight rebounding of the restoration when releasing pressure. Further adjustment is necessary. |
| 3. **Restoration conditioning – Part I** | Wear gloves, masks, and glasses. Clean fitting surface with alcohol.<br>**If feldspathic porcelain veneer:** Etch the intaglio for 90 seconds with 9.6%–10% HF acid and rinse copiously.<br>**If lithium disilicate** (e.max): Etch only 20 seconds with 5% HF acid (IPS Ceramic Etching Gel, Ivoclar) and rinse copiously.<br>Optional (if large amounts of white debris): Preclean the fitting surface with 37% phosphoric acid (eg, Ultra-Etch) by rubbing with a microbrush for 30 seconds.<br>Rinse and dip in an **ultrasonic bath with distilled water or 90% ethanol** for 2 to 4 minutes. Thoroughly dry, apply **silane** (eg, Silane, Ultradent) for 20 to 40 seconds, air-dry, and heat-dry in the oven for 1 minute or with a hair dryer for 2 minutes at 100°C/212°F. | Porcelain surfaces contaminated with try-in products must be carefully cleansed with resin solvents (acetone, ethanol, methanol, or methylene chloride) before starting adhesive conditioning. Do not air-abrade thin veneers with aluminum oxide! Rinsed HF etchant should be neutralized before flushing. An alternate method to heat-drying is to let dry an additional 5 minutes in the Calset unit or in air. A **shiny surface after silane application reveals silane excess** → heat-dry, then remove excess in an ultrasonic bath (alcohol) or by rinsing with boiling water, and heat-dry again. |
| 4. **Tooth conditioning – Part I** | Use matrices/wedges to protect neighboring teeth.<br>**Airborne-particle abrade** (eg, Microetcher, Danville, with CoJet or 30-µm $Al_2O_3$) until the preparation surface is completely dull. **Apply phosphoric acid** to the entire surface and 1 mm beyond the margins for 30 seconds, rinse (20 seconds), and thoroughly dry. | **Dentin exposure should have been treated before impression with the IDS technique.** In case of missed dentin exposures, a dentin primer should be used.<br><br>CoJet and silane should be used on old existing composite resin restorations. |
| 5. **Restoration conditioning – Part II** | OptiBond FL Bottle 2 – (Black cap) Apply **adhesive resin** (eg, OptiBond FL Adhesive only, no Primer) at the intaglio surface of the veneer, air-thin, and store under a light shield (eg, Vivapad). | Adhesive resins are sensitive to light, so shielding is necessary until insertion to prevent premature polymerization. |
| 6. **Tooth conditioning – Part II** | Apply **adhesive resin** to the preparation surface (eg, OptiBond FL Adhesive only, no Primer unless dentin exposures are detected) and air-thin, but **DO NOT polymerize!** | This should always be the last step before insertion of the restoration. |



t.me/Dr_Mouayyad_AlbtousH

**TABLE 6-3** *(cont)* Detailed instructions for adhesive delivery after try-in

| Step | Instruments and methods | Notes |
|---|---|---|
| 7. Insertion | Insert preheated composite in the restoration, spread, and slowly insert onto the tooth. Use **finger pressure to seat onto the tooth.** Remove gross excesses with a DD1 instrument (Hu-Friedy). Remove the wedges/matrix (hold the restoration during this step). Push the restoration further down until complete insertion. | |
| 8. Excess removal and light polymerization | Push veneer further down. Use the DD1 in the embrasures to remove all excesses. **Do not floss** as this could induce fracture. **Polymerize from all sides** (total 60 to 90 seconds per surface, depending on veneer thickness) but **never for more than 20-second increments**, then move to the next surface. | Before polymerization, pushing the restoration and removing excesses is repeated until no further excesses are extruding from margins. |
| 9. Air-blocking | Place **glycerin gel** (eg, K-Y Jelly) over the margins and polymerize (10 seconds per surface). Rinse and dry. | |
| 10. Removal of excesses and resin flashes | **Hand instruments only!** Check the margins with a scaler, DD7-DD10 instruments (Hu-Friedy), and #12 scalpel blade. Remove clamp if necessary. | Avoid using burs on ceramic margins unless a major composite resin excess needs to be removed. |
| 11. Repeat for next restoration | Move clamp #212 onto the next tooth to be treated and repeat steps 3 to 10 for the next restoration. **The insertion sequence should always be rehearsed on a solid model before starting delivery of a group of restorations.** Overlapping teeth may dictate a specific insertion sequence to avoid loss of interdental contacts. | Incomplete seating of the next restoration is usually caused by excess resin flashes at the interdental contacts or contamination of the preparation surface during delivery of the previous restoration. |
| 12. Occlusal adjustments | Remove rubber dam and adjust high contacts in maximal intercuspation with fine diamond burs followed by silicon/diamond polishing points. Adjust dynamic guidance and repolish if necessary. | Air/water spray will prevent damaging the ceramic when adjusting/polishing. Advise the patient that interdental openings are created by rubber dam placement and will close after the gingiva recovers its position after a few hours. |





t.me/Dr_Mouayyad_AlbtousH

## Special considerations

### Interdental adjustments during luting procedures

***Because of its precise fit, each remaining ceramic workpiece must be tried again under rubber dam as delivery proceeds. A passive fit must be obtained.*** Slight movement of adjacent teeth and presence of the previously delivered neighboring restoration can alter the seating of the next restoration, especially in cases of extensive wrapping and long interdental contacts (Fig 6-81). Articulating paper and abrasive disks or fine diamond burs are used alternatively to mark the excess contact, adjust, and polish the interdental surface.



6-81a



6-81b

**FIG 6-81 Final try-in and proximal adjustments.** *(a)* The right central incisor and left lateral incisor are nonvital, and all four incisors have existing Class 3 and Class 4 composite resin restorations, which explains the marked interdental wrapping. *(b)* The porcelain restorations on both central incisors have a long interdental contact. *(c)* Following delivery of the left lateral and central incisors, the restoration on the right central incisor could not be completely seated *(arrowheads* show marginal opening). *(d to f)* Excessive pressure at the interdental contact is identified with articulating paper and slightly released using abrasive disks and water irrigation at low speed. *(g and h)* The procedure is repeated until complete and passive seating of the restoration is obtained *(arrowhead* shows marginal closure). *(i)* Clinical situation after etching of the tooth, just prior to final insertion. *(j)* Comparative preoperative (overlay) and postoperative views. There were multiple indications for restoring these teeth, including the old extended composite resin restoration and the altered crown biomechanics of the endodontically treated teeth; the procedure also allowed recovery of the incisal prominence, coronal volume, and length. Other views of this case can be found in Fig 6-39.



t.me/Dr_Mouayyad_AlbtousH

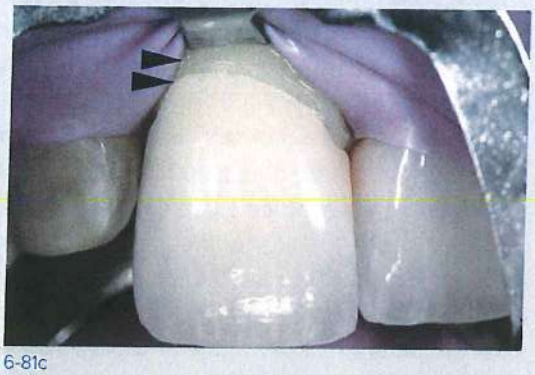

6-81c

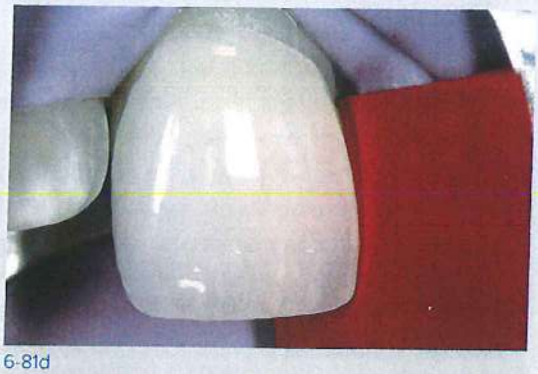

6-81d



6-81e



6-81f



6-81g

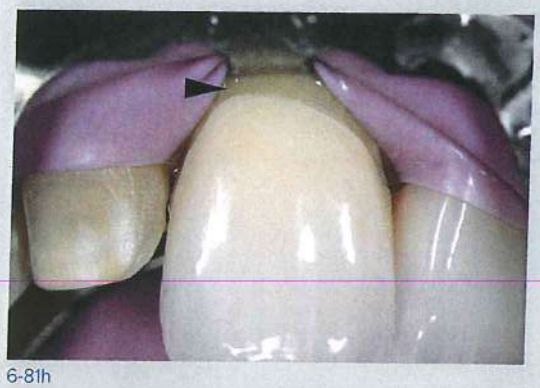

6-81h



6-81i





6-81j

t.me/Dr_Mouayyad_AlbtousH

### Masking a show-through defect

A relatively common problem is encountered when a thin area of the restoration is coincidentally facing a transparent area of the tooth, typically near the incisal edge. As a result, a gray spot or area may be visible even during try-in (Fig 6-82). ***If not compensated for by masking, such a defect will only get more apparent after delivery, once the veneer is perfectly fitted and optically continuous with the tooth (through the luting composite).*** Compensation by an opaque luting agent is contraindicated as it will limit light distribution through the restoration and surrounding soft tissue, possibly causing an umbrella effect (explained in Fig 6-19d). Instead, such a ***small and localized defect can be resolved by selective masking onto the tooth preparation.*** Enamel in the problematic area is slightly flattened to make space for the bonding of a thin layer of masking resin. The restoration is tried again with glycerin gel to confirm the desired effect before delivery with a regular composite resin.

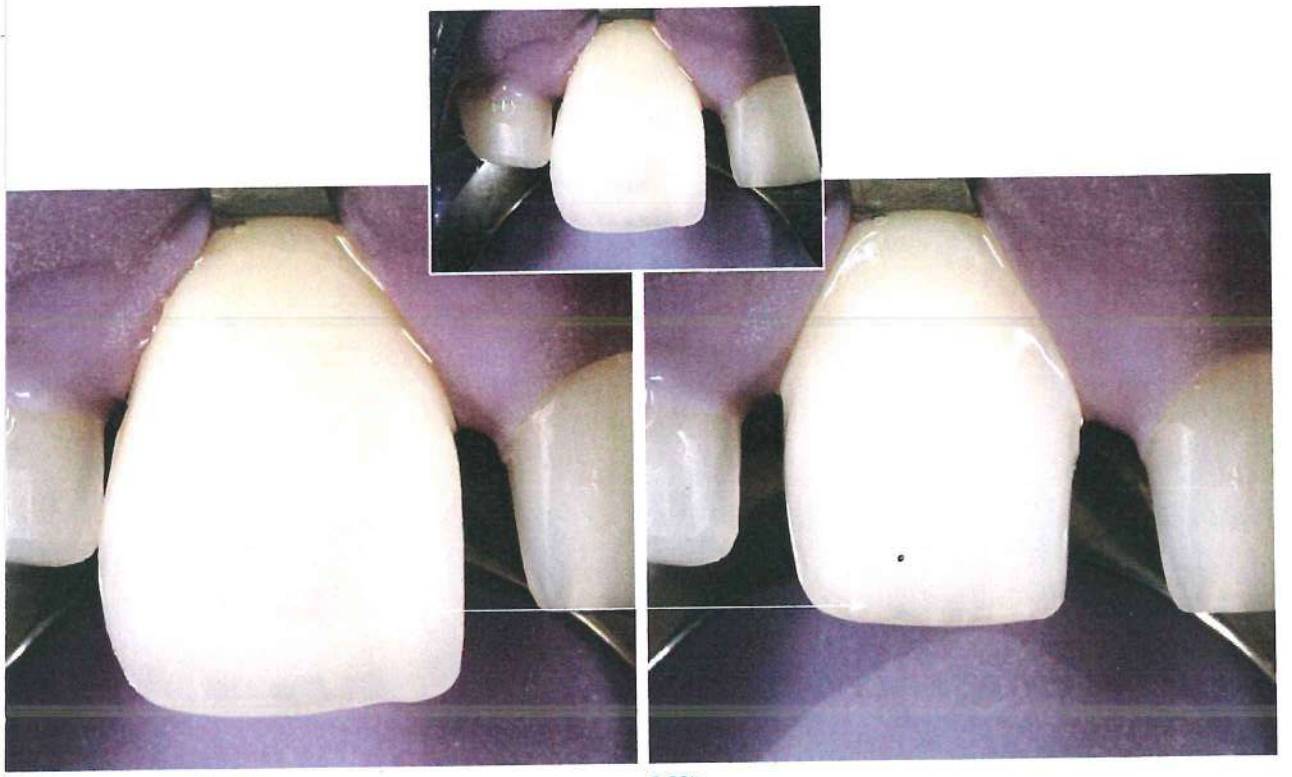

6-82a 6-82b

**FIG 6-82 Step-by-step masking of a localized show-through defect.** *(a and b)* A wet try-in of this right central incisor reveals a strong show-through defect at the incisal third *(dotted oval* and overlay image). It coincides with an area of transparency on the tooth *(arrow)*. This unfortunate effect is due to the superimposition of the transparent area and the reduced thickness of the ceramic at this same location. There is no need to redo the veneer or to use an opaque luting agent. Selective intrinsic masking of the preparation was obtained after slightly reducing the enamel *(c)*, etching the area *(d)*, rinsing and drying, and then applying a wash of adhesive resin mixed with A1 opaque resin (Kolor + Plus, Kerr; *e)*. The opaque liner is polymerized for 20 seconds and polymerized again through glycerin gel for another 10 seconds. *(i and j)* Another wet try-in is done to check the effect. *(k)* A restorative microhybrid composite resin (ENA HRi dentin shade, Micerium) was used for the delivery, and the show-through effect has been resolved. Tooth preparations of this case are presented in Figs 6-24 and 6-25.



t.me/Dr_Mouayyad_AlbtousH



6-82c



6-82d




6-82e



6-82f



6-82g



6-82h

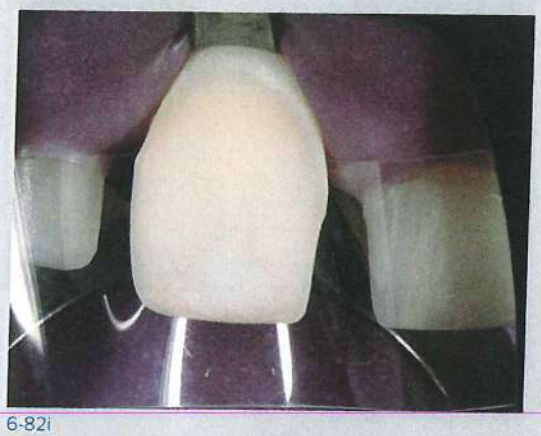

6-82i



6-82j



6-82k



t.me/Dr_Mouayyad_AlbtousH

## Additive luting

In some rare situations, large interdental spaces will call for oversized miniwings, the emergence profile of which may generate hygiene problems. Figure 6-83 features a patient with severe localized biocorrosion and a large diastema between the maxillary central incisors. The mock-up revealed that a small residual diastema would please the patient. Despite maximum interdental wrapping of the preparation, the resulting type IIIB veneers still display an excessive emergence generating a concavity (Fig 6-83d, *arrows*), which would be difficult for the patient to maintain. It was decided to compensate for this problem by additive luting: Both the veneer and the tooth preparation were conditioned and bonded beyond the interdental and lingual margins in order to use overflow of luting composite resin to fill the concavity and produce a smooth emergence (Fig 6-83g).



6-83a

6-83b

**FIG 6-83 Extreme interdental emergence profile compensated by additive luting.** *(a)* This patient presented with localized diet-induced biocorrosion, extensive enamel loss, dentin exposures, and gaps between his maxillary incisors. Following a wax-up and confirmation with a mock-up, ultraconservative preparations in combination with a frontal insertion path and IDS were carried out (overlay image, preparations with retraction cord for final impression). *(b)* The working model reveals the significant modification of the soft tissue model by the ceramist in order to obtain an extended interproximal volume and partial closure of the diastema. *(c and d)* The corresponding type IIIB veneers were tried in, and the mesial aspect of the restorations is obviously emerging at 90 degrees to the tooth surface *(arrows)*. *(e)* The veneer and the tooth were etched and bonded additively (try-in under rubber dam; the *dotted line* represents the outer etched area overlapping the tooth and the restoration that will be covered with composite resin). *(f)* HF etching of the veneer is carried out at the fitting surface and extends to the outer overlapping surface. The outer overlapping surface must be devoid of glazing porcelain in order to be etched correctly. A fine diamond may be used to remove the glaze before etching. *(g)* Comparative view after seating the veneer with composite resin. The overflow of material at the proximal and palatal margin is used to cover the outer surfaces that were etched and obtain a flat surface devoid of concavities (rubber dam is used as a barrier to shape the composite resin). *(h and i)* Final buccal and lingual views as well as postoperative radiographs (overlay) showing the continuous margins and smooth surfaces facilitating hygiene. (Both overlay images reproduced with permission from Magne.[135])



t.me/Dr_Mouayyad_AlbtousH

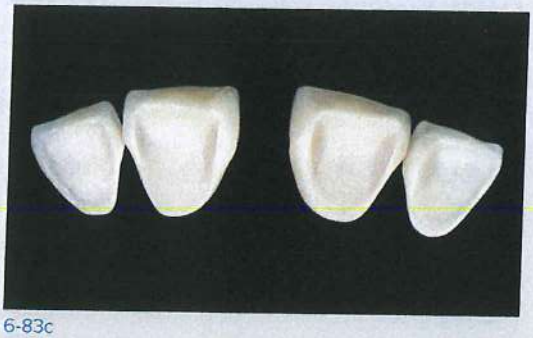

6-83c

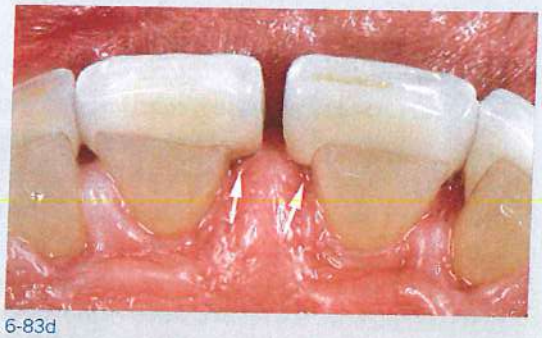

6-83d

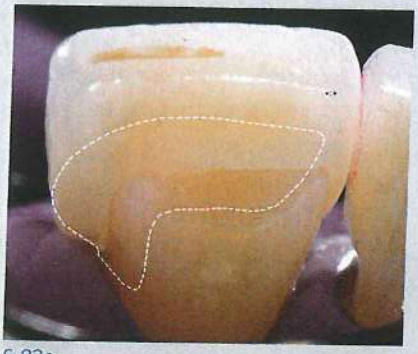

6-83e



6-83f

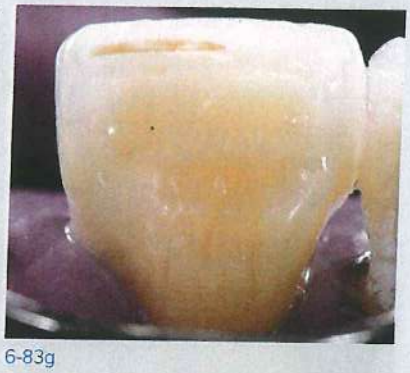

6-83g

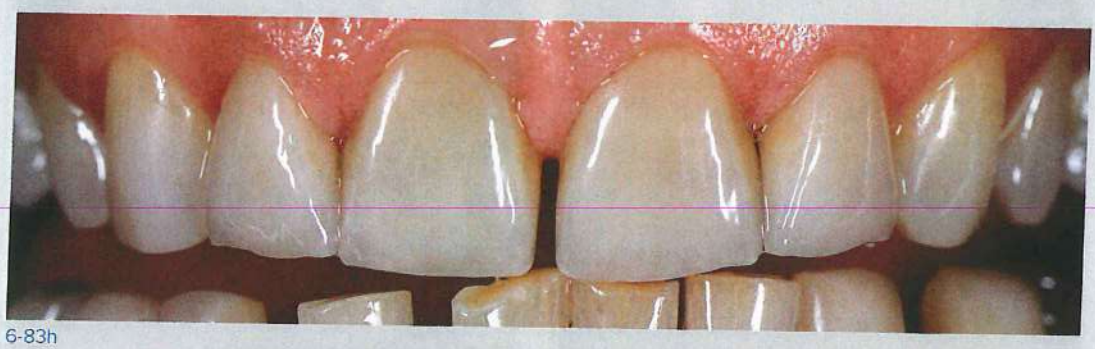

6-83h



1Y




6-83i



t.me/Dr_Mouayyad_AlbtousH

## Prebonding cracks

***Until it is bonded to the tooth, a porcelain workpiece remains extremely delicate.*** Microscopic flaws can form before cementation, either during laboratory processing or at the try-in stage. Even though bonding an already-cracked porcelain workpiece is generally not recommended, clinicians should be aware that a prebonding flaw that initiated from the inner surface of the restoration (Fig 6-84) is likely to become invisible after cementation and in the long term (> 20 years). This fact is also illustrated in Fig 6-85; the vertical crack was clearly visible on the master model (Fig 6-85a) and totally disappeared after bonding to the tooth (Fig 6-85b). The crack remained invisible after more than 21 years of clinical service (Fig 6-85c). The phenomenon might be attributed to the efficient sealing/infiltration of the flaw by the adhesive resin, the walls of the defect being enlarged and adequately conditioned during HF acid etching. Silanization also helps in wetting the microscopic space. Careful examination of each BPR to be bonded is therefore recommended. Use of an optic fiber and transillumination is imperative.

***Postbonding flaws initiating from the outer restoration surface (easily detectable with tangential light) can also be sealed after delivery following a specific technique*** *(see resin infiltration technique in chapter 7, Figs 7-11 and 7-12).*[262]



6-84a



6-84b




6-84c




6-84d

**FIG 6-84 Single type IIIA BPR with prebonding internal flaw.** This left incisor workpiece cracked during transport from the laboratory to the operatory. *(a)* The horizontal flaw is visible from the facial surface *(arrowhead). (b)* Closer examination revealed that the crack initiated at the inner surface. *(c and d)* The single restoration was delivered regardless of the crack; it is in perfect condition 20 years later and still matches perfectly the intact right central incisor (smartphone photographs).



t.me/Dr_Mouayyad_AlbtousH



6-85a



6-85b



6-85c

21Y

**FIG 6-85 Disappearance of prebonding flaw because of adhesive luting.** An internal prebonding crack was clearly detectable before delivery of this right central incisor *(a)* but is no longer visible after definitive insertion of the BPR *(b)*. *(c)* The defect is still invisible after more than 21 years of clinical service (smartphone photograph). This case is also presented in chapter 7, Fig 7-8 for the repair of the right lateral incisor, which had fractures 16 years before and is still in perfect condition.



t.me/Dr_Mouayyad_AlbtousH

# REFERENCES


1. Pincus CR. Building mouth personality. J South Calif Dent Assoc 1938;14:125–129.
2. Horn HR. Porcelain laminate veneers bonded to etched enamel. Dent Clin North Am 1983:27:671–684.
3. Calamia JR. Etched porcelain facial veneers: A new treatment modality based on scientific and clinical evidence. N Y J Dent 1983:53:255–259.
4. Rochette AL. A ceramic restoration bonded by etched enamel and resin for fractured incisors. J Prosthet Dent 1975;33:287–293.
5. Touati B, Pissis P, Miara P. Bonded single restorations and the concept of pellicular preparations. Cah Prothese 1985;13:95–130.
6. Touati B, Bersay L. Enameling of teeth using glass ceramic veneers. Cah Prothese 1987;15:167–189.
7. Touati B, Plissart-Vanackere A. Ceramic bonded veneers. Toward a minimal prosthesis. Real Clin 1990;1:51–66.
8. Calamia JR. Etched porcelain veneers: The current state of the art. Quintessence Int 1985;16:5–12.
9. Calamia JR. Clinical evaluation of etched porcelain veneers. Am J Dent 1989;2:9–15.
10. Calamia JR. The current status of etched porcelain veneer restorations. J Indiana Dent Assoc 1993;72:10–15.
11. Christensen GJ. Veneering of teeth. State of the art. Dent Clin North Am 1985;29:373–391.
12. Garber AD, Goldstein RE, Feinman RA. Porcelain Laminate Veneers. Chicago: Quintessence, 1988.
13. Friedman MJ. Augmenting restorative dentistry with porcelain veneers. J Am Dent Assoc 1991;122:29–34.
14. Andreasen FM, Daugaard-Jensen J, Munksgaard EC. Reinforcement of bonded crown fractured incisors with porcelain veneers. Endod Dent Traumatol 1991;7:78–83.
15. Andreasen FM, Flugge E, Daugaard-Jensen J, Munksgaard EC. Treatment of crown fractured incisors with laminate veneer restorations. An experimental study. Endod Dent Traumatol 1992;8:30–35.
16. Magne P, Magne M, Belser U. Natural and restorative oral esthetics. Part II: Esthetic treatment modalities. J Esthet Dent 1993;5:239–246.
17. Magne P, Holz J. Restauration des dents antérieures. Principe, indications et limites des techniques de traitement. Rev Mens Suisse Odontostomatol 1994;104:1247–1254.
18. Walls AW. The use of adhesively retained all-porcelain veneers during the management of fractured and worn anterior teeth: Part 1. Clinical technique. Br Dent J 1995;178:333–336.
19. Walls AW. The use of adhesively retained all-porcelain veneers during the management of fractured and worn anterior teeth: Part 2. Clinical results after 5 years of follow-up. Br Dent J 1995;178:337–340.
20. Belser UC, Magne P, Magne M. Ceramic laminate veneers: Continuous evolution of indications. J Esthet Dent 1997;9:197–207.
21. Magne P, Douglas WH. Additive contour of porcelain veneers: A key element in enamel preservation, adhesion and esthetic for the aging dentition. J Adhes Dent 1999;1:81–91.
22. Magne P, Douglas WH. Optimisation des concepts mécanique en médecine dentaire esthétique. Inf Den 1999;81:373–381.
23. Magne P, Douglas WH. Design optimization and evolution of bonded ceramics for the anterior dentition: A finite element analysis. Quintessence Int 1999;30:661–672.
24. Magne P, Perroud R, Hodges JS, Belser UC. Clinical performance of novel-design porcelain veneers for the recovery of coronal volume and length. Int J Periodontics Restorative Dent 2000;20:440–457.
25. Magne P, Magne M. Treatment of extended anterior crown fractures using Type IIIA bonded porcelain restorations. J Calif Dent Assoc 2005;33:387–396.
26. Jordan RE, Boksman L. Conservative vital bleaching treatment of discolored dentition. Comp Cont Ed 1984;5:803–808.
27. Haywood VB, Leonard RH, Dickinson GL. Efficacy of six months of nightguard vital bleaching of tetracycline-stained teeth. J Esthet Dent 1997;9:13–19.
28. Haywood VB, Parker MH. Nighguard vital bleaching beneath existing porcelain veneers: A case report. Quintessence Int 1999;30:743–747.
29. Magne P, Douglas WH. Porcelain veneers: Dentin bonding optimization and biomimetic recovery of the crown. Int J Prosthodont 1999;12:111–121.
30. Magne P, Douglas WH. Rationalization of esthetic restorative dentistry based on biomimetics. J Esthet Dent 1999;11:5–15.
31. Magne P, Douglas WH. Cumulative effects of successive restorative procedures on anterior crown flexure: Intact versus veneered incisors. Quintessence Int 2000;31:5–18.
32. Gresnigt MMM, Cune MS, Schuitemaker J, et al. Performance of ceramic laminate veneers with immediate dentine sealing: An 11 year prospective clinical trial. Dent Mater 2019;35:1042–1052.
33. Sedgley CM, Messer HH. Are endodontically treated teeth more brittle? J Endod 1992;18:332–335.
34. Papa J, Cain C, Messer HH. Moisture content of vital vs. endodontically treated teeth. Endod Dent Traumatol 1994;10:91–93.
35. Burke S, Burch JG, Tetz JA Incidence and size of pretreatment overlap and posttreatment gingival embrasure space between maxillary central incisors. Am J Orthod Dentofacial Orthop 1994;105:506–511.
36. Allen EP, Kois J, Tarnow D, Takei H. Progress in interdental papilla construction. Presented at the 21st Annual Meeting of the American Academy of Esthetic Dentistry, Aspen, 8 August 1996.
37. Magne P, Magne M, Belser U. The esthetic width in fixed prosthodontics. J Prosthodont 1999;8:106–118.
38. Kopp FR. Esthetic principles for full crown restorations. Part II: Provisionalization. J Esthet Dent 1993;5:258–264.
39. Lombardi RE. The principles of visual perception and their clinical application to denture esthetics. J Prosthet Dent 1973;29:358–382.
40. Walls AW, Murray JJ, McCabe JF. Composite laminate veneers: A clinical study. J Oral Rehabil 1988;15:439–454.
41. Tyas MJ. Correlation between fracture properties and clinical performance of composite resins in Class IV cavities. Aust Dent J 1990;35:46–49.
42. Peumans M, Van Meerbeek B, Lambrechts P, Vanherle G. The 5-year clinical performance of direct composite additions to correct tooth form and position. I. Esthetic qualities. Clin Oral Investig 1997;1:12–18.
43. Wall JG, Reisbick MH, Johnston WM. Incisal-edge strength of porcelain laminate veneers restoring mandibular incisors. Int J Prosthodont 1992;5:441–446.




t.me/Dr_Mouayyad_AlbtousH

44. Gresnigt MMM, Cune MS, Jansen K, van der Made SAM, Özcan M. Randomized clinical trial on indirect resin composite and ceramic laminate veneers: Up to 10-year findings. J Dent 2019;86:102–109.
45. Meijering AC, Roeters FJ, Mulder J, Creugers NH. Patients' satisfaction with different types of veneer restorations. J Dent 1997;25:493–497.
46. Magne P, Versluis A, Douglas WH. Rationalization of incisor shape: Experimental-numerical analysis. J Prosthet Dent 1999;81:345–355.
47. Okeson JP. Temporomandibular disorders: Anatomic factors and TMD. In: Orofacial Pain. Chicago: Quintessence, 1996:122–123.
48. Ramfjord S, Ash MM. Anatomy and physiology of the masticatory system. Ideal occlusion. In: Occlusion, ed 3. Philadelphia: W.B. Saunders, 1983:166–168.
49. Dawson PE. Anterior guidance. In: Evaluation, Diagnosis, and Treatment of Occlusal Problems, ed 2. St Louis: Mosby, 1989:274–297.
50. Beyron H. Optimal occlusion. Dent'Clin North Am 1969;13:537–554.
51. Magne P, Magne M, Belser U. The diagnostic template: A key element to the comprehensive esthetic treatment concept. Int J Periodontics Restorative Dent 1996;16:560–569.
52. Magne P, Belser UC. Novel porcelain laminate preparation approach driven by a diagnostic mock-up. J Esthet Restor Dent 2004;16:7–16.
53. Magne P, Magne M. Use of additive waxup and direct intraoral mock-up for enamel preservation with porcelain laminate veneers. Eur J Esthet Dent 2006;1:10–19.
54. Reshad M, Cascione D, Magne P. Diagnostic mock-ups as an objective tool for predictable outcomes with porcelain laminate veneers in esthetically demanding patients: A clinical report. J Prosthet Dent 2008;99:333–339.
55. Simon H, Magne P. Clinically based diagnostic wax-up for optimal esthetics: The diagnostic mock-up. J Calif Dent Assoc 2008;36:355–362.
56. Magne P, Hanna J, Magne M. The case for moderate "guided prep" indirect porcelain veneers in the anterior dentition. The pendulum of porcelain veneer preparations: From almost no-prep to over-prep to no-prep. Eur J Esthet Dent 2013;8:376–388.
57. Castelnuovo J, Tjan AH, Phillips K, Nicholls JI, Kois JC. Fracture load and mode of failure of ceramic veneers with different preparations. J Prosthet Dent 2000;83:171–180.
58. Magne P, Magne M. Porcelain veneers at the turn of the millenium: A window to biomimetics [in French]. Real Clin 1998;9:329–343.
59. Magne P, Douglas WH. Optimization of resilience and stress distribution in porcelain veneers for the treatment of crown-fractured incisors. Int J Periodontics Restorative Dent 1999;19:543–553.
60. Gordon JE. Strain energy and modern fracture mechanics. In: Structures: Or Why Things Don't Fall Down. New York: Da Capo, 1978:70–109.
61. Barghi N, Berry TG. Post-bonding crack formation in porcelain veneers. J Esthet Dent 1997;9:51–54 .
62. Magne P, Kwon KR, Belser U, Douglas WH. Crack propensity of porcelain laminate veneers: A simulated operatory evaluation. J Prosthet Dent 1999;81:327–334.
63. Magne P, Versluis A, Douglas WH. Effect of luting composite shrinkage and thermal loads on the stress distribution in porcelain laminate veneers. J Prosthet Dent 1999;81:335–344.
64. Magne P, Douglas WH. Interdental design of porcelain veneers in the presence of composites fillings: Finite element analysis of composite shrinkage and thermal stresses. Int J Prosthodont 2000;13:117–124.
65. Gresnigt MM, Ozcan M, Kalk W, Galhano G. Effect of static and cyclic loading on ceramic laminate veneers adhered to teeth with and without aged composite restorations. J Adhes Dent 2011;13:569–577.
66. Munksgaard EC, Hojtved L, Jorgensen EH, Andreasen JO, Andreasen FM. Enamel-dentin crown fractures bonded with various bonding agents. Endod Dent Traumatol 1991;7:73–77.
67. Baratieri LN. Tooth fragment reattachment. In: Direct Adhesive Restorations on Fractured Anterior Teeth. Sao Paulo: Quintessence, 1998:135–205.
68. Magne P, Magne M, Jovanovic SA. An esthetic solution for single-implant restorations—Type III porcelain veneer bonded to a screw-retained custom abutment: A clinical report. J Prosthet Dent 2008;99:2–7.
69. Magne P, Paranhos MP, Burnett LH Jr, Magne M, Belser UC. Fatigue resistance and failure mode of novel-design anterior single-tooth implant restorations: Influence of material selection for type III veneers bonded to zirconia abutments. Clin Oral Implants Res 2011;22:195–200.
70. Magne P, Oderich E, Boff LL, Cardoso AC, Belser UC. Fatigue resistance and failure mode of CAD/CAM composite resin implant abutments restored with type III composite resin and porcelain veneers. Clin Oral Implants Res 2011;22:1275–1281.
71. Oderich E, Boff LL, Cardoso AC, Magne P. Fatigue resistance and failure mode of adhesively restored custom implant zirconia abutments. Clin Oral Implants Res 2012;23:1360–1368.
72. Boff LL, Oderich E, Cardoso AC, Magne P. Fatigue resistance and failure mode of adhesively restored custom metal-composite resin premolar implant abutments. Int J Oral Maxillofac Implants 2014;29:364–373.
73. Molina I, Goldberg J, Volpato CM, Magne P. Accelerated fatigue resistance of novel-design histoanatomic implant restorations made of CAD/CAM bilaminar assemblies. Int J Esthet Dent 2017;12:336–351.
74. Magne P, Silva M, Oderich E, Boff LL, Enciso R. Damping behavior of implant-supported restorations. Clin Oral Implants Res 2013;24:143–148.
75. Deery C, Wagner ML, Longbottom C, Simon R, Nugent ZJ. The prevalence of dental erosion in a United States and a United Kingdom sample of adolescents. Pediatr Dent 2000;22:505–510.
76. Mulic A, Fredriksen Ø, Jacobsen ID, Tveit AB, Espelid I, Crossner CG. Dental erosion: Prevalence and severity among 16-year-old adolescents in Troms, Norway. Eur J Paediatr Dent 2016;17:197–201.
77. Salas MMS, Vargas-Ferreira F, Ardenghi TM, Peres KG, Huysmans MD, Demarco FF. Prevalence and associated factors of tooth erosion in 8–12-year-old Brazilian schoolchildren. J Clin Pediatr Dent 2017;41:343–350.
78. Lussi A, Buzalaf MAR, Duangthip D, et al. The use of fluoride for the prevention of dental erosion and erosive tooth wear in children and adolescents. Eur Arch Paediatr Dent 2019;20:517–527.
79. Lussi A, Jaeggi T, Schaffner M. Prevention and minimally invasive treatment of erosions. Oral Health Prev Dent 2004;2(suppl 1):321–325.
80. Koodaryan R, Hafezeqoran A, Poursoltan S. Effect of dentin surface roughness on the shear bond strength of resin bonded restorations. J Adv Prosthodont 2016; 8:224–228.




t.me/Dr_Mouayyad_AlbtousH

81. Sattabanasuk V, Vachiramon V, Qian F, Armstrong SR. Resin-dentin bond strength as related to different surface preparation methods. J Dent 2007;35:467–475.
82. Zimmerli B, De Munck J, Lussi A, Lambrechts P, Van Meerbeek B. Long-term bonding to eroded dentin requires superficial bur preparation. Clin Oral Investig 2012;16:1451–1461.
83. Ganss C, Lussi A, Peutzfeldt A, Naguib Attia N, Schlueter N. Impact of Sn/F pre-treatments on the durability of protective coatings against dentine erosion/abrasion. PLoS One 2015;10(6):e0123889.
84. Gresnigt MM, Cune MS, de Roos JG, Özcan M. Effect of immediate and delayed dentin sealing on the fracture strength, failure type and Weibull characteristics of lithium-disilicate laminate veneers. Dent Mater 2016;32:e73–e81.
85. Magne P. Megabrasion: A conservative strategy for the anterior dentition. Pract Periodontics Aesthet Dent 1997;9:389–395.
86. Dietschi D, Krejci I. Traitements chimiques des dyschromies dentaires. Réalités Cliniques 1999;10:7–24.
87. Gerdolle D, Mortier E, Richard A, Vailati F. Full-mouth adhesive rehabilitation in a case of amelogenesis imperfecta: A 5-year follow-up case report. Int J Esthet Dent 2015;10:12–31.
88. Faria-e-Silva AL, De Moraes RR, Menezes Mde S, Capanema RR, De Moura AS, Martelli H Jr. Hardness and microshear bond strength to enamel and dentin of permanent teeth with hypocalcified amelogenesis imperfect. Int J Paediatr Dent 2011;21:314–320.
89. Bouvier D, Duprez JP, Pirel C, Vincent B. Amelogenesis imperfecta—A prosthetic rehabilitation: A clinical report. J Prosthet Dent 1999;82:130–131.
90. Klink A, Groten M, Huettig F. Complete rehabilitation of compromised full dentitions with adhesively bonded all-ceramic single-tooth restorations: Long-term outcome in patients with and without amelogenesis imperfecta. J Dent 2018;70:51–58.
91. Doner FH. The molded porcelain jacket crown. Dental Cosmos 1936;78:16–19.
92. Burke FJ, Watts DC. Fracture resistance of teeth restored with dentin-bonded crowns. Quintessence Int 1994;25:335–340.
93. Burke FJ. The effect of variations in bonding procedure on fracture resistance of dentin-bonded all-ceramic crowns. Quintessence Int 1995;26:293–300.
94. Burke FJ, Qualtrough AJ, Wilson NH. A retrospective evaluation of a series of dentin-bonded ceramic crowns. Quintessence Int 1998;29:103–106.
95. Bertschinger C, Paul SJ, Lüthy H, Schärer P. Dual application of dentin bonding agents: Effect on bond strength. Am J Dent 1996;9:115–119.
96. Magne P, So WS, Cascione D. Immediate dentin sealing supports delayed restoration placement. J Prosthet Dent 2007;98:166–174.
97. Jones GE, Boksman L, McConell RL. Effect of etching technique on the clinical performance of porcelain veneers. Quintessence Dent Technol 1989;10:635–637.
98. Peumans M, Van Meerbeek B, Yoshida Y, Lambrechts P, Vanherle G. Porcelain veneers bonded to tooth structure: An ultra-morphological FE-SEM examination of the adhesive interface. Dent Mater 1999;15:105–119.
99. Canay S, Hersek N, Ertan A. Effect of different acid treatments on a porcelain surface. J Oral Rehabil 2001;28:95–101.
100. Magne P, Cascione D. Influence of post-etching cleaning and connecting porcelain on the microtensile bond strength of composite resin to feldspathic porcelain. J Prosthet Dent 2006;96:354–361.
101. Daronch M, Rueggeberg FA, Moss L, de Goes MF. Clinically relevant issues related to preheating composites. J Esthet Restor Dent 2006;18:340–350.
102. Magne P, Magne M, Magne I. Porcelain jacket crowns: Back to the future through bonding. Quint Dent Technol 2010;34:89–96.
103. Magne M, Panaghiotis P, Magne P. The alveolar model. Quintessence Dent Technol 2008;32:39–46.
104. Stankiewicz NR, Wilson PR. The ferrule effect: A literature review. Int Endod J 2002;35;575–581.
105. Juloski J, Radovic I, Goracci C, Vulicevic ZR, Ferrari M. Ferrule effect: A literature review. J Endod 2012;38:11–19.
106. Magne P, Lazari PC, Carvalho MA, Johnson T, Del Bel Cury AA. Ferrule-effect dominates over use of a fiber post when restoring endodontically treated incisors: An in vitro study. Oper Dent 2017;42:396–406.
107. Figueiredo FED, Martins-Filho PRS, Faria-E-Silva AL. Do metal post-retained restorations result in more root fractures than fiber post-retained restorations? A systematic review and meta-analysis. J Endod 2015;41:309–316.
108. Naumann M, Neuhaus KW, Kölpin M, Seemann R. Why, when, and how general practitioners restore endodontically treated teeth: A representative survey in Germany. Clin Oral Investig 2016;20:253–259.
109. Zhou L, Wang Q. Comparison of fracture resistance between cast posts and fiber posts: A meta-analysis of literature. J Endod 2013;39:11–15.
110. Heydecke G, Peters MC. The restoration of endodontically treated, single-rooted teeth with cast or direct posts and cores: A systematic review. J Prosthet Dent 2002;87:380–386.
111. Schwartz RS, Robbins JW. Post placement and restoration of endodontically treated teeth: A literature review. J Endod 2004;30:289–301.
112. Toksavul S, Toman M, Uyulgan B, Schmage P, Nergiz I. Effect of luting agents and reconstruction techniques on the fracture of pre-fabricated post systems. J Oral Rehabil 2005;32:443–440.
113. Rasimick BJ, Wan J, Musikant BL, Deutsch ASA. Review of failure modes in teeth restored with adhesively luted endodontic dowels. J Prosthodont 2010;19:639–646.
114. Goracci C, Ferrari M. Current perspectives on post systems: A literature review. Aust Dent J 2011;56(suppl 1): 77–83.
115. Lazari PC, de Carvalho MA, Del Bel Cury AA, Magne P. Survival of extensively damaged endodontically treated incisors restored with different types of posts-and-core foundation restoration material. J Prosthet Dent 2018;119:769–776.
116. Carvalho MA, Lazari PC, Del Bel Cury AA, Magne P. Fatigue and failure analysis of restored endodontically treated maxillary incisors without a dowel or ferrule. J Prosthet Dent (in press).
117. Carvalho MA, Lazari PC, Gresnigt M, Del Bel Cury AA, Magne P. Current options concerning the endodontically-treated teeth restoration with the adhesive approach. Braz Oral Res 2018;32(suppl 1):e74.
118. Biacchi GR, Basting RT. Comparison of fracture strength of endocrowns and glass fiber post-retained conventional crowns. Oper Dent 2012;37:130–136.
119. Magne P, Goldberg J, Edelhoff D, Güth JF. Composite resin core buildups with and without post for the restoration of endodontically treated molars without ferrule. Oper Dent 2015;41:64–75.
120. Belleflamme MM, Geerts SO, Louwette MM, Grenade CF, Vanheusden AJ, Mainjot AK. No post-no core approach to restore severely damaged posterior teeth: An up to 10-year retrospective study of documented endocrown cases. J Dent 2017;63:1–7.



t.me/Dr_Mouayyad_AlbtousH

121. Carvalho MA, Lazari-Carvalho PC, Del Bel-Cury AA, Magne P. Accelerated fatigue resistance of endodontically treated incisors without ferrule restored with CAD/CAM endocrown. Int J Esthet Dent (in press).
122. Kemaloglu H, Emin Kaval M, Turkun M, Micoogullari Kurt S. Effect of novel restoration techniques on the fracture resistance of teeth treated endodontically: An in vitro study. Dent Mater J 2015;34:618–622.
123. Kim RJ, Kim YJ, Choi NS, Lee IB. Polymerization shrinkage, modulus, and shrinkage stress related to tooth-restoration interfacial debonding in bulk-fill composites. J Dent 2015;43:430–439.
124. Atalay C, Yazici AR, Horuztepe A, Nagas E, Ertan A, Ozgunaltay G. Fracture resistance of endodontically treated teeth restored with bulk fill, bulk fill flowable, fiber-reinforced, and conventional resin composite. Oper Dent 2016;41:131–140.
125. Kourkouta S, Walsh TT, Davis LG. The effect of porcelain laminate veneers on gingival health and bacterial plaque characteristics. J Clin Periodontol 1994;21:638–640.
126. Chan C, Weber H. Plaque retention on teeth restored with full-ceramic crowns: A comparative study. J Prosthet Dent 1986;56:666–671.
127. Savitt ED, Malament KA, Socransky SS, Melcer AJ, Backman KJ. Effects on colonization of oral microbiota by a cast glass-ceramic restoration. Int J Periodontics Restorative Dent 1987;7:22–35.
128. Koidis PT, Schroeder K, Johnston W, Campagni W. Color consistency, plaque accumulation, and external marginal surface characteristics of the collarless metal-ceramic restoration. J Prosthet Dent 1991;65:391–400.
129. Edelhoff D, Sorensen JA. Tooth structure removal associated with various preparation designs for posterior teeth. Int J Periodontics Restorative Dent 2002;22:241–249.
130. Edelhoff D, Sorensen JA. Tooth structure removal associated with various preparation designs for anterior teeth. Int J Periodontics Restorative Dent 2002;87:503–509.
131. Roulet JF. Longevity of glass ceramic inlays and amalgam—Results up to 6 years. Clin Oral Investig 1997;1:40–46.
132. Dietschi D, Spreafico R. Adhesive Metal-Free Restorations: Current Concepts for the Esthetic Treatment. Berlin: Quintessence, 1997.
133. Federlin M, Sipos C, Hiller KA, et al. Partial ceramic crowns: Influence of ceramic thickness, preparation design and luting material on fracture resistance and marginal integrity in vitro. Oper Dent 2007;32:251–260.
134. Stappert CF, Chitmongkolsuk S, Silva NR, Att W, Strub JR. Effect of mouth-motion fatigue and thermal cycling on the marginal accuracy of partial coverage restorations made of various dental materials. Dent Mater 2008;24:1248–1257.
135. Magne P. Immediate dentin sealing: A fundamental procedure for indirect bonded restorations. J Esthet Restor Dent 2005;17:144–154.
136. Magne P. Composite resins and bonded porcelain: The postamalgam era? J Calif Dent Assoc 2006;34:135–147.
137. Magne P, Schlichting LH, Maia HP, Baratieri LN. In vitro fatigue resistance of CAD/CAM composite resin and ceramic posterior occlusal veneers. J Prosthet Dent 2010;104:149–157.
138. Schlichting LH, Maia HP, Baratieri LN, Magne P. Novel-design ultra-thin CAD/CAM composite resin and ceramic occlusal veneers for the treatment of severe dental erosion. J Prosthet Dent 2011;105:217–226.
139. Magne P, Stanley K, Schlichting LH. Modeling of ultrathin occlusal veneers. Dent Mater 2012;28:777–782.
140. Schlichting LH, Resende TH, Reis KR, Magne P. Simplified treatment of severe dental erosion with ultrathin CAD-CAM composite occlusal veneers and anterior bilaminar veneers. J Prosthet Dent 2016;116:474–482.
141. Resende TH, Reis KR, Schlichting LH, Magne P. Ultrathin CAD-CAM ceramic occlusal veneers and anterior bilaminar veneers for the treatment of moderate dental biocorrosion: A 1.5-year follow-up. Oper Dent 2018;43:337–346.
142. Ioannidis A, Mühlemann S, Özcan M, Hüsler J, Hämmerle CHF, Benic GI. Ultra-thin occlusal veneers bonded to enamel and made of ceramic or hybrid materials exhibit load-bearing capacities not different from conventional restorations. J Mech Behav Biomed Mater 2019;90:433–440.
143. Maeder M, Pasic P, Ender A, Özcan M, Benic GI, Ioannidis A. Load-bearing capacities of ultra-thin occlusal veneers bonded to dentin. J Mech Behav Biomed Mater 2019;95:165–171.
144. Torbjörner A, Fransson B. Biomechanical aspects of prosthetic treatment of structurally compromised teeth. Int J Prosthodont 2004;17:135–141.
145. Ericson S, Hedegard B, Wennström A. Roentgenographic study of vital abutment teeth. J Prosthet Dent 1966,16:981–987.
146. Schwartz NL, Whitsett LD, Berry TG, Stewart JL. Unserviceable crowns and fixed partial dentures: Life-span and causes for loss of serviceability. J Am Dent Assoc 1970;81:1395–1401.
147. Kerschbaum T, Voß R. Die praktische Bewährung von Krone und Inlay. Dtsch Zahnärztl Z 1981;36:243–250.
148. Pippin DJ, Mixson JM, Soldan-Els AP. Clinical evaluation of restored maxillary incisors: Veneers vs. PFM crowns. J Am Dent Assoc 1995;126:1523–1529.
149. Vailati F, Belser UC. Full-mouth adhesive rehabilitation of a severely eroded dentition: The three-step technique. Part 1. Eur J Esthet Dent 2008;3:30–44.
150. Vailati F, Belser UC. Full-mouth adhesive rehabilitation of a severely eroded dentition: The three-step technique. Part 2. Eur J Esthet Dent 2008;3:128–146.
151. Vailati F, Belser UC. Full-mouth adhesive rehabilitation of a severely eroded dentition: The three-step technique. Part 3. Eur J Esthet Dent 2008;3:236–257.
152. Lussi A, Hellwig E, Ganss C, Jaeggi T. Buonocore memorial lecture. Dental erosion. Oper Dent 2009;34:251–262.
153. Signore A, Benedicenti S, Covani U, Ravera G. A 4- to 6-year retrospective clinical study of cracked teeth restored with bonded indirect resin composite onlays. Int J Prosthodont 2007;20:609–616.
154. Geurtsen W, Schwarze T, Günay H. Diagnosis, therapy, and prevention of the cracked tooth syndrome. Quintessence Int 2003;34:409–417.
155. Vailati F, Bruguera A, Belser UC. Minimally invasive treatment of initial dental erosion using pressed lithium disilicate glass-ceramic restorations: A case report. Quint Dent Technol 2012;35:1–14.
156. Goldstein MB. No-prep/minimal-prep: The perils of oversimplification. Dent Today 2007;26:10.
157. Nosti J. "Thin is in" the art of minimal & no prep veneer. J N J Dent Assoc 2009;80:30–31.
158. Lowe RA. No-prep veneers: A realistic option. Dent Today 2010;29:80–82,84,86.
159. Mizrachi M, Lowe RA. A new and economical concept no-prep veneers. Dent Today 2011;30:138,140,142–143.
160. Wells D. Low-risk dentistry using additive-only ("no-prep") porcelain veneers. Compend Contin Educ Dent 2011;32:50–55.
161. Freydberg BK. No-prep veneers: The myths. Dent Today 2011;30:70–71.



t.me/Dr_Mouayyad_AlbtousH

162. Friedman MJ. Porcelain veneer restorations: A clinician's opinion about a disturbing trend. J Esthet Restor Dent 2001;13:318–327.
163. Kabbach W, Clavijo V. Maintenance of partial ceramic restorations and fragments. Clinica 2014;10:370–372.
164. Magne M, Magne I, Bazos P, Paranhos MP. The parallel stratification masking technique: An analytical approach to predictably mask discolored dental substrate. Eur J Esthet Dent 2010;5:330–339.
165. Stein RS, Kuwata M. A dentist and a dental technologist analyze current ceramo-metal procedures. Dent Clin North Am 1977;21:729–749.
166. Highton R, Caputo AA, Matyas J. A photoelastic study of stress on porcelain laminate preparations. J Prosthet Dent 1987;58:157–161.
167. Garber DA. Porcelain laminate veneers: Ten years later. Part I: Tooth preparation. J Esthet Dent 1993;5:57–61.
168. El-Sherif M, Jacob R. The ceramic reverse three-quarter crown for anterior teeth: Preparation design. J Prosthet Dent 1989;61:4–6.
169. Munechika T, Suzuki K, Nishiyama M, Ohashi M, Horie K. A comparison of the tensile bond strengths of composite resins to longitudinal and transverse sections of enamel prisms in human teeth. J Dent Res 1984;63:1079–1082.
170. Rouse JS. Full veneer versus traditional veneer preparation: A discussion of interproximal extension. J Prosthet Dent 1997;78:545–549.
171. Dietschi D, Magne P, Holz J. Bonded to tooth ceramic restorations: In vitro evaluation of the efficiency and failure mode of two modern adhesives. Rev Mens Suisse Odontostomatol 1995;105:299–305.
172. Dietschi D, Herzfeld D. In-vitro evaluation of marginal and internal adaptation of class II resin composite restorations after thermal and occlusal stressing. Eur J Oral Sci 1998;106:1033–1042.
173. Paul SJ, Schärer P. The dual bonding technique: A modified method to improve adhesive luting procedures. Int J Periodontics Restorative Dent 1997;17:536–545.
174. Paul SJ. Effect of a dual application of dentin-bonding agents on shear bond strength of various adhesive luting systems on dentin. In: Adhesive Luting Procedures. Berlin: Quintessence, 1997:89–98.
175. Jayasooriya PR, Pereira PN, Nikaido T, Burrow MF, Tagami J. The effect of a "resin coating" on the interfacial adaptation of composite inlays. Oper Dent 2003;28:28–35.
176. Hu J, Zhu Q. Effect of immediate dentin sealing on preventive treatment for postcementation hypersensitivity. Int J Prosthodont 2010;23:49–52.
177. Johnson GH, Craig RG. Accuracy of addition silicones as a function of technique. J Prosthet Dent 1986;55:197–203.
178. Tjan AH, Whang SB, Tjan AH, Sarkissian R. Clinically oriented evaluation of the accuracy of commonly used impression materials. J Prosthet Dent 1986;56:4–8.
179. Magne P, Magne M, Belser U. Impressions and esthetic rehabilitation. The preparatory work, clinical procedures and materials. Schweiz Monatsschr Zahnmed 1995;105:1302–1316.
180. Tuit CM, Rosen M, Cohen J, Becker PJ. Effect of impression technique and multiple pours on accuracy of stone models. J Dent Assoc S Afr 1991;46:515–518.
181. Löe HL, Silness JS. Tissue reactions to string packs used in fixed restorations. J Prosthet Dent 1963;13:318–323.
182. Nemetz H, Donovan T, Landesman H. Exposing the gingival margin: A systematic approach for the control of hemorrhage. J Prosthet Dent 1984;51:647–651.
183. Magne P, Nielsen B. Interactions between impression materials and immediate dentin sealing. J Prosthet Dent 2009;102:298–305.
184. Ghiggi PC, Steiger AK, Marcondes ML, et al. Does immediate dentin sealing influence the polymerization of impression materials? Eur J Dent 2014;8:366–372.
185. Bruzi G, Carvalho AO, Maia HP, Giannini M, Magne P. Are some combinations of resin liners and impression materials incompatible with immediate dentin sealing? Am J Esthet Dent 2013;3:200–208.
186. Magne P. Noninvasive bilaminar CAD/CAM composite resin veneers: A semi-(in)direct approach. Int J Esthet Dent 2017;12:134–154.
187. Lin CP, Douglas WH. Structure-property relations and crack resistance at the bovine dentin-enamel junction. J Dent Res 1994;73:1072–1078.
188. De Long R, Sasik C, Pintado MR, Douglas WH. The wear of enamel when opposed by ceramic systems. Dent Mater 1989;5:266–271.
189. Seghi RR, Rosenstiel SF, Bauer P. Abrasion of human enamel by different dental ceramics in vitro. J Dent Res 1991;70:221–225.
190. Krejci I, Lutz F, Reimer M. Marginal adaptation and fit of adhesive ceramic inlays. J Dent 1993;21:39–46.
191. Magne P, Oh WS, Pintado MR, De Long R. Wear of enamel and veneering ceramics after laboratory and chairside finishing procedures. J Prosthet Dent 1999;82:669–679.
192. Peumans M, Van Meerbeek B, Lambrechts P, Vuylsteke-Wauters M, Vanherle G. Five-year clinical performance of porcelain veneers. Quintessence Int 1998;29:211–221.
193. Fradeani M. Six-year follow-up with Empress veneers. Int J Periodontics Restorative Dent 1998;18:216–225.
194. Friedman MJ. A 15-year review of porcelain veneer failure—A clinician's observations. Compend Contin Educ Dent 1998;19:625–636.
195. Dumfahrt H. Porcelain laminate veneers. A retrospective evaluation after 1 to 10 years of service: Part II—Clinical results. Int J Prosthodont 2000;13:9–18.
196. Bruce GA. The Herbst method of filling with glass. Dent Rec 1891;11:47–48.
197. Roulet JF, Soderholm KJ, Longmate J. Effects of treatment and storage conditions on ceramic/composite bond strength. J Dent Res 1995;74:381–387.
198. Sorensen JA, Strutz JM, Avera SP, Materdomini D. Marginal fidelity and microleakage of porcelain veneers made by two techniques. J Prosthet Dent 1992;67:16–22.
199. Wall JG, Reisbick MH, Espeleta KG. Cement luting thickness beneath porcelain veneers made on platinum foil. J Prosthet Dent 1992;68:448–450.
200. Sim C, Ibbetson R. Comparison of fit of porcelain veneers fabricated using different techniques. Int J Prosthodont 1993;6:36–42.
201. Sheets CG, Taniguchi T. A multidie technique for the fabrication of porcelain laminate veneers. J Prosthet Dent 1993;70:291–295.
202. Chiche GJ, Pinault A. Impressions for laminate veneers. In: Esthetics of Anterior Fixed Prosthodontics. Chicago: Quintessence, 1994:169–170.
203. Schäfer F, Järschke I, Meyer G. Randschlussgenauigkeit von OD-Inlays aus DUCERAM-LFC Massen. Quelle: Universität Göttingen. In: Komma O. Hydrothermale Dentalkeramik-Systeme: Eine neue Werkstoffklasse. Dokumentation von DUCERA Dental GmbH, 1993.
204. Beham G. IPS-Empress: Eine neue Keramik-Technologie. Ivoclar-Vivadent Report 1990;6:3–14.
205. McPhee ER. Hot-pressed porcelain process for porcelain-fused-to-metal restorations. J Prosthet Dent 1975;33:577–581.




t.me/Dr_Mouayyad_AlbtousH

206. Dong JK, Luthy H, Wohlwend A, Scharer P. Heat-pressed ceramics: Technology and strength. Int J Prosthodont 1992;5:9–16.
207. Materdomini D, Friedman MJ. The contact lens effect: Enhancing porcelain veneer esthetics. J Esthet Dent 1995;7:99–103.
208. Duarte S, Sartori N, Sadan A, Phark JH. Adhesive resin cements for bonding esthetic restorations: A review. Quint Dent Technol 2011;34:41–66.
209. Gresnigt MMM, Özcan M, Carvalho M, et al. Effect of luting agent on the load to failure and accelerated-fatigue resistance of lithium disilicate laminate veneers. Dent Mater 2017;33:1392–1401.
210. Magne M, Bazos P, Magne P. The alveolar model. Quint Dent Technol 2009;32:39–46.
211. Lavigne J, Lucchini JP, Spirgi M. Use of a mounting table for arbitrary hinge transfer on an articulator. Schweiz Monatsschr Zahnheilkd 1979;89:1251–1256.
212. Bowley JF, Michaels GC, Lai TW, Lin PP. Reliability of a facebow transfer procedure. J Prosthet Dent 1992;67: 491–498.
213. Magne M, Magne I, Magne P. Diagnostic waxing transfer from diagnostic casts to soft tissue definitive casts. J Prosthet Dent 2008;100:70–71.
214. Lala C, Miladinov M. Analog & digital different. Dental Dialogue 2019;51:90–104.
215. Borges CFM, Magne P, Pfender E, Heberlein J. Diamond burs made with a new technology. J Prosthet Dent 1999;82:73–79.
216. Patterson CJ, McLundie AC, Stirrups DR, Taylor WG. Efficacy of a porcelain refinishing system in restoring surface finish after grinding with fine and extra-fine diamond burs. J Prosthet Dent 1992;68:402–406.
217. Campbell SD. Evaluation of surface roughness and polishing techniques for new ceramic materials. J Prosthet Dent 1989;61:563–568.
218. Grieve AR, Jeffrey IW, Sharma SJ. An evaluation of three methods of polishing porcelain by comparison of surface topography with the original glaze. Restorative Dent 1991;7:34–36.
219. Sulik WD, Plekavich EJ. Surface finishing of dental porcelain. J Prosthet Dent 1981;46:217–221.
220. Klausner LH, Cartwright CB, Charbeneau GT. Polished versus autoglazed porcelain surfaces. J Prosthet Dent 1982;47:157–162.
221. Scurria MS, Powers JM. Surface roughness of two polished ceramic materials. J Prosthet Dent 1994;71:174–177.
222. Haywood VB, Heymann HO, Kusy RP, Whitley JQ, Andreaus SB. Polishing porcelain veneers: An SEM and specular reflectance analysis. Dent Mater 1988;4:116–121.
223. Haywood VB, Heymann HO, Scurria MS. Effects of water, speed, and experimental instrumentation on finishing and polishing porcelain intra-orally. Dent Mater 1989;5:185–188.
224. Brewer JD, Garlapo DA, Chipps EA, Tedesco LA. Clinical discrimination between autoglazed and polished porcelain surfaces. J Prosthet Dent 1990;64:631–634.
225. Goldstein RE. Creating esthetic restorations through special effects. In: Esthetics in Dentistry. Philadelphia: J.B. Lippincott, 1976:425–455.
226. Magne P, Paranhos MP, Hehn J, Oderich E, Boff LL. Selective masking for thin indirect restorations: Can the use of opaque resin affect the dentine bond strength of immediately sealed preparations? J Dent. 2011;39:707–709.
227. Hein S, Tapia J, Bazos P. eLABor_aid: A new approach to digital shade management. Int J Esthet Dent 2017;2:186–202.
228. Kelly JR. Perspective on strength. Dent Mater 1995;11:103–110.
229. Darr AH, Jacobsen PH. Conversion of dual cure luting cements. J Oral Rehabil 1995;22:43–47.
230. Bortolotto T, Guillarme D, Gutemberg D, Veuthey JL, Krejci I. Composite resin vs resin cement for luting of indirect restorations: Comparison of solubility and shrinkage behavior. Dent Mater 2013;32:834–838.
231. Magne P, Razaghy M, Carvalho MA, Soares LM. Luting of inlays, onlays, and overlays with preheated restorative composite resin does not prevent seating accuracy. Int J Esthet Dent 2018;13:318–332.
232. Suh BI, Feng L, Pashley DH, Tay FR. Factors contributing to the incompatibility between simplified-step adhesives and chemically-cured or dual-cured composites. Part III. Effect of acidic resin monomers. J Adhes Dent 2003;5:267–282.
233. Besek M, Mormann WH, Persi C, Lutz F. The curing of composites under Cerec inlays. Schweiz Monatsschr Zahnmed 1995;105:1123–1128.
234. Friedman MJ. Current state-of-the-art porcelain veneers. Curr Opin Cosmet Dent 1993;28–33.
235. Lee IB, Cho BH, Son HH, Um CM. Rheological characterization of composites using a vertical oscillation rheometer. Dent Mater 2007;23:425–432.
236. Al-Ahdal K, Silikas N, Watts DC. Rheological properties of resin composites according to variations in composition and temperature. Dent Mater 2014;30:517–524.
237. Blalock JS, Holmes RG, Rueggeberg FA. Effect of temperature on unpolymerized composite resin film thickness. J Prosthet Dent 2006;96:424–432.
238. Della Bona A, Northeast SE. Shear bond strength of resin bonded ceramic after different try-in procedures. J Dent 1994;22:103–107.
239. Barghi N, Chung K, Farshchian F, Berry T. Effects of the solvents on bond strength of resin bonded porcelain. J Oral Rehabil 1999;26:853–857.
240. Jardel V, Degrange M, Picard B, Derrien G. Correlation of topography to bond strength of etched ceramic. Int J Prosthodont 1999;12:59–64.
241. Jardel V, Degrange M, Picard B, Derrien G. Surface energy of etched ceramic. Int J Prosthodont 1999;12:415–418.
242. Filho AM, Vieira LC, Araujo E, Monteiro Junior S. Effect of different ceramic surface treatments on resin microtensile bond strength. J Prosthodont 2004;13:28–35.
243. Bruzi G, Carvalho AO, Giannini M, Pires Maia H, Magne P. Post-etching cleaning influences the resin shear bond strength to CAD/CAM lithium disilicate ceramics. Appl Adhes Sci 2017;5:17.
244. Lopes GC, Perdigão J, Baptista D, Ballarin A. Does a self-etching ceramic primer improve bonding to lithium disilicate ceramics? Bond strengths and FESEM analyses. Oper Dent 2019;44:210–218.
245. Sadoun M, Asmussen E. Bonding of resin cements to an aluminous ceramic: A new surface treatment. Dent Mater 1994;10:185–189.
246. Aboushelib MN. Evaluation of zirconia/resin bond strength and interface quality using a new technique. J Adhes Dent 2011;13:255–260.
247. Kern M. Bonding to oxide ceramics—Laboratory testing versus clinical outcome Dent Mater 2015;31:8–14.
248. Barghi N. To silanate or not to silanate: Making a clinical decision. Compend Contin Educ Dent 2000;21:659–662,664.
249. Suh BI. Principle of Adhesion Dentistry. Newtown, PA: Aegis, 2013:156–160.



t.me/Dr_Mouayyad_AlbtousH

250. Hooshmand T, van Noort R, Keshvad A. Bond durability of the resin-bonded and silane treated ceramic surface. Dent Mater 2002;18:179–188.
251. Hooshmand T, van Noort R, Keshvad A. Storage effect of a pre-activated silane on the resin to ceramic bond. Dent Mater 2004;20:635–642.
252. Bruzi G, Carvalho AO, Giannini M, Pires Maia H, Magne P. Bonding of CAD/CAM lithium disilicate restorations with regular and flowable composite resin with and without wetting resin. Appl Adhes Sci 2018;6:10.
253. Queiroz JR, Benetti P, Ozcan M, et al. Surface characterization of feldspathic ceramic using ATR FT-IR and ellipsometry after various silanization protocols. Dent Mater. 2012;28:189–196.
254. Barghi N, Berry T, Chung K. Effects of timing and heat treatment of silanated porcelain on the bond strength. J Oral Rehabil 2000;27:407–412.
255. Gresnigt MMM, Kalk W, Özcan M. Clinical longevity of ceramic laminate veneers bonded to teeth with and without existing composite restorations up to 40 months. Clin Oral Investig 2013;17:823–832.
256. Gresnigt MM, Kalk W, Ozcan M. Randomized clinical trial of indirect resin composite and ceramic veneers: Up to 3-year follow-up. J Adhes Dent 2013;15:181–190.
257. Bergmann P, Noack MJ, Roulet JF. Marginal adaptation with glass-ceramic inlays adhesively luted with glycerine gel. Quintessence Int 1991;22:739–744.
258. Patterson CJ, McLundie AC, Stirrups DR, Taylor WG. Refinishing of porcelain by using a refinishing kit. J Prosthet Dent 1991;65:383–388.
259. Hulterstrom AK, Bergman M. Polishing systems for dental ceramics. Acta Odontol Scand 1993;51:229–234.
260. Jagger DC, Harrison A. An in vitro investigation into the wear effects of unglazed, glazed, and polished porcelain on human enamel. J Prosthet Dent 1994;72:320–323.
261. Al-Hiyasat AS, Saunders WP, Sharkey SW, Smith GM, Gilmour WH. The abrasive effect of glazed, unglazed, and polished porcelain on the wear of human enamel, and the influence of carbonated soft drinks on the rate of wear. Int J Prosthodont 1997;10:269–282.
262. Gresnigt M, Magne M, Magne P. Porcelain veneer post-bonding crack repair by resin infiltration. Int J Esthet Dent 2017;12:156–170.



t.me/Dr_Mouayyad_AlbtousH

t.me/Dr_Mouayyad_AlbtousH



t.me/Dr_Mouayyad_AlbtousH

# MAINTENANCE AND ADVANCED REPAIR TECHNIQUES

Bonded restorations, when applied with the strict protocols described in this book, have proven to represent a very strong assembly with the teeth both in vitro and in vivo. Long-term clinical studies have demonstrated excellent maintenance of esthetics (especially with anterior bonded porcelain restorations), high patient satisfaction, and absence of adverse effects on gingival health. As a result, the maintenance protocol barely differs from that applied to intact natural teeth. This chapter describes some specific maintenance procedures as well as how to address the problems that can be encountered with bonded restorations over time. The repair of old bonded porcelain and composite resin restorations is very similar in nature. The motto of this chapter could very well be "repair rather than replace," as numerous examples of apparently failed restorations will be presented that were approached conservatively and repaired with an excellent prognosis.





t.me/Dr_Mouayyad_AlbtousH

# 7.1 BPRs: MAXIMUM PERFORMANCE, REDUCED MAINTENANCE

Numerous examples have been provided throughout this book demonstrating the outstanding performance of bonded restorations. ***The gold medal of maximum performance at minimum maintenance goes to anterior bonded porcelain restorations (BPRs).***

Early clinical trials show that retention and fracture rates of anterior BPRs were not likely to raise specific concerns.[1–4] At least two clinical studies demonstrated a 100% survival rate over 5 years,[2,4] and two other long-term studies revealed a 90% survival rate and a 93% success rate over 10 and 15 years, respectively.[5,6] These results were confirmed by subsequent studies[7–9]; one of the aforementioned trials[4] even included cases of extreme incisal edge spans (type IIIA), which is the end-of-spectrum indication for BPRs. The results are particularly encouraging because most of these early BPRs (Fig 7-1; 27-year follow-up views in Figs 7-1p to 7-1t; see also Fig 6-84) were solely bonded to enamel (Figs 7-1b and 7-1c) and did not address dentin exposures because dentin adhesion was still debatable at the time of placement. Peumans et al noticed more defects at locations where the restoration margin was located in existing composite resin restorations.[2,7] Gresnigt et al,[10–12] however, demonstrated that these problems could be resolved by applying tribochemical silicoating conditioning and silane to the existing restoration (see process in Fig 7-3).

***The clinical success of bonded restorations in general is undoubtedly linked with (1) the maximum preservation of enamel and dentin, which results in the mimicking of intact tooth biomechanics, and (2) the maximum respect of periodontal tissues.*** This last element is strengthened by the fact that dental porcelain is less susceptible to accumulation of bacterial plaque in comparison to gold, resin, or even hard tooth structures.[13,14] It is therefore not surprising that significant reductions in Plaque Index and plaque bacteria vitality could be observed after the placement of porcelain veneers.[15] According to a 5-year follow-up by Walls,[16] even when the glazed porcelain surface had been removed during finishing procedures at the gingival margins, no changes were observed in either plaque or gingival indices.

***For these various reasons, BPRs might be the most forgiving type of restoration for patients struggling with oral hygiene.***

The excellent clinical results of BPRs can only improve in the future, considering the continuous improvements of ceramic materials and luting techniques (highly filled composite resins with lowered thermal expansion, filled adhesive resin, immediate dentin sealing, etc).

**FIG 7-1 First BPRs (type IIIA) placed by the authors in 1992 with 27-year follow-up.** *(a)* The patient's anterior teeth initially presented defective Class 4 composite resin restorations. *(b and c)* Insertion of the BPRs was carried out only with enamel and ceramic bonding despite localized exposed dentin surfaces (right central incisor after $H_3PO_4$ etching in *b*) and substantial hard tissue breakdown, especially on the left central incisor *(c)*. *(d)* Incisal edge span of the ceramic ranges from 3 to 5 mm. *(e)* One-year postoperative clinical view. *(f and g)* Patient satisfaction at 7-year follow-up is 100%, and no alterations are detected on the radiograph *(h)*. These BPRs have been serving for more than 27 years (see *p* to *t*).



t.me/Dr_Mouayyad_AlbtousH



7-1a



7-1b



7-1c



7-1d




7-1e




7-1f




7-1h




7-1g



t.me/Dr_Mouayyad_AlbtousH

# 7.2 ROUTINE PROFESSIONAL HYGIENE

There are no specific instructions regarding personal hygiene around bonded restorations. As far as brushing and flossing are concerned, the same care and techniques used for natural teeth can be applied to the restored teeth. The clinician or the dental hygienist, however, must follow some specific guidelines during professional hygiene.[17]

## Routine scaling

***No mechanical intervention (scaling or polishing) should be carried out in the absence of gingival inflammation and plaque.***

Only when required (eg, presence of gingivitis, suspected excess of composite resin or calculus), handheld instruments (curette or scaler) should be used in a very tactile and sensitive movement. Careful movements should be made parallel to the gingival contour (Fig 7-1k). Root-to-crown movements should be absolutely avoided (Fig 7-1l), because they could easily chip the margin or ditch the interface.

**The following devices should NEVER be used:**

- Sonic or ultrasonic scalers can create significant damage to the restorative margin (chipping, cracking).
- Air-abrasion polishing systems harm the glaze, cause pitting and staining, and remove the luster.

Sonic or ultrasonic scalers also create adverse effects on intact enamel itself and should not be used for routine tooth cleaning. They should be reserved for first-time removal of hardened, stubborn calculus on intact teeth.[18] Direct contact between oscillating scalers and tooth/restoration surfaces should be prevented at all times.[19]

**FIG 7-1** *(cont)* Follow-up at 7 and 8 years. *(i and j)* Detailed views of the left central incisor show optimal soft tissue and absolute stability of surface texture and gloss compared to the intact lateral incisor. *(j)* Proximal enamel is visible and stained, which supports the idea that more extended interdental penetration would be indicated today. The maintenance protocol was simulated during the 8-year recall visit. *(k)* An explorer or scaler can be used to check the margins and remove hard deposits when required. It is essential to use a gentle movement parallel to the gingival contour. *(l)* Root-to-crown movements are contraindicated because they can undermine and chip off the ceramic margin.



t.me/Dr_Mouayyad_AlbtousH

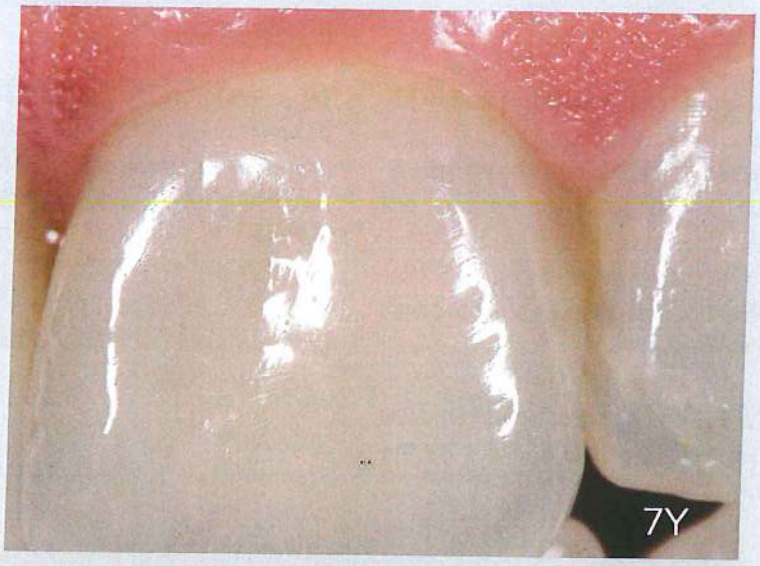


7-1i

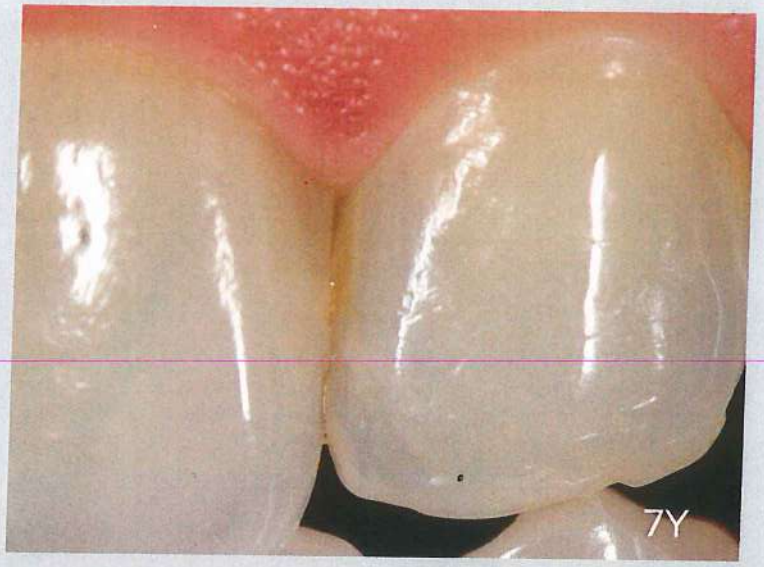


7-1j




7-1k

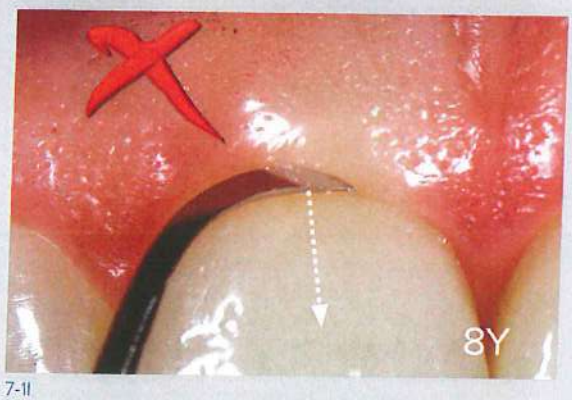


7-1l



t.me/Dr_Mouayyad_AlbtousH

## Polishing

Heavy stains on accessible margins can be removed with fine silicon points (eg, Dialite fine W16D-21, Brasseler) or sonic brushes with dentifrice. Gingivally, placement of a deflection cord always helps in this task (Figs 7-1m and 7-1n). Toothpaste (or extrafine aluminum oxide polishing paste) and a rubber cup can be used to polish the restored tooth (Fig 7-1o).

***Coarse polishing pastes must never be used because they can dull the surface of the restorations.***[20]

## Fluoridation

***Topical fluorides, especially acidulated phosphate fluoride (1.23% APF) gels must not come in contact with the porcelain because they have an etching effect and can damage the ceramic surface.***[21–24]

Sodium fluoride (2% NaF) gels are always preferred because of their inoffensive nature.[22,24]

BIMANUAL CORD PLACEMENT

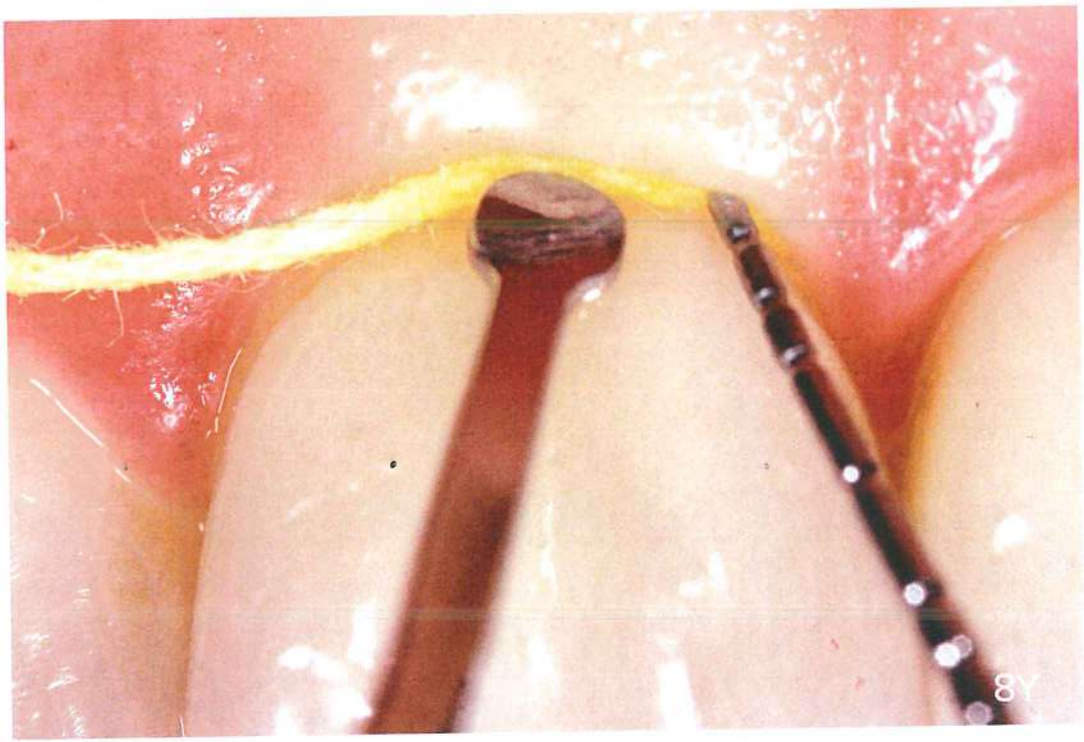

7-1m

**FIG 7-1** *(cont)* Optimal inspection can be carried out when a deflection cord has been placed. *(m)* Trauma to the soft tissues can be prevented by stabilizing the cord with a periodontal probe while a spatula is used to insert the cord into the sulcus (bimanual insertion technique). *(n)* To remove heavy marginal staining, diamond silicon points can be used safely because the deflection cord protects the marginal gingiva. *(o)* Final polishing can be carried out simply with a soft rubber cup and dentifrice to prevent damage to the ceramic surface. *(p to t)* The veneers are still in good condition after 27 years of clinical service (follow-up photography courtesy of Dr Francesca Vailati, Geneva, Switzerland). Note that the envelope of function *(t)* clearly includes the restorations and overlaps the lingual margins, which did not affect the long-term performance of those type IIIA BPRs.



t.me/Dr_Mouayyad_AlbtousH

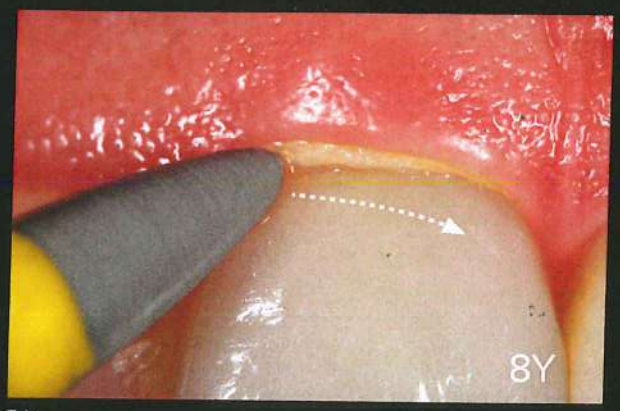


7-1n

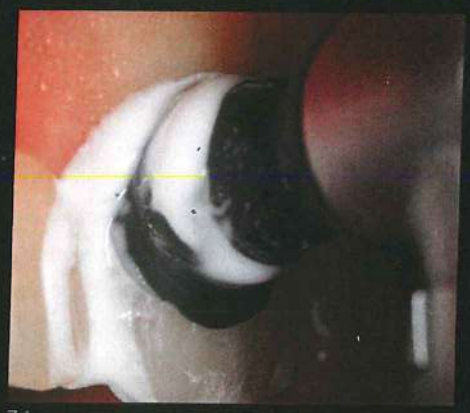

7-1o




7-1p



7-1q




7-1r

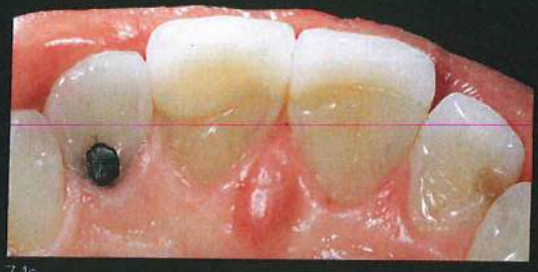

7-1s

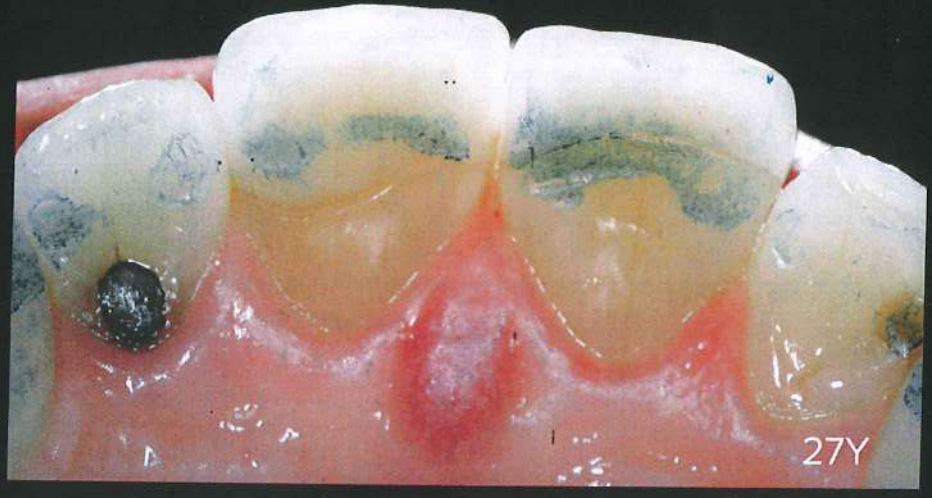


7-1t


t.me/Dr_Mouayyad_AlbtousH

# 7.3 COMPLICATIONS AND REPAIRS

## Prevention

***A common-sense and preventive measure to reduce wear and attenuate the risk of failure entails providing the restored patient with a hard acrylic occlusal splint to be worn at night (aka, the "dental helmet"). Such an appliance is absolutely indicated for patients with acknowledged nighttime clenching or grinding habits, with or without restorations.***

However, clinical experience clearly shows that pain-free patients usually do not comply very well in wearing such preventive splints, even when a minimum thickness of resin is achieved for maximum comfort (Fig 7-2). On the other hand, splints designed for therapeutic reasons have proven their efficacy and are actually used by the patients because they really feel a physical need (eg, myofascial pain). For purely preventive devices, unfortunately the patient's response is not so positive.

### Repair vs replace

Postbonding cracks,[25,26] chipping,[27] fractures,[6,7,16] and microleakage[6,28] are among the possible complications of bonded restorations; these problems and the related factors have been presented and widely discussed throughout this book. Long-term data for porcelain veneers have been provided by Friedman,[6] who reported 7% of complications over 15 years of clinical service. When facing complications, however, clinicians may traditionally decide to replace the restorations rather than repair them. Depending on the type of complication, there is no evidence, however, to suggest that replacement presents a better prognosis than the repair of bonded restorations.

Clinical studies have demonstrated that *(1)* repair is minimally invasive and can increase the longevity of restorations,[7,29–31] and *(2)* repair failure rates are low, and repaired restorations are less likely to require invasive treatment (endodontic treatment, extraction) than replaced restorations.[32]

In addition, the "friendliness" of adhesive restoration complications must be emphasized because in most cases, repair can be carried out with simple means at minimum costs, unlike ***complications with traditional coverage crowns that are more likely to require endodontic treatment and extraction.***[33]

## Basic armamentarium

The excellent reparability of bonded restorations can be attributed to the developments of intraoral repair systems and tools.

***Among these, the intraoral sandblaster represents the most essential device for repair (Fig 7-3) along with the use of silicatization (tribochemical silicoating) and silanization.***[34,35]

Surface roughening by etching has undoubtedly the strongest effect on ceramic-resin bond strength.[36] However, intraoral use of hydrofluoric acid (HF) is controversial and even prohibited in some countries. Efficient surface roughening can be obtained in vivo by airborne-particle abrasion with the intraoral sandblaster, which represents an efficient and safe procedure when combined with the use of a silane as explained hereinafter.

**FIG 7-2 Preventive hard acrylic maxillary nightguard.** *(a)* Restored patients (BPRs on maxillary incisors) must be considered as patients with intact teeth. Hence, it is recommended that at-risk individuals (clenchers and bruxers) be given a preventive/protective appliance such as a maxillary splint *(b)* with full-arch coverage for interocclusal protection and anterior guidance *(c)*.


t.me/Dr_Mouayyad_AlbtousH



7-2a



7-2c



7-2b




7-3a

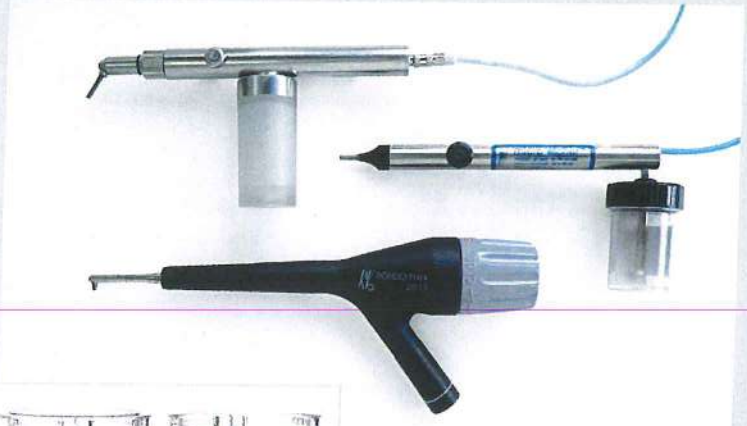







7-3b

**FIG 7-3 Portable intraoral sandblasters.** *(a)* There are a number of devices that can be hooked directly to the high-speed air-driven connectors, including *(top to bottom)* Dento-Prep (Ronvig), Microetcher (Danville), and Rondoflex (KaVo). Blasting pressure is 2 to 3 bar (30–42 psi). It is mandatory that the patient's eyes and airways be protected (with a mask or a wet towel and rubber dam, respectively) and that intense suction be used to avoid dissemination of the sand. The container can be loaded with various types of sand. AquaCare by Velopex, on the other hand, is a standalone system only requiring air pressure (Venturi) and with the possibility to change sand via a cartridge system (overlay in part *a*). *(b)* Silica-modified sand (eg, CoJet or SilJet) is recommended for intraoral use.



t.me/Dr_Mouayyad_AlbtousH

A fine sand with 30-µm particles has been developed specifically for intraoral use (Fig 7-3b; eg, CoJet by 3M or SilJet by Danville). Because this sand has been modified with silica, it will simultaneously allow the roughening and incorporation of silica (silicatization) into the restoration surface (Fig 7-3c), whether ceramic or composite resin. This tribochemical coating process produces a silica-enriched surface, which will then react with the silane (chemical coupling). Tribochemically modifying the porcelain and using a silane results in a significant increase of bonding characteristics.[37,38] Intraoral silicoating/silane has been available since 1993 and is also effective on amalgam, metal alloy, composite resins, hybrid ceramics (PICN), feldspathic ceramics, alumina, and zirconia-based ceramics.[34,39]

***Applying tribochemical silicoating and silane to existing composite resin restorations (eg, Class 2 and 3) is also indicated before the delivery of porcelain veneers as part of the tooth preparation conditioning.***[10–12]

## Maintenance by resurfacing/repair

A first example of minor surface maintenance and repair after 11 years of successful service is presented in Fig 7-4 in a case of fragment reattachment (see original treatment in chapter 3, Fig 3-25). The clinical steps are the same whether it is a ceramic-only repair (see next section "Chipping repair" and Fig 7-5) or a mixed composite resin and enamel repair (Fig 7-4).

**FIG 7-3** *(cont) (c)* Silicoating process. CoJet is made of corundum particles (hard aluminum oxide) modified by silica *(top left)*. When particles are blasted against the substrate (metals, ceramics, composite resins), a high-temperature impact produces energy *(top middle*; high-temperature triboplasma indicated with crosses). Blasting pressure is 2 to 3 bar (30–42 psi). Components of the modified particles are incorporated into the substrate *(top right; red line)*. There is no significant increase of the substrate temperature as a whole but only at a microscopic level of the surface. The silicated surfaces have increased reactivity with silane solutions to develop a covalent bond with resin as explained in Fig 6-76a (covalent siloxane bond –Si-O-Si-). (Modified from 3M instructions for use of CoJet.)

**FIG 7-4 Resurfacing of rebonded fragments after 11 years.** The central incisors had fractured 11 years before, and the fragments had been rebonded (fragment reattachment technique presented in chapter 3, Fig 3-25). *(a and b)* There is staining at the mesial margins (but no infiltration) and a small chipping fracture at the distoincisal edge of the left central incisor. *(c)* After proper isolation, the overlapping composite resin became well visible and was removed at the mesial margins.

**FIG 7-4** *(cont, next pages)* The repair surfaces were silicoated for about 5 to 10 seconds *(d)* and etched with phosphoric acid for 30 seconds *(e)*, then rinsed and thoroughly air-dried. *(f)* Silane was applied, thoroughly air-dried, and left alone for 5 minutes to completely dry. Low-viscosity filled adhesive resin was applied, air-thinned, and polymerized *(g)*, and a high-value enamellike composite resin was applied *(i)*, shaped, and polymerized. *(j and k)* The same procedures were repeated on the other side. *(l to n)* Finished and polished repair immediately after removal of rubber dam *(l)* and after rehydration (*n*; baseline fracture for comparison in *m*).



t.me/Dr_Mouayyad_AlbtousH

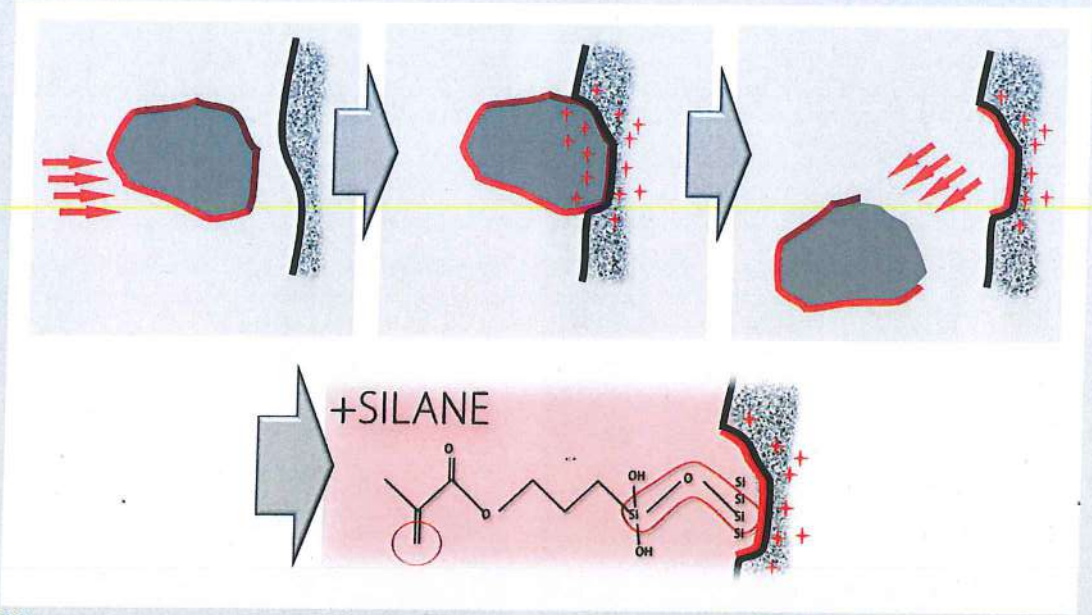


7-3c




7-4a



7-4b



7-4c



t.me/Dr_Mouayyad_AlbtousH

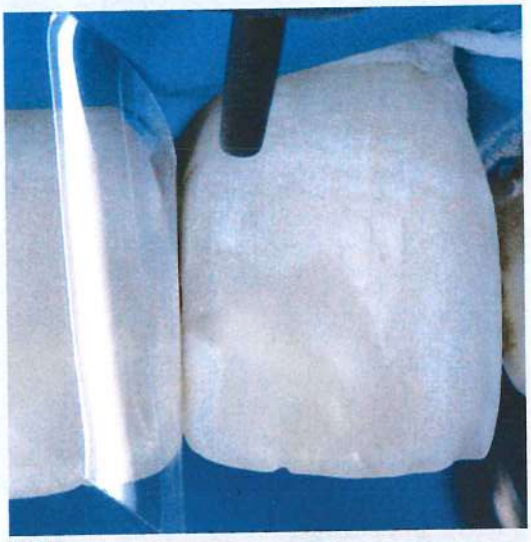

7-4d



7-4e



7-4f



7-4g

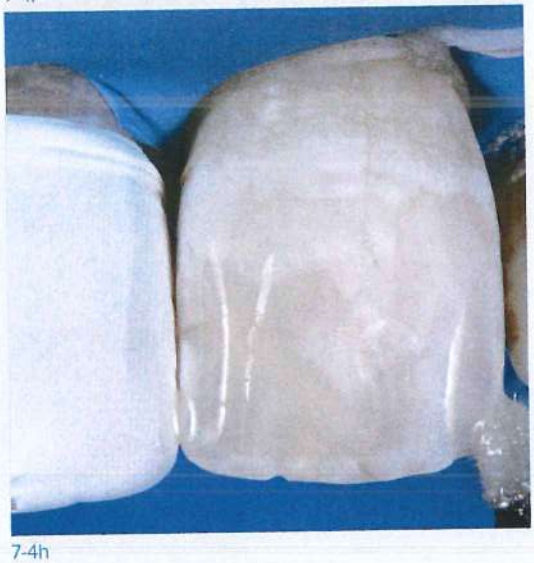

7-4h



7-4i



t.me/Dr_Mouayyad_AlbtousH



7-4j



7-4k



7-4l

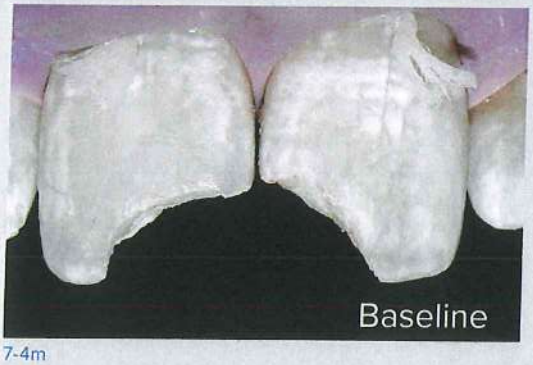


7-4m




7-4n



t.me/Dr_Mouayyad_AlbtousH

## Chipping repair

*Chipping* is defined as a cohesive fracture that occurs within the body of the porcelain or composite resin in areas of intense point loading (usually by fatigue or accidental traumatic force). Minor chipping of the incisal edge can occur at any time during the life of a restoration. The pattern of this defect resembles very much the enamel chipping found in aging intact teeth.

***When esthetics or function is not compromised, the chipped surface can be selectively polished with fine-grain diamond burs and diamond-impregnated silicon points and left as is.***

In more severe cases, replacement of the lost fragment is required. Conditioning of the fractured surface by airborne-particle abrasion (tribochemical silicoating as explained in Fig 7-3c) and silanization is required, and the following procedure can be recommended, whether dealing with chipped ceramic (Fig 7-5) or composite resin restorations:

1. Isolate the dental segment under rubber dam and protect the patient's airways from sand inhalation (mask over eyes and nose).
2. Gently roughen the fractured surface with a diamond bur at low speed (in case of ceramic, remove the glaze layer surrounding the fracture).
3. Load silicoating sand into intraoral sandblaster.
4. Check efficiency on a metal strip (metal must turn a uniform dark color).
5. **Air-abrade the chipped surface with CoJet for about 5 to 10 seconds** (depending on the surface area, up to 15 seconds for entire labial surface); neighboring teeth should be protected with a metal matrix.
6. The surface can be cleaned with phosphoric acid for 30 seconds (optional), rinsed, and thoroughly air-dried.
7. **Apply silane** for 20 to 40 seconds and thoroughly air-dry; eventually heat-dry with hair dryer at low power or light-polymerization unit. A 5-minute delay (completely dry) after silanization will enhance the effect of the silane. The silanated surface should not look shiny.
8. Apply low-viscosity adhesive resin and air-thin.
9. Restore with light-polymerizing composite resin and finish as for a natural tooth.

**FIG 7-5 Repair of chipped porcelain veneer.** *(a)* The patient presented with a chipped porcelain veneer and admitted having chewed over a metal fork. *(b)* Rubber dam is placed over the anterior teeth. The fracture is 100% cohesive, and no other alterations of the remaining tooth-restoration complex are detected. *(c)* A metal strip has been wedged to protect the neighboring tooth during tribochemical airborne-particle abrasion with CoJet. Depending on the defect size, use of adhesive tape is recommended to protect the intact surrounding ceramic surface (see Fig 7-11b). *(d)* A 60-second cleaning with $H_3PO_4$ (followed by rinsing and thorough air-drying) may precede the application of the silane. *(e)* Evaporation of the solvent and condensation of the silane requires time (> 5 minutes), but the process can be accelerated with dry warm air (eg, hair dryer at low power); the patient must not be anesthetized to be able to respond in case of excessive application of heat. *(f)* After the defect has been coated with low-viscosity adhesive resin and air-thinned, a regular light-curing restorative composite resin can be used. *(g)* Excess composite resin can be detected by rubbing articulating paper over the facial surface. *(h)* Following gross excess removal with a scalpel, the restoration can be finished with silicon points and polishing disks; this BPR has been serving for more than 6 years.



t.me/Dr_Mouayyad_AlbtousH



7-5a



7-5b



7-5c



7-5d



7-5e



7-5f



7-5g



7-5h



t.me/Dr_Mouayyad_AlbtousH

## Fracture repair

This section illustrates fracture repairs in three cases; the fractures occurred after 7, 13, and 5 years of clinical service, respectively (Figs 7-6 to 7-8). In all cases, the ceramic fragment could be recovered and reattached successfully. Following careful elimination of the remaining composite resin, the rebonding was carried out in the same manner as a classical luting procedure. The exact cause of such failures can vary; two scenarios must be distinguished and can even be mixed on the same tooth:

- **The luting composite resin remained on the tooth, which suggests debonding at the porcelain/composite resin interface** (Fig 7-6): This could be the result of improper bonding (eg, omission of adhesive resin to wet the etched porcelain), contamination of the etched surface (eg, omission of ultrasonic cleaning following HF etching), or improper use of silane coupling agents (eg, excess, inappropriate drying), among other factors.
- **The luting composite resin remained on the ceramic workpiece, which suggests debonding at the tooth/composite resin interface** (see Fig 7-8). This scenario seems to occur essentially when the underlying tooth substrate is dentin. In the case of indirect restorations, improper dentin bonding often results from the application mode of the dentin bonding agent (eg, omission of immediate dentin sealing [IDS] as described in chapter 4, section 4.4).

The repair procedures (fragment rebonding or repair with composite resin) follows the principle described for the chipping repair (previous page) with only minor differences (Table 7-1):

1. Before the repair (conditioning of the fractured surface of the tooth) starts, **the exposed dentin must be sealed by IDS**.
2. The fragment must be cleaned from eventual composite resin remnants with a diamond bur at low speed.
3. After the refining of the enamel and restorative edges and airborne-particle abrasion, the fragment must be tested again to ensure that the fit is not compromised by the presence of the IDS layer.
4. The fragment must be treated like a restoration and the fitting surface conditioned accordingly.

The sequence described in Fig 7-13 (replacement of a Class 3 composite resin in contact with a porcelain veneer) is also similar to the fracture repair when the fragment is missing.

**FIG 7-6 Partial loss of BPR by cervical fracture without dentin exposure.** *(a)* The cervical part of this BPR lost retention during its 7th year of clinical service. *(b)* The patient fortunately recovered the ceramic fragment, and no dentin was exposed. Luting composite resin remained on the tooth, revealing a possible problem in the conditioning of the ceramic workpiece. The fragment was first cleaned (inner surface and fractured edge) then etched with HF acid and silanized, as would have been applied for a new veneer. *(c)* Because traditional luting procedures will be applied, placement of rubber dam is required. *(d and e)* Following elimination of luting composite resin remnants from the tooth surface with a diamond bur at low speed, the intraoral sandblaster (with CoJet) was used for final cleaning and roughening, including the fractured porcelain edge. Final conditioning of the tooth surface was carried out with phosphoric acid etching (enamel + roughened ceramic), silane being then applied to the fractured edge. Exposed dentin would have required the additional use of a dentin bonding agent (IDS) before the repair. *(f)* Adhesive resin and a regular restorative composite resin were used to deliver the fragment. *(g)* The final view shows adequate integration of the reattached fragment and invisible repair line. *(h)* The result is stable after 8 months of clinical service despite the patient's rather poor oral hygiene. This BPR has been serving for more than 8 years.



t.me/Dr_Mouayyad_AlbtousH




7-6a



7-6b



7-6c



7-6d

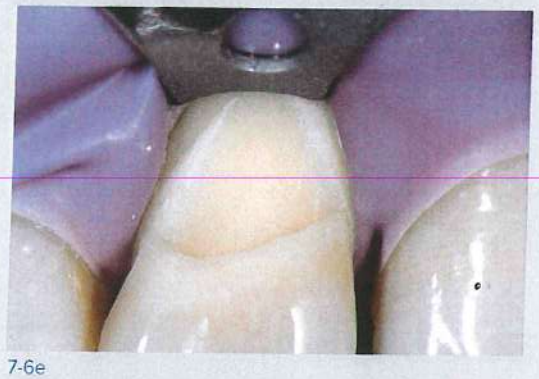

7-6e

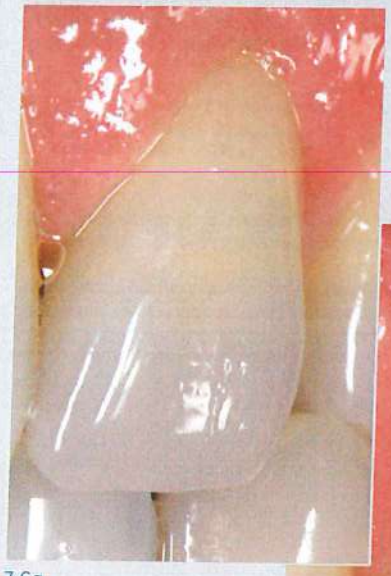

7-6g



7-6f



7-6h



t.me/Dr_Mouayyad_AlbtousH

**TABLE 7-1** Step-by-step procedures for fracture repair with and without fragments

| With fragment | Without fragment |
|---|---|
| 1. Isolate the dental segment under rubber dam and protect the patient's airways from sand inhalation. | |
| 2. **In the presence of exposed dentin, seal the exposed dentin according to the IDS protocol:** Use a diamond bur to freshly cut the dentin, followed by etching, priming, placement of adhesive resin, polymerization, and air-blocking. | |
| 3. **Clean and roughen the fractured surface and enamel** with a diamond bur at low speed (in case of ceramic, remove the glaze layer surrounding the fracture). No composite resin remnants must be found. | |
| 4. Load silicoating sand into the intraoral sandblaster. | |
| 5. Check the efficiency on a metal strip (metal must turn to a uniform dark color). | |
| 6. **Air-abrade the fractured tooth/restoration surface with CoJet for about 5 to 10 seconds** (depending on the surface area); neighboring teeth should be protected with a metal matrix. | |
| 7. **Test the fragment fit** and seating on the tooth. If the IDS layer is interfering, slightly adjust the fitting surfaces. | 7. **Etch the fractured tooth/restoration surface** with phosphoric acid for 30 seconds, rinse, and thoroughly air-dry. |
| 8. **Clean and roughen the fitting surface of the fragment** with a diamond bur at low speed. No composite resin remnants must be found. **Condition the fragment fitting surface as indicated for that material** (HF acid etching for ceramics, airborne-particle abrasion for composite resin). | 8. **Apply silane to the restoration surface** for 20–40 seconds, thoroughly air-dry, and eventually heat-dry with a hair dryer at low power or light-polymerization unit. A 5-minute delay (completely dry) after silanization will enhance the effect of the silane. The silanated **surface should not look shiny**. |
| 9. **Etch the fractured tooth/restoration and fragment fitting surfaces** with phosphoric acid for 30 seconds, rinse, and thoroughly air-dry. If a ceramic fragment, clean in an ultrasonic bath. | 9. Apply low-viscosity adhesive resin and air-thin. |
| 10. **Apply silane to the fractured tooth/restoration and fragment** fitting surfaces for 20–40 seconds, thoroughly air-dry, and eventually heat-dry with a hair dryer at low power or light-polymerization unit. A 5-minute delay (completely dry) after silanization will enhance the effect of the silane. The silanated **surface should not look shiny**. | 10. Restore with light-polymerizing composite resin and finish as for a natural tooth. |
| 11. Apply low-viscosity adhesive resin to the fractured tooth/restoration and fragment fitting surfaces and air-thin. | |
| 12. Deliver the fragment with light-polymerizing composite resin* and finish as for a regular bonded restoration. | |

*In case of deficient marginal adaptation of a fragment, choose a dentin shade of composite resin.

**FIG 7-7 Porcelain onlay fracture after 13 years.** *(a to d)* This vital maxillary first molar was restored with a bonded porcelain overlay (*d* was taken after more than 7 years of clinical service). No effective dentin bonding strategy was available at the time of placement. Only adhesion to marginal enamel was used (dentin was protected with a cement liner). *(e and f)* Signs of fracture appeared after 12 years, and the complete fracture of the distolingual cusp (and part of the mesiolingual cusp) was observed at year 13 (note the cement liner attached to the fragment). Following the repair and reattachment of the fragment under rubber dam *(g and h)*, the restoration kept serving appropriately *(i)*. *(j)* A minor repair of the mesiolingual margin was performed at year 15. *(k)* The same restoration is still in service at year 20. (Parts *e* to *h* courtesy of Dr Francesca Vailati, who also performed the repair.)



t.me/Dr_Mouayyad_AlbtousH



7-7a



7-7b



7-7c




7-7d




7-7e



7-7f



7-7g



7-7h



7-7i




7-7j




7-7k



t.me/Dr_Mouayyad_AlbtousH

Figure 7-8 depicts an enlightening case where the same tooth was accidentally subjected to two different bonding methods: A major area of exposed dentin at the mesial aspect of the right lateral incisor was sealed with the IDS technique before impression making (Fig 7-8a), and exposed dentin at the distal face of the same tooth went undetected and was sealed only at the time of insertion by applying the adhesive system but not prepolymerizing the adhesive resin. As a possible consequence of this erroneous dentin hybridization approach, the distal half of the restoration fractured after almost 5 years of clinical service (Fig 7-8d). This course of events is totally in accordance with clinical data published by Dumfahrt showing that veneers partially bonded to dentin (without IDS) have an increased risk of failure.[5] This cannot be said about veneers partially bonded to dentin with the IDS technique. According to an 11-year prospective clinical trial, the success rate of veneers bonded to dentin (> 50% exposure) increases from 82% without IDS to 98% with IDS.[40] In addition, the amount of scientific evidence in favor of IDS is overwhelming as explained in chapter 4 (section 4.4); IDS will benefit any type of semi-(in)direct or indirect restoration.

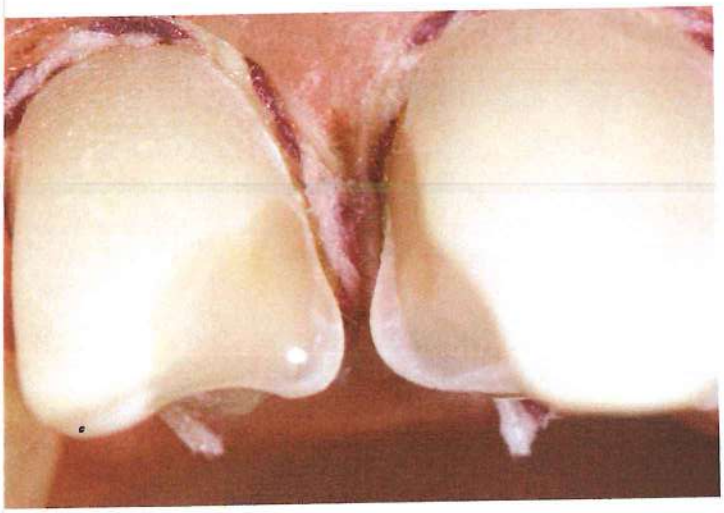

7-8a

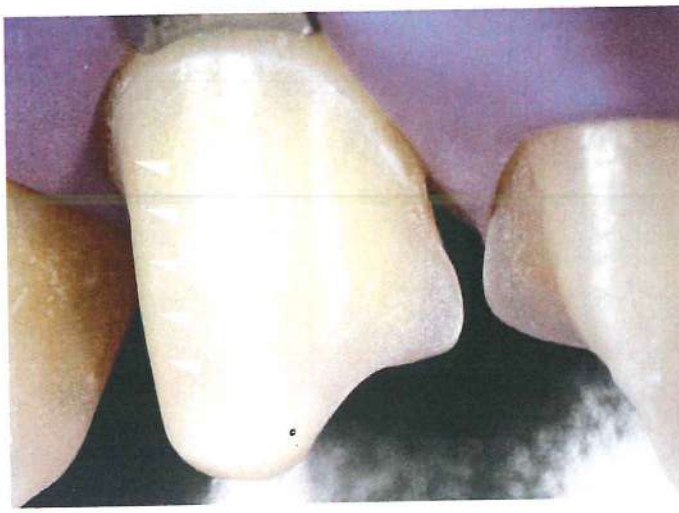

7-8b



7-8c

**FIG 7-8 Long-term success of BPR repair.** This clinical situation is ideal for IDS. *(a)* Following tooth preparations, the removal of existing interdental composite resins left large dentin exposures, which were immediately treated with IDS prior to taking the final impression. *(b)* On the subsequent visit, when proceeding to luting the restorations, it was noticed that a large dentin exposure had been missed by IDS at the distal surface of the lateral incisor *(arrows)*. This area was treated (etched and primed) independently after sandblasting/etching, and the adhesive resin was placed without prepolymerization to allow the complete seating of the restoration with the luting composite resin. *(c)* The final result looks fine. *(d)* However, the distal half of the restoration fractured after 5 years of clinical service.



t.me/Dr_Mouayyad_AlbtousH




7-8d




7-8e

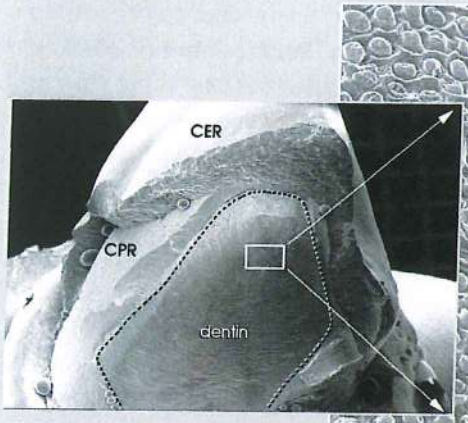


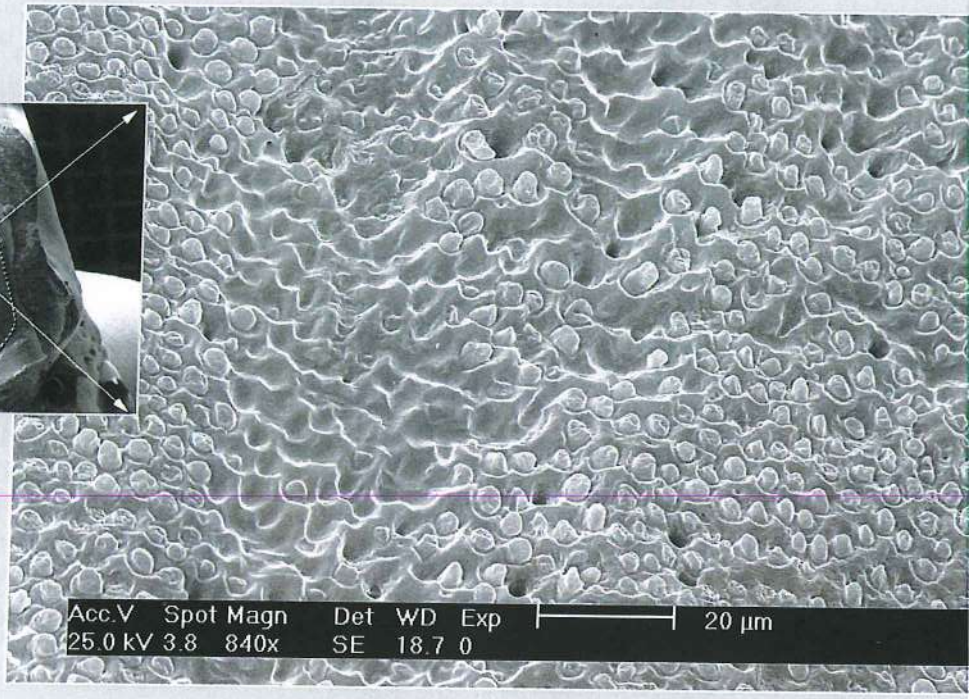


7-8f

**FIG 7-8** *(cont)* Despite the distal fracture at 5 years, the mesial aspect of the restoration, which was originally bonded with the IDS technique, is still well-bonded *(d)*. *(e)* The luting composite resin (CPR) is attached to the distal ceramic fragment. *(f)* Closer SEM analysis of the tooth surface revealed the large area of exposed dentin *(right and dotted area in left)*; this is the area that had been missed by IDS. Its shape fits exactly the composite resin remnants on the fragment. Dentin hybridization and resin tags are well visible *(right in f)* but failed to bond to the overlaying composite resin. *(g)* The repair was successful as seen after 21 years of clinical service and minor maintenance (maintenance by Dr Didier Dietschi). The same case is presented in chapter 6, Fig 6-85.




7-8g



t.me/Dr_Mouayyad_AlbtousH

# 7.4 POSTBONDING CRACK INFILTRATION

## General considerations

As illustrated in Figs 7-6 to 7-8, a fractured fragment can be easily reattached with an excellent esthetic outcome and prognosis. Postbonding cracks once constituted a problematic complication because there were originally no procedures to address this problem. If tolerated by the patient, flaws were only monitored, and no specific intervention was recommended. Patients must be informed that cracking does not constitute a risk for the remaining underlying tooth substance.

***Microscopic cracks can originate from an accumulation of factors including preparation errors (sharp internal edges), tensile stress release after porcelain firing (lack of segmentation) especially with type IIIA veneers (thick incisal restoration with thin labial extensions), delivery/preparation errors (eg, alumina airborne-particle abrasion of the porcelain before etching; Fig 7-9), patient-related factors, and sometime unknown causes.***

These flaws can occur quite early in the life of a BPR without showing any signs of progression over the years (see example in chapter 6, Fig 6-55).[4] Those defects sometime mimic enamel cracks found in antagonist teeth (Fig 7-9) or are in continuation to an existing crack on the same tooth (Fig 7-10). This is a reminder that enamel cracks are physiologic (ie, part of the normal aging process; see chapter 1, section 1.6) and that, in this context, porcelain cracks cannot be considered an absolute failure. ***Replacement of cracked BPRs should be carried out only in the case of esthetically unpleasant flaws (deeply stained) or upon the patient's request and refusal to attempt a repair procedure.***

## Resin infiltration repair

A recent publication demonstrated that resin infiltration of cracked veneers was possible and may offer a more reasonable and much simpler alternative to replacement.[41] Figure 7-11 illustrates the successful repair and 2-year follow-up of a postbonding crack that had occurred 2 weeks after delivery of a type IIIA BPR. More details about the steps are illustrated in another case in Fig 7-12, with a successful outcome after 6 years.

**FIG 7-9 Postbonding vertical cracks originating from prebonding use of aluminum oxide airborne-particle abrasion.** Six maxillary porcelain veneers were delivered (canine to canine) and displayed short-term cracks. The cracks mimic the vertical enamel cracks of antagonist teeth. It was noted that the veneers' fitting surfaces were air-abraded with aluminum oxide before etching the porcelain. This is the only error that was noted in the clinical protocol and therefore likely to explain the situation. Alumina particles have sharp edges, and the high-speed impact with the porcelain can cause microscopic failure to evolve after delivery due to the additional stresses caused by resin shrinkage and function. Dental technicians avoid alumina particles altogether and use 50-micron glass beads at low pressure (1.5 bar/22 psi) instead when cleaning off the refractory material from the fitting surface of the restorations.

**FIG 7-10 "Biomimetic" crack in 6-year-old anterior BPRs.** *(a)* Clinical examination of 6-year-old porcelain veneers in high-wear case. *(b)* Note the crack on the left central incisor initiating from the lingual surface and following precisely the continuation of an existing enamel crack on the lingual surface *(arrows)*.



t.me/Dr_Mouayyad_AlbtousH



7-9




7-10a

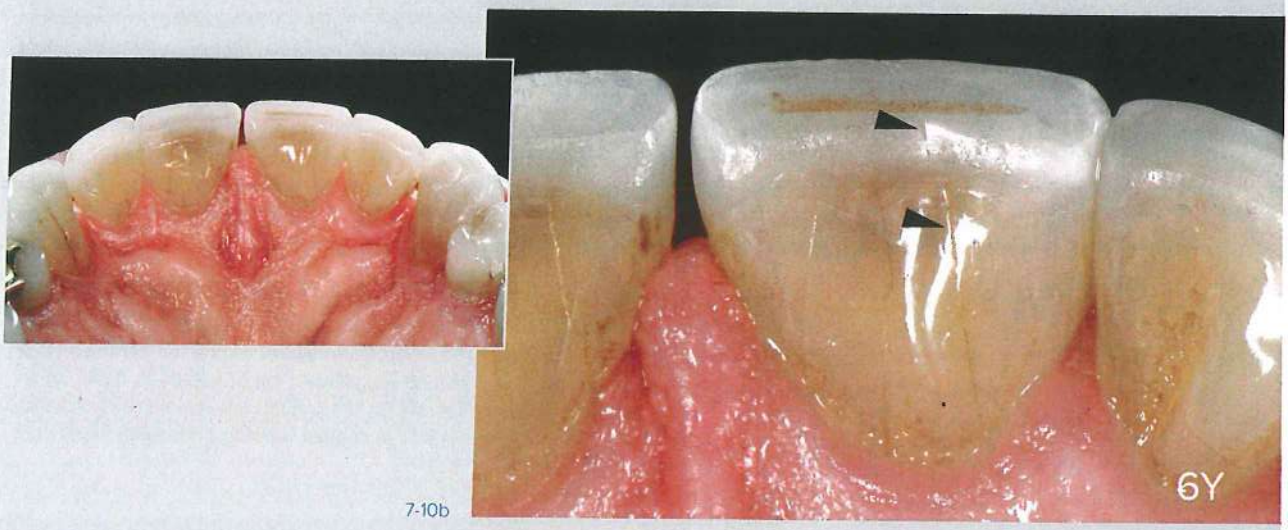


7-10b



t.me/Dr_Mouayyad_AlbtousH

The resin infiltration repair includes the following steps:

1. Isolate the dental segment under rubber dam and protect the patient's airways from sand inhalation (mask over eyes and nose).
2. If indicated, **further isolate any craze line with adhesive tape** (otherwise neighboring teeth should be protected with a metal matrix).
3. Load silicoating sand into the intraoral sandblaster.
4. Check the efficiency on a metal strip (metal must turn a uniform dark color).
5. **Air-abrade the craze line to open the fracture surface** (5 to 10 seconds at 2 bar/30 psi for about 15 seconds).
6. Optional: The surface can be cleaned with phosphoric acid for 30 seconds, rinsed, and thoroughly air-dried.
7. **Apply silane** for 20–40 seconds, thoroughly air-dry, and eventually heat-dry with a hair dryer at low power or light-polymerization unit. A 5-minute delay (completely dry) after silanization will enhance the effect of the silane. The silanated surface should not look shiny.
8. **Apply low-viscosity adhesive resin in excess and let infiltrate for 15 to 20 minutes** (unpolymerized). Apply composite resin if indicated (concavity or volume defect).
9. Light-polymerize for 20 seconds.
10. Apply glycerin jelly, polymerize for 20 seconds, and finish as for a regular repair, if needed.

In the case of failure to infiltrate (crack still visible), gently open craze line with a pointed diamond bur at low speed and restart at step 3. Add regular composite resin restoration as needed at step 8 or after step 9.

**FIG 7-11 Short-term postbonding crack with successful resin infiltration.** *(a)* Cross-polarized image of maxillary incisors of a patient 2 weeks after delivery of a type IIIA porcelain veneer on the maxillary left central incisor. The crack happened at the junction between the labial extension and incisal bulk of porcelain (level of incisal preparation line). *(b)* Because of its labial location, the craze line was carefully isolated with adhesive tape to protect the intact labial surface of the restoration from airborne-particle abrasion. The steps included CoJet air abrasion (to open the fracture surface; 5 to 10 seconds at 2 bar/30 psi), HF acid etching/rinsing (9.6% for 60 seconds; note that this is optional and is only indicated when the crack is fully accessible and away from the gingival line), silane application (20 to 40 seconds, followed by air-drying and another 5 minutes of drying time), infiltration with adhesive resin for 15 to 20 minutes (OptiBond FL, Kerr), and light polymerization for 20 seconds, air-blocking, and polymerization again. *(c)* The crack is still invisible after 2 years. (Parts *a* to *c* courtesy of Dr Marco Gresnigt; parts *a* and *b* reproduced with permission from Gresnigt et al.[41])

**FIG 7-12 Resin infiltration of medium-term postbonding cracks originating from the lingual surface.** The patient presents with a bonded porcelain crown on a nonvital tooth with a metal post and composite resin core (maxillary right central incisor). This restoration had been placed simultaneously to a porcelain veneer on the left central incisor. *(a)* The patient detected a labial crack after 5 years of clinical service and was offered the possibility to repair rather than replace and avoid the difficult single incisor shade-matching dilemma. *(b)* The lingual view reveals the possibility that the crack originated from focal stresses at the surface of the ceramic in contact with the underlying metal post head. (Parts *a* and *b* reproduced with permission from Gresnigt et al.[41])



t.me/Dr_Mouayyad_AlbtousH





7-11a

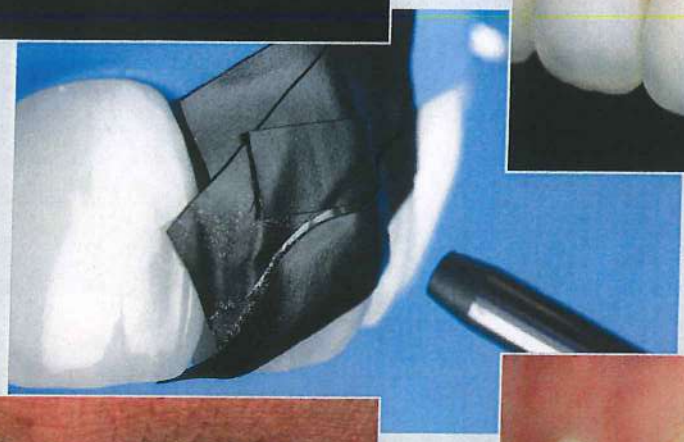

7-11b







7-11c

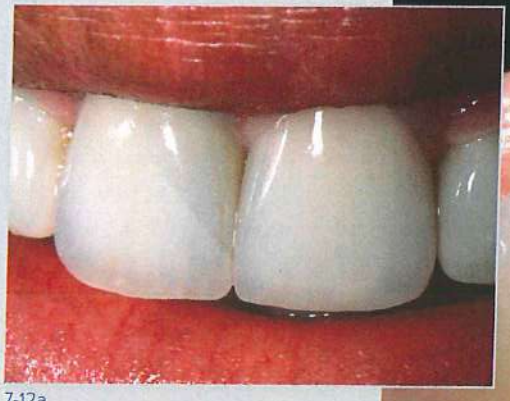

7-12a




7-12b



t.me/Dr_Mouayyad_AlbtousH



7-12c



7-12d



7-12e

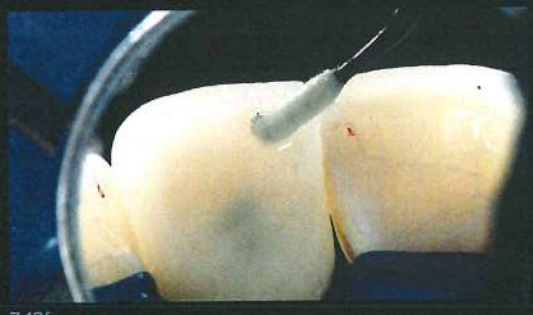

7-12f



7-12g

**FIG 7-12** *(cont)* In view of the likely lingual origin of the crack, it was decided to proceed to resin infiltration from the lingual side only. Air abrasion clearly aggravated the original defect *(c and d)*; however, it improved the ability for the silane and adhesive resin to penetrate the microscopic space *(e and f*, respectively). *(g)* The unpolymerized resin was left to infiltrate for 15 minutes before polymerization. *(h)* The infiltration was efficient enough to reach the labial aspect of the lesion, which is no longer visible (compare before and after, *top left* overlay and *top right* overlay). *(i)* The lesion is still invisible 6 years after the repair (for a total of 11 years of clinical service) despite the fact that no HF acid etching was used. (Part *d* reproduced with permission from Gresnigt et al.[41])


t.me/Dr_Mouayyad_AlbtousH

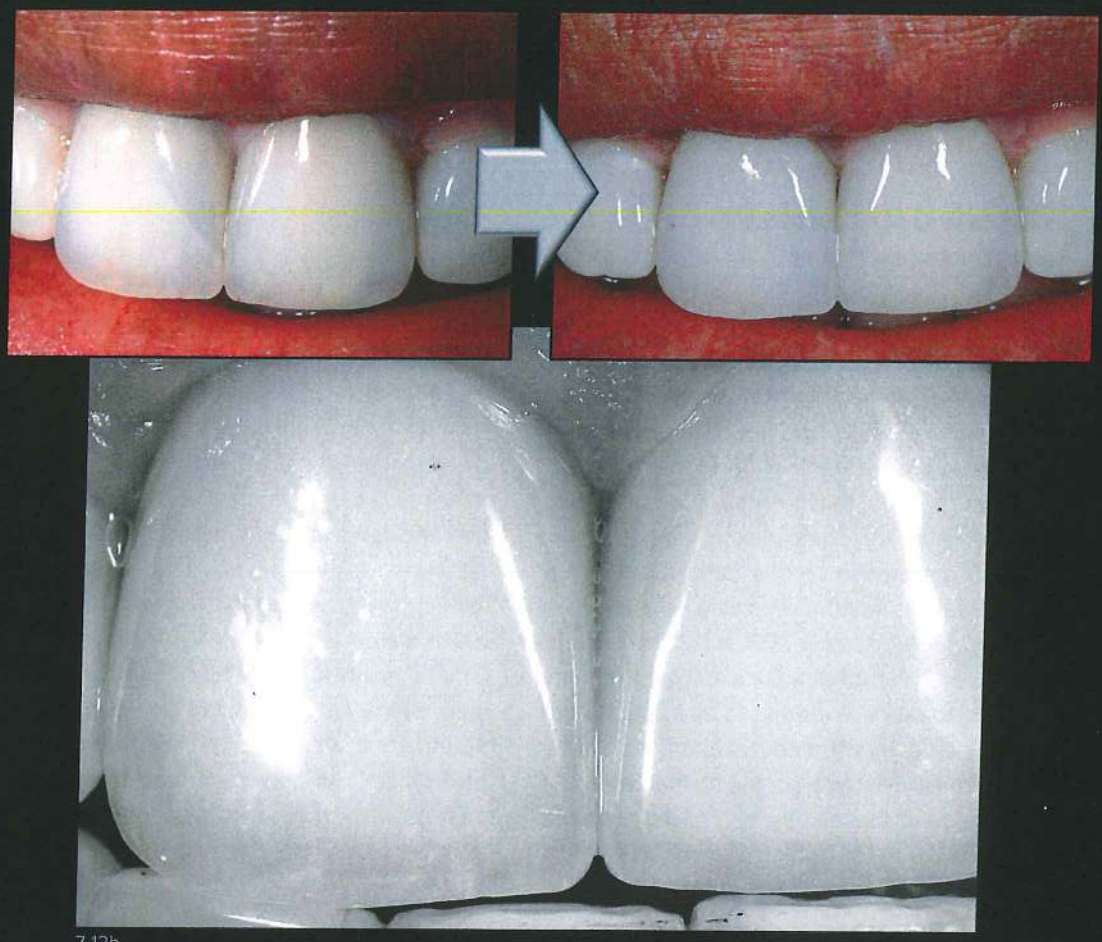

7-12h

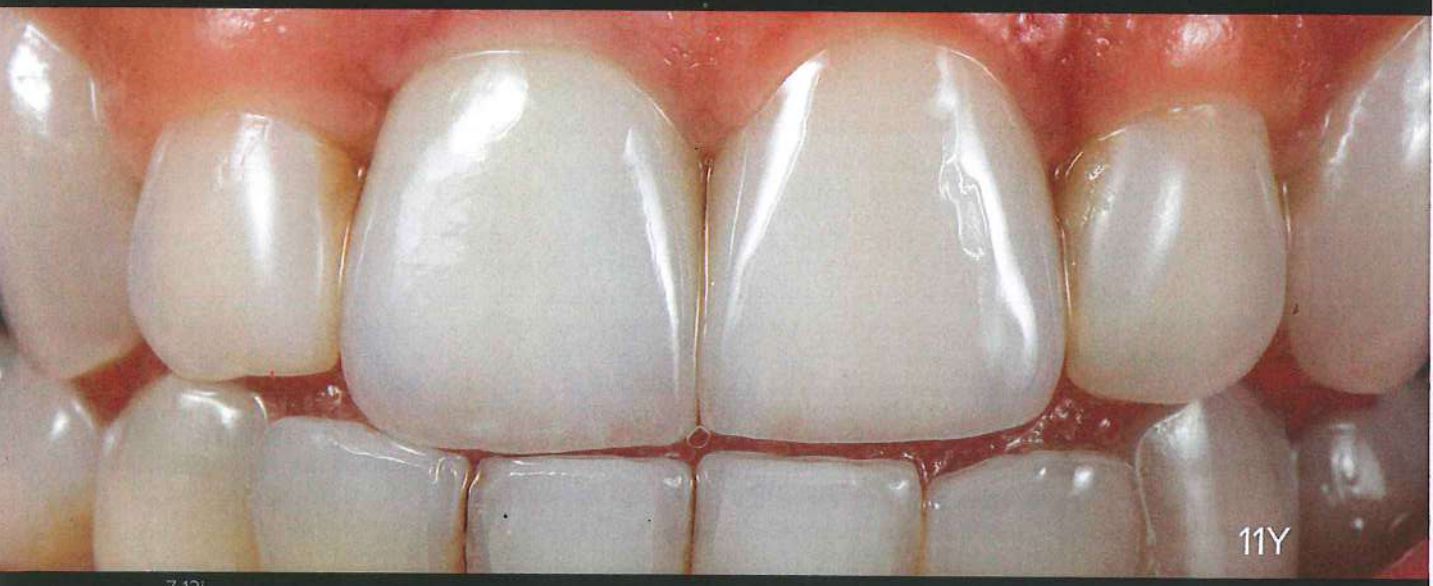


7-12i



t.me/Dr_Mouayyad_AlbtousH

# 7.5 REPLACEMENT OF CLASS 3 COMPOSITE RESIN RESTORATIONS ADJACENT TO BPRs

In a number of clinical situations, veneers are placed over existing yet clinically acceptable interdental composite resin restorations (see chapter 6, Fig 6-19). The partial wraparound design proves to be a wise and conservative choice, and excellent adaptation can be obtained between new BPRs and preexisting interdental composite resins:[42,43] Due to the favorable survival of BPRs, the question may be raised whether ulterior replacement or need of a new Class 3 restoration can be carried out with a lingual access without removing or altering an existing labioproximal BPR. As is the case in previously described repair situations, intraoral bonding to porcelain seems to be a critical step. It has been demonstrated that future restorative procedures initiated from the palatal aspect of veneered incisors can be successful provided that appropriate ceramic surface conditioning is achieved.[43]

Here again, intraoral application of HF acid must be carefully assessed, especially in the presence of an opened preparation with exposed dentin. The alternative procedure using tribochemical silicoating is recommended instead (Fig 7-13; see also repair of fracture without fragment in Table 7-1). First, the cleaned exposed dentin must be sealed with a dentin bonding agent (as is the case for IDS). For a smooth esthetic transition, the margins of Class 3 preparations must be beveled, including the buccal aspect (interface with the ceramic) if the restoration margin is visible. Following placement of a metal matrix to protect the neighboring tooth, the ceramic (and the rest of the preparation) is air-abraded, etched for 30 seconds with 35% phosphoric acid, and silanated. Further steps of the restorative procedure are similar to those for an intact tooth.

**FIG 7-13 Step-by-step adhesive procedure for the replacement of a Class 3 composite resin restoration beneath an existing porcelain veneer.** *(A)* The existing restoration and eventual decay are removed. *(B and B')* The clean exposed dentin is immediately sealed; any dentin bonding agent can be used as long as the manufacturer's protocol is followed. *(C)* An enamel bevel of about 1 mm is created (no ceramic bevel needed if the veneer margin is in the contact area). *(D)* A protective metal matrix is placed, and the ceramic margin is airborne-particle abraded for 5 to 10 seconds. *(E)* The enamel and ceramic margins are etched for 30 seconds with phosphoric acid. *(F)* The ceramic margin is silanated and dried thoroughly with air followed by a 5-minute drying time. *(G and G')* Adhesive resin is applied and immediately polymerized followed by incremental restoration with composite resin.



t.me/Dr_Mouayyad_AlbtousH

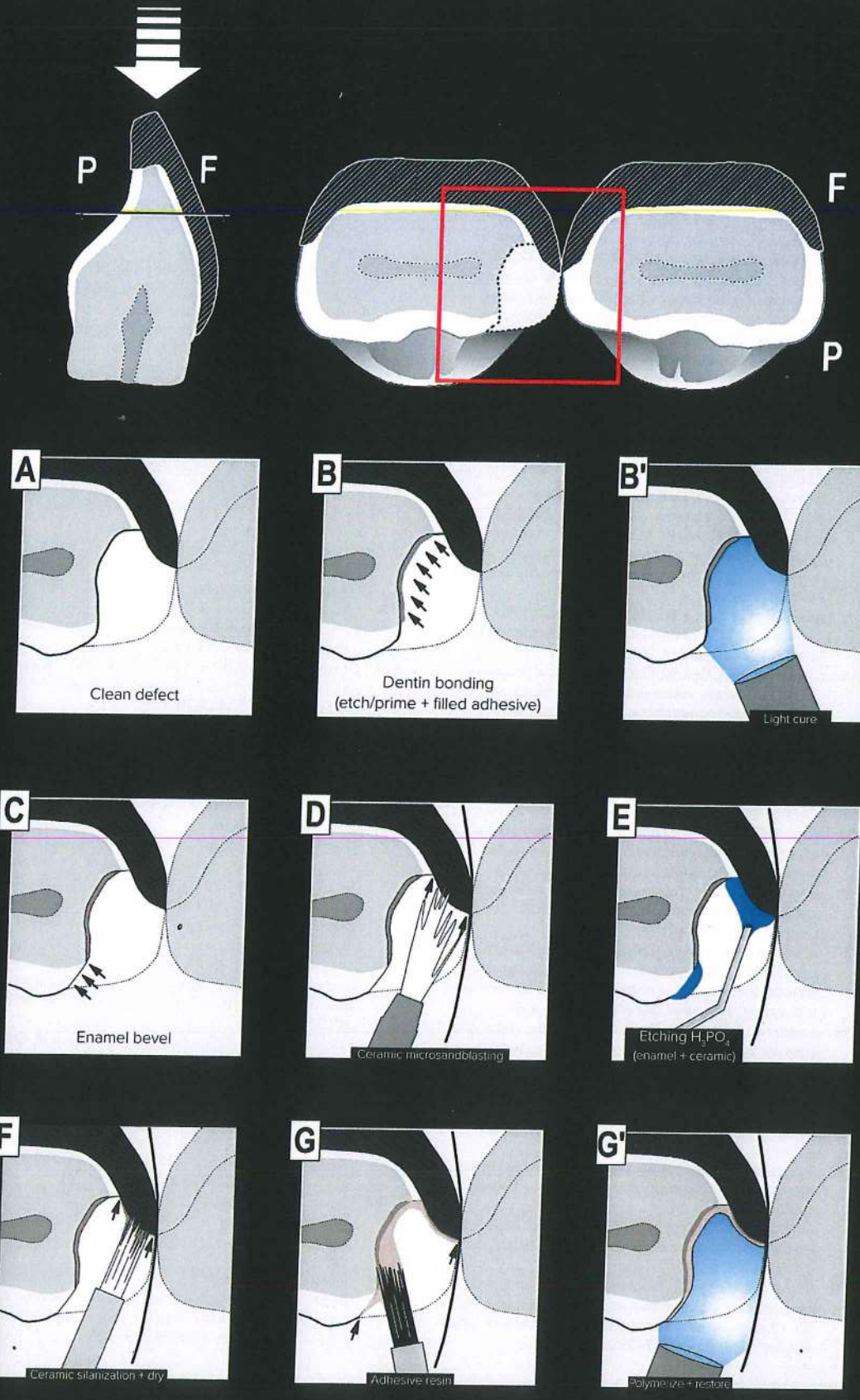


7-13



t.me/Dr_Mouayyad_AlbtousH

# REFERENCES


1. Calamia JR. Clinical evaluation of etched porcelain veneers. Am J Dent 1989;2:9–15.
2. Peumans M, Van Meerbeek B, Lambrechts P, Vuylsteke-Wauters M, Vanherle G. Five-year clinical performance of porcelain veneers. Quintessence Int 1998;29:211–221.
3. Fradeani M. Six-year follow-up with Empress veneers. Int J Periodontics Restorative Dent 1998;18:216–225.
4. Magne P, Perroud R, Hodges JS, Belser U. Clinical performance of novel-design porcelain veneers for the recovery of coronal volume and length. Int J Periodontics Restorative Dent 2000;40:441–457.
5. Dumfahrt H. Porcelain laminate veneers. A retrospective evaluation after 1 to 10 years of service: Part II—Clinical results. Int J Prosthodont 2000;13:9–18.
6. Friedman MJ. A 15-year review of porcelain veneer failure—A clinician's observations. Compend Contin Educ Dent 1998;19:625–636.
7. Peumans M, De Munck J, Fieuws S, Lambrechts P, Vanherle G, Van Meerbeek B. A prospective ten-year clinical trial of porcelain veneers. J Adhes Dent 2004;6:65–76.
8. Fradeani M, Redemagni M, Corrado M. Porcelain laminate veneers: 6- to 12-year clinical evaluation—A retrospective study. Int J Periodontics Restorative Dent 2005;25:9–17.
9. Beier US, Kapferer I, Burtscher D, Dumfahrt H. Clinical performance of porcelain laminate veneers for up to 20 years. Int J Prosthodont 2012;25:79–85.
10. Gresnigt MMM, Kalk W, Özcan M. Clinical longevity of ceramic laminate veneers bonded to teeth with and without existing composite restorations up to 40 months. Clin Oral Investig 2013;17:823–832.
11. Gresnigt MM, Ozcan M, Kalk W, Galhano G. Effect of static and cyclic loading on ceramic laminate veneers adhered to teeth with and without aged composite restorations. J Adhes Dent 2011;13:569–577.
12. Gresnigt MM, Kalk W, Ozcan M. Randomized clinical trial of indirect resin composite and ceramic veneers: Up to 3-year follow-up. J Adhes Dent 2013;15:181–190.
13. Chan C, Weber H. Plaque retention on teeth restored with full-ceramic crowns: A comparative study. J Prosthet Dent 1986;56:666–671.
14. Koidis PT, Schroeder K, Johnston W, Campagni W. Color consistency, plaque accumulation, and external marginal surface characteristics of the collarless metal-ceramic restoration. J Prosthet Dent 1991;65:391–400.
15. Kourkouta S, Walsh TT, Davis LG. The effect of porcelain laminate veneers on gingival health and bacterial plaque characteristics. J Clin Periodontol 1994;21:638–640.
16. Walls AWG. The use of adhesively retained all-porcelain veneers during the management of fractured and worn anterior teeth: Part 2. Clinical results after 5 years of follow-up. Br Dent J 1995;178:337–340.
17. Miller LM. Porcelain veneer protection plan: Maintenance procedures for all porcelain restorations. J Esthet Dent 1990;2:63–66.
18. Plagmann HC, Wartenberg M, Kocher T. Changes in the enamel surface after calculus removal. Dtsch Zahnarztl Z 1989;44:285–288.
19. Topoll HH, Lange DE, Hugelmyer T, Hannemann D. Surface changes of enamel, root cementum and fillings after treatment with tooth cleaning instruments. Dtsch Zahnarztl Z 1989;44:387–390.
20. Sugiyama T, Kameyama A, Enokuchi T, et al. Effect of professional dental prophylaxis on the surface gloss and roughness of CAD/CAM restorative materials. J Clin Exp Dent 2017;9:e772–e778.
21. Jones DA. Effects of topical fluoride preparations on glazed porcelain surfaces. J Prosthet Dent 1985;53:483–484.
22. Wunderlich RC, Yaman P. In vitro effect of topical fluoride on dental porcelain. J Prosthet Dent 1986;55:385–388.
23. Demirhanoglu ST, Sahin E Effects of topical fluorides and citric acid on overglazed and autoglazed porcelain surfaces. Int J Prosthodont 1992;5:434–440.
24. Kula K, Kula TJ. The effect of topical APF foam and other fluorides on veneer porcelain surfaces. Pediatr Dent 1995;17:356–361.
25. Barghi N, Berry TG. Post-bonding crack formation in porcelain veneers. J Esthet Dent 1997;9:51–54.
26. Magne P, Kwon KR, Belser UC, Hodges JS, Douglas WH. Crack propensity of porcelain laminate veneers: A simulated operatory evaluation. J Prosthet Dent 1999;81:327–334.
27. Nordbo H, Rygh-Thoresen N, Henaug T. Clinical performances of porcelain laminate veneers without incisal overlapping: 3-year results. J Dent 1994;22:342–345.
28. Lacy AM, Wada C, Du W, Watanabe L. In vitro microleakage at the gingival margin of porcelain and resin veneers. J Prosthet Dent 1992;67:7–10.
29. Opdam NJ, Bronkhorst EM, Loomans BA, Huysmans MC. Longevity of repaired restorations: A practice based study. J Dent. 2012;40:829–835.
30. Fernández E, Martín J, Vildósola P, et al. Can repair increase the longevity of composite resins? Results of a 10-year clinical trial. J Dent 2015;43:279–286.
31. Loomans B, Özcan M. Intraoral repair of direct and indirect restorations: Procedures and guidelines. Oper Dent 2016;41(S7):S68–S78.
32. Gordan VV, Riley JL 3rd, Rindal DB, et al; National Dental Practice-Based Research Network Collaborative Group. Repair or replacement of restorations: A prospective cohort study by dentists in The National Dental Practice-Based Research Network. J Am Dent Assoc 2015;146:895–903.
33. Smales RJ, Berekally TL. Long-term survival of direct and indirect restorations placed for the treatment of advanced tooth wear. Eur J Prosthodont Restor Dent 2007;15:2–6.
34. Edelhoff D, Marx R, Spiekermann H, Yildirim M. Clinical use of an intraoral silicoating technique. J Esthet Restor Dent 2001;13:350–356.
35. Staxrud F, Dahl JE. Silanising agents promote resin-composite repair. Int Dent J 2015;65:311–305.
36. Roulet JF, Soderholm KJ, Longmate J. Effects of treatment and storage conditions on ceramic/composite bond strength. J Dent Res 1995;74:381–387.
37. Sun R, Suansuwan N, Kilpatrick N, Swain M. Characterisation of tribochemically assisted bonding of composite resin to porcelain and metal. J Dent 2000 Aug;28:441–445.
38. Robin CD, Scherrer SS, Wiskott HWA, de Rijk WG, Belser UC. Weibull parameters of composite resin bond strengths to porcelain and noble alloy using the Rocatec system. Dent Mater 2002;18:389–395.




t.me/Dr_Mouayyad_AlbtousH

39. Flury S, Dulla FA, Peutzfeldt A. Repair bond strength of resin composite to restorative materials after short- and long-term storage. Dent Mater 2019;35:1205–1213.
40. Gresnigt MMM, Cune MS, Schuitemaker J, et al. Performance of ceramic laminate veneers with immediate dentine sealing: An 11 year prospective clinical trial. Dent Mater 2019;35:1042–1052.
41. Gresnigt M, Magne M, Magne P. Porcelain veneer post-bonding crack repair by resin infiltration. Int J Esthet Dent 2017;12:156–170.
42. Christgau M, Friedl KH, Schmalz G, Edelmann K. Marginal adaptation of heat-pressed glass-ceramic veneers to Class 3 composite restorations in vitro. Oper Dent 1999;24:233–244.
43. Magne P, Douglas WH. Cumulative effects of successive restorative procedures on anterior crown flexure: Intact versus veneered incisors. Quintessence Int 2000;31:5–18.



t.me/Dr_Mouayyad_AlbtousH



t.me/Dr_Mouayyad_AlbtousH

# THE WHOLE STORY: FROM LA CHAUX-DE-FONDS TO LOS ANGELES

Who we are is the result of our "story." This story encompasses the environment in which we were born, how we were received by our family and educated by our parents and schools, how we were affected and guided by those around us, and how we affected others. This small biography describes the intellectual and spiritual awakening that changed the first author's life forever! Nothing happened by chance in this amazing journey at the University of Life.

*For you formed my inward parts; you knitted me together in my mother's womb. I praise you, for I am fearfully and wonderfully made. Wonderful are your works; my soul knows it very well. My frame was not hidden from you, when I was being made in secret, intricately woven in the depths of the earth. Your eyes saw my unformed substance; in your book were written, every one of them, the days that were formed for me, when as yet there was none of them.*

*—Psalm 139:13–16*





t.me/Dr_Mouayyad_AlbtousH

## Albin and Agnès

My parents both grew up in rural areas of Switzerland. My father, Albin, was born in 1931 to a family of farmers. Despite his deep love for farming and animals, when he came of age he had to look for job opportunities elsewhere because his older brothers were going to run the farm. My mother, Agnès, endured a tough childhood under authoritarian parents who ran a small bakery and grocery store. Despite her love for reading and learning, when she came of age she was forced by her parents to learn sewing in a boarding school. My parents therefore shared a similar but too common story in the sense that they had to follow a different professional path than the one they would have chosen. They married in 1955 after meeting at a wine festival when my father was 24 and my mother was 21. While they were dating, my father would cycle 100 km from Geneva to visit her in the country on the weekends; my mother sewed her own wedding dress.



Albin and Agnès Magne civil wedding in Geneva (1955).

## Marina, Michel, and me: Life around jail from La Chaux-de-Fonds to Neuchâtel

My sister, Marina, was born in Geneva on January 1, 1956, precisely 47 years before my daughter was born in the same city. Later that year my father accepted a job as adjunct jailor in the city of La Chaux-de-Fonds, and our family started our jailhouse adventure. My brother, Michel, was born there in 1958, and I was born in 1966, a month after Easter.

My parents chose the name Pascal, which means *Passover* (from the Hebrew *Pesach* or Greek *Pascha*). As a newborn, I was extremely underweight because my pylorus did not work properly, so I would regurgitate all my food. Despite feeling helpless, my mother persevered and fed me every hour. It was undoubtedly a very difficult time for the whole family. It was my first struggle with life, but thanks to the love and dedication of my parents, I made it through.



Pascal and mother in Lake Neuchâtel (1966).

We later moved into a service apartment located in the jail building, where both my



t.me/Dr_Mouayyad_AlbtousH

parents were involved. My mother helped to organize meals for the inmates, my sister sometimes accompanying her in the jail garden, and would also help in the kitchen or in admission of female inmates. At home, like many working-class women in that area, she assembled parts for watchmaking companies, unknowingly handling radioactive luminescent material containing radium. (My mother died of lung cancer in 1997.)

In January 1969, my father was promoted to Jail Director in the nearby city of Neuchâtel, and our service apartment was connected to the 30-cell jail via intercom. I still like to joke with my friends that we grew up in jail; our entire family life would run at the rhythm of the jail schedule. Because my dad was so courageous and compassionate with the inmates, whom he called his "guests," those guests would later greet my dad by his first name as we walked the streets of Neuchâtel.

## My brother's influence and my career choice

Upon finishing his mandatory school in the mid 1970s, my brother, Michel, began an apprenticeship at a dental laboratory. Despite his previous ambivalence about art, he was immediately filled with passion for dental technology, especially morphology and ceramics. For his final exams to become a dental technician, Michel had to fabricate a ceramic incrustation "riveted" into a gold framework. He fell in love with porcelain and decided that dental ceramist would be his call. Today he would describe it as 3D painting.

As a child I always looked up to my big brother, and he has undoubtedly had quite an influence on who I am today. During my high school years, Michel attended lectures with Dr Harold Shavell (from Chicago) and Mr Willi Geller (from Zurich). He was always sharing with me the photographic slides he took during those lectures. Dr Shavell's amazing amalgam sculptures and Mr Geller's lifelike porcelain were going to stay deeply imprinted in my brain. Michel was excelling in porcelain, generating an enormous amount of full-arch works as an in-house technician in various dental offices. I was struck by the beauty of his works.

Before making a final choice of career, I decided to spend 1 week shadowing my own dentist in Neuchâtel. I fell in love with what I saw—the meticulous work, the small instruments, especially endodontics. I enrolled at the "Faculté de Médecine."

But I almost quit the first week. I was sitting in a class about genetics and could not understand a single word. I was devastated and told my parents that I would never make it. Thank God I persevered, instead completing my first year with the best grades of my class. I had developed a unique study method in which I would generate typed-out summaries of my class notes and then further summarize those (also typewritten). Those documents were so condensed and succinct that they became known to the student body and were shared by students during many years to follow (including my nephew 13 years later!). This study method would accompany me for the rest of my career.

During the summer break of 1985, I found a job in an industrial butchery. The work was brutal, and my hands were frozen. But each day after work, I would pass by this computer store. Once day there was a new computer in the window, so I went in to check it out. When the salesperson started to move the cursor with what he called a "mouse," I was totally stunned. I had never used a computer, and I could not believe what I was seeing. I was already dreaming about how this tool would help me in my new study method. Of



Pascal and Michel (May 1967).



t.me/Dr_Mouayyad_AlbtousH

course this computer was the Apple Macintosh, and with a display of 256 × 256 pixels, 64 kB of RAM (no hard drive), and an 8-bit processor, the device was selling at $2,500 (would be equivalent to $6,400 today). I decided to go for it. My parents helped. That computer was going to be my study partner for the next 7 years. Thank God university tuition fees in Switzerland were minimal and my parents were going to be able to support me entirely.

## αΩ.2 EARLY ACADEMIC LIFE AND THE BROTHERS

### The big move to Geneva School of Dental Medicine – Becoming a DMD

I left home for the first time in the fall of 1985 for my second year of medicine in Geneva. The separation from my parents felt like a tear in my heart. I would study hard during the week and jump on the train back to Neuchâtel to spend the weekends with my family. At school I was a good student but not a great one. I had to work much harder than my classmates to get the same results. My driving force was my determination to complete my studies as efficiently as possible to remove from my parents the burden of financial support.

I remember very well my first patient. It was during emergency services. The young woman was a drug addict and had left her dog in her car to come to the appointment. I was trying so hard to complete the caries cleanup and place a temporary restoration, and she was getting impatient, worried about her dog. It was intense. It reminded me of that first day at university 3 years earlier. ***I could have abandoned it all. But here again, perseverance and study allowed me to break through.***

I became a DMD at age 23 in the summer of 1989. For my final practical exam, I had to do two amalgam restorations, two anterior Class 3 composite resin restorations, a full crown preparation including provisional acrylic crown, and an extraction. Many of my classmates and I were immediately hired by the school as teaching faculty, especially at the preclinical level. I had applied for faculty positions in both Conservative Dentistry and Fixed Prosthodontics. I was



Second year of dental school in Geneva (1987).

unsure about this and had also planned to return to Neuchâtel and practice there as an associate. I was first hired part-time in the Division of Restorative Dentistry in Geneva, which would allow me to work part-time in my hometown. However, during my last days at school, I came across Professor Urs Belser in the stairway. He had previously told me there was no available position in his division (Fixed Prosthodontics), yet he announced to me that day that he decided to hire me after all. It was rare to be hired in both divisions, which allowed me to become immediately a full-time lecturer. It was the fall



t.me/Dr_Mouayyad_AlbtousH

of 1989, and I was able to start my career without a loan. Young hires had to teach preclinical courses for several years before being allowed to teach in the patients' clinics. In the Division of Restorative Dentistry, I joined the team of Dr Didier Dietschi (my mentor and true friend) and immediately started to work on a master thesis about dentin-resin bonding of porcelain onlays. In the Division of Fixed Prosthodontics, I started to work on full-mouth rehabilitation cases.



Michel in his first laboratory, Oral Design Center Montreux (1992).

## Professional turning point – A new call

While my thesis was moving along very well under the direction of Didier, I was frustrated by my clinical works. Even though Dr Belser always insisted on working with highly qualified dental technicians, the PFM crowns and bridges we were getting did not look natural in the mouth. I was also shocked by some of the failures of sophisticated works performed by experienced and extremely talented clinicians (ie, ceramic and root fractures, etc). Something was missing. I started to question whether I could practice this profession for the rest of my life.

In those days, Michel was in-house technician for a dentist in the beautiful city of Montreux. In 1991, Prof Belser came to me and mentioned this very talented dental technician from Basel who was looking for a talented dentist to work on a series of anterior crown cases to present a new porcelain that he developed. His name was Claude Sieber, and the porcelain was Vitadur Alpha (for layering over aluminum oxide framework). Claude came to Geneva to meet us and we immediately started a series of approximately 10 cases. ***For the first time I could see firsthand the porcelain of a master inside the mouth of my own patients.*** Claude also inspired me with his photography. Of course I had seen pictures of the amazing cases of my brother but had not worked with him yet. Claude's work was stunning and I came to realize that I was working with one of the best ceramists on the planet.

But the real turning point happened a year later, in 1992, when Michel finally opened his own dental laboratory in Montreux—Oral Design Center Montreux, a name chosen at the insistence of Willi Geller himself. As we worked on our first case together—restoration of large fractures on maxillary central incisors (the patient displayed in Fig 7-1)—we were faced with a tough decision. Both teeth were vital, but there was not enough coronal structure left for the resistance and retention form of a crown. I remember sitting with Prof Belser and discussing our options. The patient had previous composite resin restorations that had worked well and only needed replacement because of discoloration. Bonding had been successful with composite resin restorations, and it could be successful again. Hence we decided to keep the same strategy but use porcelain instead of composite resin restorations. This first case was also our first two type III bonded porcelain restorations (see classification in Table 6-1). How could we dare bond 5 mm of freestanding porcelain on an incisal edge? Famous educators at that time were warning of the risks of placing more than 2 mm of porcelain on an incisal edge. In addition, I had never learned how to do porcelain veneers before. It was daring but it made complete sense. Prof Belser approved. Even though dentin was largely exposed on the incisal edges, we bonded those two veneers exclusively to the enamel. Those restorations are still in function as I am writing these lines, 29 years later.



t.me/Dr_Mouayyad_AlbtousH


THURSDAY 25th JUNE 1992

09.00 DR PASCAL MAGNE, M.D., D.M.D.,

"Esthetic Dentistry: Current Concepts and Clinical Trends"

Pascal Magne is a lecturer in the departments of Operative Dentistry and Endodontics, and Fixed Prosthodontics at the University of Geneva Dental School, Switzerland.

Until recently, specific esthetic materials and techniques hardly challenged conventional techniques. Nowadays, a major concern is progressively to eliminate metal from restorative materials. The respective developments and their clinical applications will be described.

14.00 DR THOMAS J. KEPIC, D.D.S., M.S.D.,

"Total Patient/Customer Service"

Thomas Kepic had a private practice in Upland, California specializing in periodontics.

In order to have a highly successful private practice, the clinician must possess more than the knowledge and clinical ability to deliver excellent contemporary dentistry. Time efficiency in internal marketing will enable the consultant and staff to motivate patients to complete needed dental procedures. Three patients will then refer new patients. One must deliver not only quality but also service. That service should be tailored to the living that the patient values most.

16.00 Coffee

Program of my first international lecture in Vilamoura (Portugal, 1992), where I met Dr Thomas Kepic from Los Angeles.

***The idea of bonding large nonretentive porcelain restorations was provocative, but it was a game changer, and I never looked back or questioned my professional choice.*** Michel and I kept working on cases and refining our technique, especially the previsualization of our goals through sophisticated mock-ups and provisional restorations. Michel had already developed this amazing bilaminar sandwich technique for acrylic provisional restorations, and he was also using a similar strategy for the porcelain buildups (dentin base, cutback, characterization, enamel skin, etc; see Fig 6-67). We started to be invited by local study clubs. It was work hard and play hard, skiing and playing tennis together during the weekends. Prof Belser understood the synergy between us brothers, and he was a fuel for my creativity. My master thesis with Didier Dietschi was going well and had revealed the limitations of dentin bonding when luting indirect restorations. The dentin-resin hybrid layer seemed crushed during the seating of the restoration, and we could not figure out a solution until 1995, when Dr Stefan Paul from the University of Zurich introduced us to the dual-bonding technique.

In 1992, I was invited for my first international lecture in Vilamoura, Portugal, for the American Dental Society of Europe. I presented the cases made with Claude Sieber as well as our first cases with Michel. I also met a periodontist who was on the same program page, Dr Thomas Kepic from Los Angeles. Little did I know that we would become friends for life and even neighbors 12 years later.

Two years later, Michel and I were invited to our first international congress together in Paris. David Garber and Frank Spear were in the room, and as a result we were invited for our first lecture on American soil in 1996 for the prestigious American Academy of Restorative Dentistry. I could handle lecturing in French or Italian back then, but our English was a disaster and we were terrified. We spent the whole night before the lecture reading and rereading our English script that I had written for us. Michel barely even read the script. But we had to go on. Urs Belser introduced our lecture. We struggled so much to speak, and I felt the audience was suffering with us. But their compassion and our didactic material and pictures saved us that day, and because of that lecture, we were going to be invited a lot more to this side of the pond.

## αΩ.3 TOUCHED BY GOD

A life-changing experience was going to happen in 1995. It started with my mother being diagnosed with cancer in 1994. She had decided to fight the disease as hard as she could. My parents had just retired after 25 years of intense and faithful service at the prison of Neuchâtel. It was bad; it was an advanced form of cancer, and it was clear she was not going to survive it. But she had decided to face the devastating effects of treatment in order to extend her time with us. I knew I would soon have to face for the first time the departure of a loved one. In an incredible turn of events, while she was going through a relatively good phase in December



t.me/Dr_Mouayyad_AlbtousH

1996, I was able to bring my parents with me to New York, where I was lecturing for the Greater New York Academy of Prosthodontics. They had never visited another continent before. What a treat it was to have them in the audience while I was giving my lecture to this prestigious group; they were so proud. Dr Vincent Celenza had invited me, and he was so thoughtful with my parents. We went to a Broadway musical, and we watched the city from the top of the Empire State Building. This was going to be her last trip.

## The church

My brother had experienced some big changes too. One of his three beautiful daughters, Julie, had been asking questions about Jesus, and his wife, wanting to provide the right answers, ended up joining a Bible study group. Catherine was changed by this process and started attending church, even prioritizing this above Michel himself. After being asked by Julie to join her and her mother at church, a once-suspicious Michel eventually joined the Bible study group too. He was going through a strong spiritual experience. While we were traveling together for our lectures, he would tell me about his God. He would also tell me about his brothers and sisters at church. One day he mentioned that his relationship with those brothers seemed to supersede our own relationship; this shocked and intrigued me. After all I was his true brother, or was there a new definition implied?

In December of 1994, I was spending the holiday with my brother's family, and they invited me to join their church for one of their weekly gatherings. I was fascinated by the simplicity of this assembly. I always thought churches were buildings. ***This day I realized that the church is people. The building was not important.*** This church was in fact a simple room located in an industrial area of the city. No statues, no decoration, no distractions. A blank room with just chairs and a pulpit. People started to pray freely. All of this was new to me. Anybody could pray and use his or her own voice at any time. The prayers were as beautiful and diverse as the people. Nobody was reading from a prayer book. It was all inspired. What an experience.

This day, instead of a message, a movie about the life of Corrie Ten Boom was presented called *The Hiding Place*. During WWII, the Ten Booms had saved numerous Jews by hiding them in a small secret room behind a false wall in Corrie's room; they were eventually caught and sent to prison and then to a concentration camp. But Corrie and Betsie, her sister, would hold secret worship services with a Bible that had been smuggled in. Her parents and two siblings died in the camp, and 1 week after being miraculously released due to a clerical error, Corrie learned that all the women in her age group were sent to the gas chamber. Of course this story is a touching one, but what struck me most was that this woman, after losing all she had, stated that God had given enough love for her to forgive her enemies, which she did in writing and in person for at least two guards who had survived. She had lost everything but her faith in God. At the end of the gathering I met with the pastor and he gave me two books: a Bible, of course, and another little French book called "De la parole aux actes" (translated "From words to deeds"). The book was asking simple questions: Is there a God? If yes, who is this God? Do you know him? Does he know you? All those questions were going to resonate in my head for the next 6 months.

## The investigative journey

My parents were moderate Catholics. I remember my mother praying to the various saints depending on our needs (ie, protection during travel, lost things, etc). As such, they had sent us through the regular sacraments of Roman Catholicism, infant baptism, confirmation, and first communion. I know I believed in the existence of God because I too would pray for my various needs. But I had no clue as to who he was and if he even knew me. I discovered I was agnostic (a person who believes that nothing is known or can be known of the existence or nature of God). But I soon decided that I could not remain in this



t.me/Dr_Mouayyad_AlbtousH

state of mind. My analytical thoughts were going to guide me on a journey of discovery of what I called "the spiritual marketplace."

Although my Catholic background was tied to Christianity, I wanted to investigate other faiths and beliefs, from Islam and Judaism to Buddhism, as well as expand my knowledge of Christianity beyond Catholicism. It was a fascinating journey of reading, consulting with friends from different cultures, and processing all the knowledge in the most logical way possible. I made amazing discoveries and continue to do so today. The most intriguing element was the presence and acknowledgment of the person of Jesus Christ all across those beliefs and scriptures. Muslims can read about the life of Jesus in the Quran. Isa (Jesus) is not only mentioned 25 times (Mohammad only 4 times) but is presented as a prophet, the greatest and ultimate prophet, spirit from God, and even word from God. The Quran even mentions other people from the Bible such as John the Baptist, Moses, and Abraham (Ibrahim). I also discovered obvious analogies between Jesus and Buddha, the main characteristics being about love (loving others, loving your enemies, turning the other cheek). Some Buddhists even perceive Buddha and Jesus as brothers. The Tanak (Hebrew Bible, Old Testament) is full of references about the Messiah. When reading the Isaiah Scroll, chapter 53, the description of Jesus Christ is striking and undisputable, even though it was written 700 years BC.

***It was fascinating to discover so many similarities between the main sacred texts. All my findings were pointing in the same direction—a man named Yeshua, Isa, or Jesus, which means "God saves."***

I was now ready to go back to my original questions. I always believed God existed, yes. God wanted to connect with me, yes. He did this by making himself a human being, Jesus Christ. This man had really existed, yes. He was definitively a wise man.and a prophet, yes. Now everything was making sense. While studying the words and acts of Jesus, there was nothing wrong I could find about him. He was a human being like myself, able to feel emotions and pains like myself. But he was pure, not like myself. God had provided a model for humanity. ***The Bible was going to become what it stands for (B-I-B-L-E): my Basic Instructions Before Leaving Earth. An encyclopedia for life.*** As I started a basic Bible study, with a newly found church in Geneva, I was able to discover and understand many stories that I did not even know about.

## One more thing... the ultimate element

One last element that I needed to understand was the death of Jesus and the principle of atonement (reconciliation of God and humankind through sacrificial death). Why would this human model have to die and be sacrificed so brutally, nailed to a pole of wood? Now I came to realize what my name, Pascal, really meant. Before Jesus, animal sacrifices were used to satisfy God for offenses committed against Him. In Leviticus 17:11, God said to Moses: "For the life of a creature is in the blood, and I have given it to you to make atonement for yourself on the altar; it is the blood that makes atonement for one's life." ***The same blood of a spotless lamb had been used by the Israelites during the first Passover (the Passover Lamb) in Egypt, to protect their firstborns from the tenth plague (death) and to allow them to be freed from slavery and walk out toward the promised land. It was the Paschal sacrifice.***

Throughout the Old Testament, God had promised to provide an ultimate lamb, as foretold in the story of Abraham and Isaac as well as in the book of Isaiah. Jesus's death bore the wrath of God, preserved the lives of all who trust Him, and gave freedom to the former slaves of sin.

What a discovery: the Old and New Testaments were telling the same story. The Old Covenant (laws of Moses) had not been fulfilled, and hence God provided a New Covenant; because of the ultimate Paschal lamb, Jesus Christ, no more animal sacrifices were going to be required. What great news! When the thick heavy veil separating man from the Holy of Holies in the temple was



t.me/Dr_Mouayyad_AlbtousH



*Paschal*. Ink and paper collage on photographic paper by Michel Magne.



t.me/Dr_Mouayyad_AlbtousH

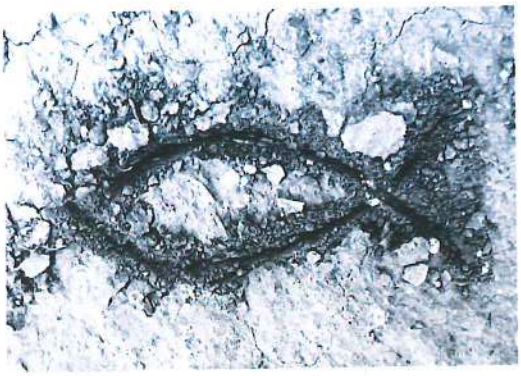

Symbol of the fish carved in the ground.




Baptism certificate.

torn, access to God was given to all, Jews and Gentiles. This was mind-blowing to me. But it was going to be only the tip of the iceberg of discoveries from the scriptures.

Jesus was the only person who had fulfilled all Old Testament messianic prophecies. Above all, Jesus was a model not only with his life but also through his death and resurrection. ***From the beginning, God did not need to rest, but he did rest on the seventh day and enjoyed his creation; so should we. Jesus did not need to be baptized, but he was baptized by John the Baptist; so should we. Jesus overcame temptation; so should we. Jesus died and resurrected; so will we: "He will revive us after two days, and on the third day he will raise us up so we can live in his presence." (Hosea 6:2, dated 760–720 BC).***

## Opening my heart to the truth

My investigation had been as inclusive and comprehensive as can be, and I had come to a conclusion. The Holy Bible (Old and New Covenants) was telling the truth. When an evangelist visiting from England made a call for people to accept Jesus as their Lord and Savior at my church in May of 1995, I opened my heart to Him that day. It was going to be the best decision of my life.

## The fish and a soulmate for life

Now that I had access to the infinite resource of love coming from above (by God the Father) and materialized below (by Jesus the Son), I knew my life was going to change. Above all, I had a new weapon—prayer—and this prayer was going to be answered rapidly. One of my students introduced me to this beautiful Peruvian woman, Geibi, who had been coming to the Dental School in Geneva as a patient. She had come from Peru at age 19 to learn French. She was 24 and I was 29. One of my best friends had married a Peruvian woman, and because we had regular weekend parties with mixed crowds of Swiss and South American people, I invited Geibi to come along in the summer of 1995. When she saw the fish sticker near my license plate, I thought I'd have to explain that the fish was *ichthus*, a Christian symbol representing Jesus Christ. But there was no need; I quickly learned that Geibi herself had accepted Christ 5 years before. It was like a thunderbolt. Our 45-minute ride to Lausanne was going to be very interesting. We did not socialize too much with the others that evening but instead shared about our respective spiritual journeys. She later became my wife and still is today, 25 years later. My love for her has not faded thanks to our common source of "agape" (unconditional love) coming from above. While life was not going to be easy every day like any other couple, we would have this shared model to look at for guidance in our relationship.



t.me/Dr_Mouayyad_AlbtousH

## Born of water and spirit

Before thinking about getting married, I wanted to get baptized again as a personal step of obedience to Christ and to publicly profess my faith. I was going to do it properly, so on November 19, 1995, I was born of water and the spirit by full immersion. ***Just as a physical mirror is used to see your physical image, the Bible was going to be my spiritual mirror to see my spiritual reflection.***

The years to follow were going to be blessed beyond my imagination. There was a fire in me to share my spiritual awakening. It felt as if I had just won the lottery and I wanted to share the winning number with everyone. But my faith would soon be tested.

# αΩ.4 THE MINNESOTA EXPERIENCE

## Reality check

Prof Urs Belser had been mentoring me all along. He had carefully nurtured my professional growth and had always guided me when I needed it. He was not a boss but a true leader and mentor, and I could see the pride in his eyes like that of a father for a son. One day in early 1996, when I was 30, he asked me about my career path and where I was heading. I had been thinking about it but he nailed an important question that I was going to have to answer sooner or later: Was my path going to be academic, mixed, or toward private practice? He made it very clear that if I was going to choose academia, I would have to step up my research profile significantly, and that meant getting a grant, finding an institution abroad, and going on a full-time research scholarship. My mother was still very sick and getting chemotherapy, I was still dating Geibi, and the prospect of leaving Switzerland was not a welcome one at that time.

In the summer of 1996, I decided to take advantage of an invitation to lecture for the first time at the American Academy of Esthetic Dentistry to visit a few American dental schools. One of them was the University of Minnesota, especially the Minnesota Dental Research Center for Biomaterials and Biomechanics (MDRCBB). Why Minneapolis? Well, I had read the paper by Morin, DeLong, and Douglas about "Cusp reinforcement by the acid-etch technique" (1984), and I was fascinated by the experimental approach using force displacement and strain gauge testing. They had also developed a unique chewing machine for fatigue testing. Finally, they had pioneered the use of numeric simulation using finite element analysis. During my visit, Dr William Douglas impressed me immediately with his kindness and openness about my projects. He has also noticed my little fish pin and said he liked it very much. He, too, was a man of faith. Upon explaining what my plan would be for my research at the MDRCBB, he simply replied, ***"What you are trying to achieve, Pascal, is called biomimetics."*** I was not going to dwell on the tissue engineering part of it but simply try to investigate the best materials and techniques available ***to mimic the perfect model given by God, the natural tooth with its beautiful enamel, dentin, and dentinoenamel junction***. Dr Douglas and I were exactly on the same wavelength, not only about dental research but also spiritually. What a match! God had just provided an additional mentor, a research mentor.

## A leap of faith, a prayer answered, and a wedding

The Minnesota visit was the first step in the process, and it had a positive outcome. Now equipped with two strong mentors, I submitted my project to the Swiss Science Foundation and it was accepted for a grant. It seemed that the



t.me/Dr_Mouayyad_AlbtousH



Wedding day in Pucallpa, Peru (March 1998).



Newlyweds back in Minnesota (1998).

doors were opening, but it was going to be a painful decision to leave for Minnesota given the precarious health of my mother. Getting on that plane in May of 1997 was a big leap of faith. It was overwhelming to leave behind my parents, my friends, and Geibi. I would communicate with my parents via fax and with Geibi via email through a third-party friend with a computer.

I had just started setting up my research project when my brother called me on June 25, 1997: "Pascal, come back as soon as you can, get on the next plane, Mom is not doing well." She had been hospitalized because her situation was worsening. I jumped on the first flight to Geneva. Michel picked me up at the airport and we drove to see my mom in Neuchâtel. She was in her room, peaceful, waiting for all of us to be present. We had a great time talking, and then we left her to have dinner. When we returned, she was in coma. She died the next day, June 28. The little wall calendar in her room had a Bible verse on it. ***The verse that day said: "In my distress I called to the Lord, and he answered me." (Psalm 120:1).*** As she took her last breath and went to the Lord, we were all praying around her bed. Geibi was there too. It became clear that my mother had been waiting for the family to be together. She had told me before that she was at peace with God and that I would have to be patient with my father. God had been so gracious. We had prayed for healing and God had answered by healing her spiritually.

Upon my return to Minnesota, I tried getting back to work. Geibi and I would keep communicating, and in September 1997 I decided to ask her hand officially and flew again to Switzerland for the occasion. In March of 1998, she made the trip from Switzerland to her hometown of Pucallpa, Peru, and I flew from Minneapolis to the Peruvian Amazon for the wedding. In anticipation, I had learned my fifth language, Spanish, via a CD-ROM English-to-Spanish in order to be able to ask properly my wife's hand to her father (her parents speak only Spanish). At first I had to deal with the thermal shock, from the freezing-cold Midwest to the super-hot and humid rainforest tropical weather. Our honeymoon was in Cusco, and of course we also visited Machu Picchu. It was refreshing. My sister and my father made the trip, too. What an amazing experience and discovery of the pre-Columbian culture. I had seen so many people with gold open crowns on their front teeth, which was somewhat appropriate given the overwhelming use of gold decoration in the Inca culture. Geibi and I returned to Minnesota to live together for the first time, at Hennepin Avenue in downtown Minneapolis.

## Biomimetic dentistry – The tooth as a model

My projects at the University of Minnesota were advancing very well thanks to the amazing help of Dr Maria Pintado, who was teaching me to



t.me/Dr_Mouayyad_AlbtousH



Working at the MDRCBB in Minneapolis (1998).

use the artificial mouth for load experiments, and Antheunis Versluis, who was teaching me finite element analysis. I was learning how to balance my life between work and my new responsibilities as a husband. God was so good to us. Another prayer was going to be answered. It was becoming obvious that we'd need to stay for another year for all my work to come to fruition. My first year had focused on studying the stresses and deformation in the anterior natural intact tooth, and I needed more time to look at restored anterior teeth. These two steps were essential in the biomimetic approach. ***After all, like Jesus, who is a model for humanity in life, natural teeth with their magnificent structure of dentin and enamel had become a model for restorative dentistry in the biomimetic approach.***

During my 2-year Minnesota experience, not only did I produce over 15 research articles, but I had learned that prioritization was key, placing God first (the first commandment), then my wife and my family, then maybe my work. I was going to learn that whenever I disrespected this important principle, I could not expect to be blessed. On the other hand, applying this principle would lead to countless blessings.

## αΩ.5 GENEVA TO LOS ANGELES

### Back to Geneva – A PD and a book... and a baby

With all my work completed in Minnesota, it was time to return to Geneva in the summer of 1999. We were so excited because my father had just found a companion to share their last chapter of life on earth. It was a blessing to both of them. I was back to my academic duties at the university and so excited to be back with my students and treating patients with my brother while working on two major projects: my second doctorate thesis (called PD, or Privat Docent, in Switzerland) and my first book. The thesis was going to be a collection of my publications, while the book was the "clinical version" of the PD. For several years, Mr HorstWolfgang Haase at Quintessence Publishing had been asking me about writing a book for them, and because all my scientific questions about bonded ceramic restorations had been answered in Minnesota, I felt I was ready. Those two projects were going to challenge my priorities, and God was going to teach me about it. Prof Belser had kept supporting me and guiding me along the process of the PD, and I successfully defended my thesis in 2001. The book followed immediately after in 2002.



With Prof Urs Belser working on the first edition of the book in Geneva (2001).



t.me/Dr_Mouayyad_AlbtousH



Erine in utero at 13 weeks (2003).

But the most amazing gift was going to be next. In February 2003, we learned that Geibi was pregnant. It was a Saturday, and Geibi was leaving to visit her parents in Peru. We decided to keep it secret until the 3-month mark. The day after Geibi had left, I went to church by myself, and after the service, an older woman of the church came up to me. I did not know her very well, but she said, "Pascal, I had a vision during prayer, and it was for you. The vision was a triangular shape that was transforming into a beautiful white flower. I don't know what it means, but you will." It was like being struck by lightning, because as she was speaking I could see the triangle as the female reproductive organ, the uterus, and the beautiful white flower as a baby girl. Sure enough, at 20 weeks of pregnancy we were told it was a girl. When exploring names, we were looking at names of white flowers; one was Nerine, and it inspired us to call our daughter Erine. She was born on October 19, 2003.

## Dr Hal Slavkin invitation

During the summer of 2002, I was contacted by Harold Slavkin, the Dean of the University of Southern California (USC) School of Dentistry at the time. He was looking for a faculty hire with a dual profile, as much interested in clinical dentistry as research. Above all, he wanted someone who would contribute to the teaching of esthetic and adhesive dentistry. He had heard about the Magne brothers from Dr Cherilyn Sheets, a member of the USC dental school's Board of Counselors, who had told Hal about the Magne brothers. Los Angeles had never been the place of my dreams, but Geibi and I decided to explore the possibility. Prof Belser insisted that we take the offer seriously. During my first visit, Dean Slavkin and I had fantastic discussions about biomimetics and the endeavors of the USC Center for Craniofacial Molecular Biology. The second visit was with my wife in January 2003, and the third was with my brother on our way to a lecture in San Francisco. Dr Slavkin gave us a very good idea of what life in California could look like. We were very much impressed by the Venice/Santa Monica area. The ocean and the beaches were not something easy to find in Switzerland.

## Big move, big challenges...

Geibi gave birth to Erine in Geneva, and 4 months later we packed all our belongings into a 12-foot container, and the three of us were on our way to Los Angeles for a new chapter of our lives. It was not going to be easy, especially for my wife who would find herself with an infant in temporary housing in Marina Del Rey, with no friends and no family to help. Again I was busy at the university setting up all my academic activities and did not see how difficult it was for Geibi at home. We found a nice place to live in Santa Monica where she was able to stroll around safely with baby Erine, but it took more than 3 years for us to overcome this very challenging move.

In early 2005, Michel and two other dental technicians from Europe decided to accept an offer by Dean Slavkin to join USC and build an in-house laboratory for the dental school. The project was daring and promising, and for the first time Michel and I were going to be able to work together under the same roof. Above all, the school would have a top-notch dental laboratory with highly skilled ceramists to increase the exposure of the dental technician's work. One of my struggles in the United States has always been that dental laboratories are considered a trade



t.me/Dr_Mouayyad_AlbtousH

partner rather than a health partner. Michel and I hope that we may have slightly contributed to alleviate this problem by establishing a high-level laboratory within the university where students can interact with skilled ceramists and see first-hand how dental technicians work. Even though it is taking a long time, it is encouraging to see that the best restorative dentists and prosthodontists now understand that their work is worth no more than that of their dental technician. This had been our message all along when lecturing together. ***We would often use the analogy that a skilled dentist with a poor ceramist is like a race-car equipped with the wheels of a basic sedan.***



Erine holding Santiago in Santa Monica (2010).

Geibi and I visited several communities before finding our place at Hope Church Santa Monica, where we have been worshiping for the last 10 years. Life is better when you have a family in Christ. In January 2010, Geibi was pregnant again, this time with a little boy. My father was so happy to finally have someone who could potentially carry his name through (my sister took the name of her husband and my brother had three daughters). Little did we know that summer 2010 was going to be a tough one.

I was on my way to a lecture in Europe in June, and I had stopped to visit my father in Neuchâtel. He had suffered minor strokes in relation to treatment of his cardiac arrhythmia, but there were no sequelae. A month later, he had a carotid blockage and was admitted at the hospital, and the next day he was in coma. Michel and I immediately flew back home and barely made it in time to say goodbye before he passed away. My father, Albin, was not able to meet my son, whom we decided to name Santiago Albin. I was confused about what just happened, a funeral again and then 2 months later, Santiago's birth. I had doubts about my father's faith; I had been challenged by many projects at work and my brain was overflowing with emotions. One day, my best friend in Switzerland sent me a message. He had been cleaning up his email inbox and had found a message that I had sent in June, just after I had visited my father. In this message I was telling my best friend how happy I was because during our discussions, my father had accepted the authority of the Bible as the word of God. He had previously denied it, but during that visit in June, 1 month before he died, he had told me otherwise. Somehow I had completely forgotten about this, and God answered my doubt through my friend.

We have adapted to life in Los Angeles, and we have been abundantly blessed. The multi-ethnic and multicultural nature of LA is impressive, and we thank God that we have been able to keep our children connected to their roots,



Family vacation in Ucayali, Peru, which is in the high Amazon rainforest where Geibi grew up (December 2013).



t.me/Dr_Mouayyad_AlbtousH




Family winter break in old town Neuchâtel (December 2017). On the left is the prison tower attached to the service apartment where Pascal grew up.

both Swiss and Peruvian. God has helped us to provide them with a balanced exposure to the reality of this society and the hope in God's promises. I remember one day when I got home, I was tired and discouraged by various challenges at work; I sat on the couch and my son asked me to play with him. I replied, "Sorry dear, I am sad." He looked at me and said, "But Daddy, you believe in Jesus, why are you worried?" I was in shock. My 6-year-old had just set me back on track, and I immediately stood up and went to play with him. What a lesson! God certainly speaks through little children.

If I could impart one thing to you in this book, it wouldn't be how to make a perfect restoration or how to emulate nature in dentistry. It would be to love people where they are and for who they are. ***The biggest challenge in life is to love people while not necessarily loving what they do, how they look, or how they act. This is the definition of unconditional love as modeled by Jesus Christ's love for us. Loving the unloving and unlovely is hard, but this is what we are called to do.***



t.me/Dr_Mouayyad_AlbtousH

# EPILOGUE

My most recent professional endeavor has been this book. It is nothing short of a miracle that I could complete this giant task. Mr William Hartman from Quintessence Chicago has been encouraging and supportive in ways that I cannot describe. Above all, his prayers have been heard and his team (Leah Huffman, Sue Robinson, and Sue Zubek) is to be praised for the outstanding work accomplished. As a conclusion, I want to share some fundamental thoughts that accompany me whenever I look at humanity, conflicts, and struggles, and try to place them in perspective:

1. *No matter how hard we try to be righteous, we are all imperfect and are all broken to some degree.* But when many broken pieces are brought together, they form a mosaic, a beautiful piece of art. The artist is God. Hence, ***a new definition for perfection on earth should be passion and love; it is what holds together all the broken pieces and produces true art.***
2. *God can always turn something apparently very bad into something very good.* In Genesis 37–50, we read that Joseph had 10 older brothers but his father loved him more than his other sons. The brothers were jealous of Joseph's favor and sold him into slavery. However, God later used Joseph to save his own brothers from starvation after Joseph became a trusted ruler in Egypt. Later, Joseph told his brothers, ***"You intended to harm me, but God intended it for good" (Genesis 50:20).***
3. *God does not look on appearance but on the heart.* In this we need to learn from the story of King David. When the first King of Israel, Saul, was disobedient, God prompted prophet Samuel to go to Bethlehem to choose one of Jesse's seven sons as the new anointed king. One after the other, each son was presented as a potential candidate. They were handsome, but the Lord says this: "Do not look on his appearance or on the height of his stature, because I have rejected him; ***for the Lord does not see as mortals see; they look on the outward appearance, but the Lord looks on the heart." (1 Samuel 16:6–7).*
This sounds very much like us. So easy to judge by physical sight! One son, the youngest, was not presented to Samuel because he was unlikely to be chosen; he was not deemed important enough, not impressive by the sight. But God chose the youngest son because of his spiritual sight: Young David was chosen and anointed as the new king at age 16. He would have to wait another 14 years to become the king, and during these 14 years, he was going to be tested and prepared for this task. His loyalty would prove unparalleled, and he would stand as Israel's greatest King. Jesus would eventually be born from the lineage of David.
4. *There is always hope.* Our lives are not limited to life on Earth. We tend to look at things as finite, but God is infinite. This life is only a snapshot of "The Whole Story." Like what a single frame is to a movie. Many people believe that we can die. But this is a lie. ***Our soul lives eternally, and there is nothing to lose in accepting this as the truth. There is a lot to lose in not believing it. Once exposed to the truth, we are all given a choice about how to spend eternity.***


t.me/Dr_Mouayyad_AlbtousH



God is speaking to you as follows:

***But if from there you seek the Lord your God, you will find him if you seek him with all your heart and with all your soul. —Deuteronomy 4:29***

***Here I am. I stand at the door and knock. If anyone hears my voice and opens the door, I will come in and eat with that person, and they with me. —Revelation 3:20***

I pray that "The Whole Story"—not mine, but that of the mosaic of God as well as His Word—will inspire you and elevate you to new spiritual heights.

Always,

Special thanks to Pastor Barry Crocker (Hope United LA, Santa Monica, California), Dr Daniel Romo (Whittier, California), and Leah Huffman (Quintessence Chicago) for reviewing the draft of this biography.



t.me/Dr_Mouayyad_AlbtousH

The sculptures displayed alongside each chapter of this book were created by Swiss artist Anita Gehler (Geneva). The intention was not only to establish a relationship between sculpture and esthetic dentistry but also to refresh the reader's eye and appeal to the senses through art. In the five sculptures presented in chapters 1 to 7, the form, texture, and nature of the materials used by the artist convey a harmony between body and spirit.



Chapter 1: Le Secret (The Secret).
Rear view of 40-cm-high cement sculpture.



Chapter 2: Le Silence (The Silence).
Frontal view of 8-cm-high bronze head.



Chapter 3: Sans Titre (No Title).
Cement sculpture 33 cm high.



Chapter 4: La Vie Est Belle (Life Is Beautiful).
Cement sculpture 43 cm high.



Chapter 5: Le Secret.
Frontal view.



Chapter 6: L'envol (Flight).
Cement sculpture 40 cm high.



Chapter 7: Le Silence.
Lateral view.



t.me/Dr_Mouayyad_AlbtousH

t.me/Dr_Mouayyad_AlbtousH

# INDEX

Page numbers followed by "t" denote tables; those followed by "f" denote figures; and those followed by "b" denote boxes.

## A


Abrasion
  airborne-particle, 280, 281f
  megabrasion, 252, 253f
  microabrasion, 250, 254
  wear versus, 34
Abutments
  anterior indirect bonded porcelain restoration application to, 594–597, 594f–597f
  description of, 60
  porcelain-fused-to-metal, 594
Acid-etch technique, cusp reinforcement with, 48, 48f–52
Acidulated phosphate fluoride, 774
Acrylic maxillary nightguard, 776, 777f
Acrylic mock-up, 448
Additive approach, 314
Additive color model, 120
Additive luting, 422, 422f–423f, 756, 756f
Additive principle, 319, 319f–321f
Additive wax-up
  analog, 468–477, 469f–477f, 474t, 476t
  diagnostic uses of, 448
  digital, 464, 464f–467f
  essentials for, 462, 462f–463f
  fabrication of, 462
  materials of, 468, 469f
  trimming of, 462
Adhesive luting, 759f
Adhesive restorations
  airborne-particle abrasion for, 280, 281f
  biomimetic nature of, 447
  isolation techniques for, 278, 279f
  placement of, 278
  tooth's circle of death treated with, 46, 47f
Adhesive systems, 40
Adhesive tooth preparation, 396
Adhesives
  dentin, 286–292
  enamel, 284–286
Aging
  of anterior teeth, 28–33, 29f–33f
  biocorrosion and, 84
  of enamel, 30, 30f
  of posterior teeth, 34, 34f–35f
  of smile, 30
Airborne-particle abrasion, 280, 281f, 682
Air-scaler handpiece, 282
Alloy restorations, 42
Alveolar model, 696, 698f, 701f
Alveolar mucosa, 72, 73f
Amalgam
  banning of, 42
  in pediatric populations, 44
  tooth fracture under, 46, 48
  tooth-colored materials versus, 42
Amalgam restorations, 385f
  composite resin restorations versus, 42t
  damage to, 282f
  illustration of, 43f
  lingual, 240
Ameloblasts, 144
Amorphous calcium phosphate, 246
Analog wax-up, 468–477, 469f–477f, 474t, 476t
Anatomical build-up technique, 328
Antagonistic enamel, 528
Anterior CAD/CAM restorations
  bilaminar, 426
  digital/analog workflow for, 426, 427f
  incisoproximal cutback, 430f–432f
  polymer vs. ceramic, 424, 425f
  step-by-step process for, 426, 427f–429f
Anterior guidance, 582, 749f
Anterior implants, 54, 55f–57f
Anterior indirect bonded porcelain restorations
  biologic considerations for, 612–615
  ceramics. *See* Ceramics.
  chipping of, 782, 783f
  Class 3 restoration
    replacement of, 796, 797f
    tooth preparation, 652, 653f
  complications of, 776
  cracking of, 790, 790f–795f
  evolution of, 566, 569f
  fabrication technique, 684–689, 685f–689f
  follow-up of, 770, 771f
  history of, 566
  indications for
    classification of, 566, 567b
    combined, 606, 606f–607f
    congenital and acquired malformations, 602, 602f–605f
    conoid teeth, 574, 574f–575f
    coronal fractures, 590–592, 591f
    crown fractures, 588f–589f
    diastemata closure, 576
    enamel loss, 598–601, 598f–601f
    extensive restorations, 588–605, 589f–605f
    generalized enamel dysplasia, 602, 602f–605f
    implant abutments, 594–597, 594f–597f
    incisal length and prominence augmentation, 582–586
    interdental black triangles, 576, 578
    lack of response to external or internal bleaching, 572, 573f
    morphologic modifications, 574, 574f–587f
    tetracycline discolorations, 570, 570f–571f
    type I, 566, 567b, 568f, 570, 570f–571f
    type II, 566, 567b, 568f, 574–587, 574f–587f
    type III, 566, 567b, 568f, 588–605, 588f–605f, 620f–621f
    type IV, 566, 567b, 569f, 608–611, 609f–611f
    type V, 566, 567b, 569f, 608–611, 609f–611f
  laboratory procedures
    ceramics, 682–684
    impressions, 682
  maintenance of, 770, 778
  masking effects, 722f–723f, 722–724
  maximum performance, 770
  occlusal veneers, 616–619, 617f–619f
  overview of, 565
  polishing of, 714, 774
  postbonding crack infiltration, 790, 790f–795f
  professional hygiene of, 772–775, 773f–775f
  provisional restorations
    cementing of, 678, 679f
    fabrication of, 672–676, 673f–677f
    glazing of, 676
    one-step, double-mix technique for, 672
    one-step, single-mix technique for, 672, 674f–675f
    shrink-fit locking of, 678, 678f
    spot-bonding of, 680, 680f–681f
    two-step, double-mix technique for, 676, 676f–677f
  veneers, 674f, 676f–678f




t.me/Dr_Mouayyad_AlbtousH

repairs
armamentarium for, 776, 778
chipping, 782, 783f
fractures, 784–789, 785f–789f
long-term results of, 788f
maintenance by, 778, 779f–781f
resurfacing of, 778, 779f–781f
shape effects, 718, 718f–722f
survival rate for, 770
tooth function restored with, 582f–583f, 584
tooth preparation
axial reduction, 628–630, 629f–632f
cervical margins, 636
Class 4 preexisting composites, 652, 653f
Class 3 preexisting restoration, 652, 653f
depth cuts, 628
diastema closure, 656, 656f–657f
dry finishing, 632–635, 633f
elements of, 634f
general considerations for, 620
immediate dentin sealing, 634, 658, 659f–663f
interdental margins, 636
mock-up–driven, 639f–643f
moderate approach, 624–626, 625f
"no-prep" to "over-prep," 622–624
overlapping, 644–650
preparatory stage, 626, 627f
recommended procedure for, 626–650
thin versus thick teeth, 650, 651f
wet reduction, 628–632
wraparound, 652–654, 653f, 655f
wrapping, 644–650
umbrella effect, 614, 614f–615f
Anterior mock-ups, 520
Anterior teeth. *See also* Canines; Incisors; *specific teeth.*
aging of, 28–33, 29f–33f
anatomy of, 7f
biocorrosion of, 598f–599f
characteristics of, 98, 98f–99f
dimensions of, 78, 79f
direct restorations in
composite resins for, 308, 308f
description of, 308
freehand placement method for. *See* Freehand placement.
guided placement technique for, 330, 331f–335f
surface texture, 336–339, 336f–339f
drawing of, 184–201
embryology of, 144, 145f
formation of, 144, 145f
function of, 8, 10f–18f, 10–18
load distribution on, 10, 11f
mechanics, 10f–18f, 10–18
numeric modeling of, 11f
posterior teeth and, 146, 146f
rationalized shape of, 6, 6f–7f
shapes of, 387
single-tooth implants, 58
wear of, 28–33, 29f–33f
Asian teeth, 80, 82
Attached gingiva, 72, 73f
Autodesk Meshmixer, 464f–467f
Automatic focusing, 544
Autonomous veneers, 691, 702, 731

## B

Bell stage, 23f, 144
Benzalkonium chloride, 292
Bilaminar assembly, 58
Bilaminar CAD/CAM polymer restorations, 426
Bilaminar shade guides, 330
Bio-base, 398, 399f, 406, 407f
Biocorrosion
bonded porcelain restorations for, 658f–661
causes of, 84
Class III occlusion with, 531f, 536f–541f
description of, 84
enamel, 598f–599f
illustration of, 525f
localized versus generalized, 514, 515f
sequential diagnostic approach to, 518–528, 519f–528f
wear caused by, 514, 617f
Biogeneric Copy module, 412, 413f, 426, 427f, 433f
Biologic width, 54, 72
Biologically oriented preparation technique, 526f
"Biomechanisms," 26, 26f
Biomimetics
CAD/CAM restoration, 412f–413f
essence/principle of, 572
magnification instruments, 305–307, 306f–307f
in mechanics, 36–51
Bis-GMA, 294
Bisphenol A, 294
Black triangles, interdental
closure of, 576, 578, 656, 658
description of, 54, 55f–56f
Bleaching
description of, 456
enamel adhesion strengths affected by, 248
external, 234
freehand Class 4 restoration after, 324f
in-office, 236, 238
microabrasion with, 250
nightguard vital. *See* Nightguard vital bleaching.
over-the-counter, 238
vital. *See* Vital bleaching.
whitening versus, 234
Bonded porcelain restorations
advantages of, 612
anterior indirect. *See* Anterior indirect bonded porcelain restorations.
biocorrosion treated with, 658f–661
biologic considerations for, 612–615
digital try-in, 561f
endocrown, 565
evolution of, 566, 569f
indirect, 565
periodontal soft tissue around, 613f
with traditional full coverage, 508, 509f
BOPT. *See* Biologically oriented preparation technique.
Brain dominance, 134, 136, 137f
Brain duality, 136
Brightness
description of, 116, 117f
tooth dimensions affected by, 82, 82f
Bulk-fills, 298

## C

CAD/CAM restorations
adhesive tooth preparation, 396
anterior
bilaminar, 426
digital/analog workflow for, 426, 427f
incisoproximal cutback, 430f–432f
polymer vs. ceramic, 424, 425f
step-by-step process for, 426, 427f–429f
chairside. *See* Chairside CAD/CAM systems.
composite resin, 300, 527f
composite resin inlay, 354
composite resin inlays/onlays, 394–399
cuspal coverage, 396, 398, 399f
description of, 58, 59f, 142
endocrowns, 414, 415f
history of, 386
morphology considerations for, 438
natural, 412, 412f–413f
occlusal veneers, 520
resin-based materials for, 424
Calcium carbonate, 712
Calcium hydroxide, 264
Camphorquinone/amine initiator system, 301
Canines
axis of, 74, 75f
central lobe of, 96f–97f

t.me/Dr_Mouayyad_AlbtousH

characteristics of, 94–97, 94f–97f
compressive forces on, 16
crown width/length ratios for, 81f
facial surface of, 16
mandibular, 98, 98f–99f
maxillary, 94–97, 94f–97f
mesial outline of, 96
morphology of, 6
palatal surface of, 7f
Carbamide peroxide, 234
amorphous calcium phosphate and, 246
chemical composition of, 237f
description of, 236
hydrogen peroxide versus, 240
in nightguard vital bleaching, 236, 237f, 238
walking bleach technique use of, 262
Carbide burs, 286
Carbopol, 240
Caries removal endpoints, 342, 344, 345f
Catalase, 264
CEJ. *See* Cementoenamel junction.
Cementation, of provisional restorations, 678, 679f
Cementoenamel junction, 18f, 54
Central incisors. *See also* Incisors.
axis of, 74, 75f
facial aspects of, 85f
features of, 84–93, 84f–93f
implant for, 55f
labial architecture of, 88f
labial lobes of, 90, 90f
lateral incisors versus, 94
maxillary
development of, 144
form of, 84–93, 84f–93f
guided technique for restoration of, 336f
illustration of, 12, 13f
permanent, 144
single-retainer cantilevered resin-bonded fixed dental prosthesis for, 62f
miniwings for inverted taper of, 664f–665f
outline of, 85f
prominence of, 586, 587f
provisional, spot-bonding of, 680, 680f–681f
wear of, 92f–93f
Centric relation, 516, 536
CER. *See* Luting ceramics.
Ceramic fragments, 308
Ceramics
adhesive resin application, 742, 743f
chemical coupling of, 738–742, 739f–740f
composite resin interactions with, 725–729
composite resins and, 38
dentin buildup, 706
description of, 682–684
etching of, 736f–737f, 736–738
final adjustments of, 748
firing schedule for, 714t
firing shrinkage of, 726–728, 727f
glazing of, 712, 713f
hydrofluoric acid etching of, 736f–737f, 736–738
insertion of, 744–748
layering and finishing of, 702–717, 703f–717f
luting composite resin application, 742, 743f
machined, 686, 686f–689f
mechanical polishing of, 714
micromechanical interlocking of, 736f–737f, 736–738
occlusal control, 748
prebonding cracks, 758, 758f–759f
pressed, 686
silanization, 738–742, 739f–740f
surface conditioning, 736–743, 736f–743f
surface finishing of, 712, 713f
tooth surface conditioning, 744
try-in, 732–734, 733f
veneers, 690–691
wear of, 34
CER/CPR ratio, 725–726, 727f
CEREC, 386
Cervical area, nightguard vital bleaching in, 246, 247f
Cervical discoloration, 636
Cervical embrasures, 576
Cervical margins
configuration and localization of, 636
relocation of, 358
C-factor, 304
Chairside CAD/CAM systems
aspects of, 386–393
choice of, 386–393
digital workflows, 387
history of, 386
Chemical treatments, 234, 235f
Children
bonded porcelain restorations in, 272
nightguard vital bleaching in, 242
tooth-colored materials in, 42, 44
Chipping, 782, 783f
Chlorhexidine, 41, 292
Chroma, 116, 117f
Chromatic adaptation, 118, 119f
Cingula crests, 16
Cingulum, 6
Circle of death, 46, 46f–47f
Class 1 gingival height, 76
Class 2 gingival height, 76
Class III occlusion, 528–536, 529f–541f
Closed sandwich restorations, 353, 354f–355f
CMKY model, 120
Collagen, 22f
Color
additive models, 120
components of, 116, 116f–117f
hue, 116, 117f
subtractive models, 120
value, 116, 117f
Color vision deficiency, 120
Commissural line, 128, 129f
Compliance, optimal, 4, 4f–5f
CompoSculp, 284
Composite resin(s)
advantages and disadvantages of, 567t
bulk-fills, 298
for CAD/CAM blocks, 300
ceramics and, 38, 725–729
characteristics of, 567t
components of, 296f
crown stiffness improvements with, 34
deep margin elevation, 363, 367
dentin bonding of, 40
dentin restoration uses of, 38
direct, 456, 457f–459f, 530, 535f
enamel bonding of, 40
endocrowns, 436
fatigue survival of, 392f
fiber-reinforced, 298–299
flowable, 299, 622
freehand placement of, 312, 313f
glass-ionomer cements and, 295f, 353
history of, 294–295, 297t
hybrid, 295
inhomogeneous microfilled, 295, 298
instruments for placement of, 284
for laboratory, 300
light-curing, 730
luting, 299–300, 419, 690, 730–731, 731f, 742, 743f, 784
macrofilled, 295
microhybrid, 298, 730–731
multihue, 328
nanofilled, 295, 298
nightguard vital bleaching and, 248
opacity of, 322f
packability of, 346
physical properties of, 34
pigments in, 120
polymerization of, 419
polymerization shrinkage, 408
shade grade for, 120, 121f
shrinkage of, 303
single-hue, 328–330, 329f
thermal expansion of, 38
timeline of, 297t
wear of, 34, 393f
Composite resin blocks, 388, 394t
Composite resin inlays
CAD/CAM systems, 354
conditioning of, 420f
luting of, 420f



t.me/Dr_Mouayyad_AlbtousH

Composite resin inlays/onlays, 394–399
ComposiTight system, 346, 347f
Compressive strength, 12
Connective tissue graft, 454f
Conoid teeth, 574, 574f–575f
Contact lens effect, 622
Contact lens veneers, 690f, 690–691
Contact wear, 34, 35f
Contact-free wear, 34, 35f
Contacts, 176, 177f
Copy-only situation, 52
Coronal fractures, 590–592, 591f, 644
Coronal volume subtraction/displacement, 489–495, 489f–495f
CP. *See* Carbamide peroxide.
CPR. *See* Luting composite.
Crack(s)
  anterior indirect bonded porcelain restorations, 790, 790f–795f
  enamel, 20–27, 24f–25f, 29f, 37f
  postbonding, 790, 790f–795f
Cracked tooth syndrome, 36, 43f, 396, 398, 616
CREs. *See* Caries removal endpoints.
Cross-polarization, 107f, 550, 554, 632
Crown deformation, cusp resistance to, 48, 48f
Crown flexure, 10
Crown fractures, 588f–589f, 646, 650
Crown rigidity, 34
Crown stiffness, 34
Crown width/length ratios, 80, 81f, 82, 83f
Cusp(s)
  acid-etch technique for reinforcement of, 48, 48f–52
  deformation of, 48, 48f
  fracturing of, 44f
  load deformation and, 18
  molars, deformation of, 51t
  posterior teeth, 146, 147f
  premolar, deformation of, 50f, 51t
  weakened, fatigue failure of, 46, 47f
Cuspal coverage, 396, 398, 399f
Cusp/fossa idealization, 176
Cutback dentin, 706, 707f, 711f
CVD. *See* Color vision deficiency.


## D


Dahl principle, 176, 515f, 516, 536, 646
Declination angle, 305–306, 306f
Deep bite, 514–518
Deep margin elevation
  biologic considerations for, 367
  composite resins for, 363, 367
  description of, 358–359
  in endodontically treated teeth, 359
  fundamentals of, 359–366
  illustration of, 359f
  immediate dentin sealing technique and, 359, 409
  matrix-in-a-matrix technique with, 364, 365f–366f
  modified supercurved circumferential matrix, 359
  radiographic control after, 358f
  subgingival margins, 387
  survival rates for, 367
Deflection cords, gingival, 666–668, 667f, 774f
DEJ. *See* Dentinoenamel junction.
Dental lamina, 144
Dental loupes, 305
Dentin
  anatomy of, 4, 4f–5f, 104, 105f
  architecture of, 105f
  buildup of, 706, 707f
  characteristics of, 28, 30
  characterization of, 708
  cutback, 706, 707f, 711f
  enamel and, interrelationship between, 28, 29f
  etched, 286, 287f
  exposure of, 28, 28f
  fluorescence of, 104, 108, 108f
  gingival margins in, 660, 661f
  layering of, 706, 707f
  opacity of, 322
  outer carious, 344
  physical properties of, 38t
  resin bonding to, 40, 416
  semipermeability of, 234
Dentin adhesives, 286–292
Dentin bonding
  chemical agents for, 288
  degradation of, 292
  delayed loading, 404
  etch-and-rinse systems, 291f, 292
  goal of, 286
  steps of, 289f
  systems for, 40, 287t, 291f
  wet, 404
Dentin bonding agents, 290, 658, 660
Dentin infiltrations, 104, 105f
Dentin lesions, 519f
Dentin mamelons, 104, 105f, 708
Dentin-bonded crowns, 566, 608, 609f
Dentin-bonded jacket crowns, 608, 609f
Dentinoenamel junction
  architecture of, 20f, 23f
  cracks and, 683
  description of, 8, 18, 20, 286, 730
  in enamel stress distribution, 24
  formation of, 20f, 22, 22f, 144
  mimicking of, 40
  physical properties of, 38t
  scalloping of, 20, 20f–21f
  surface morphology of, 20f
Deprogramming, 516, 518
Depth of wear, 34
Developmental defects
  classification of, 250
  hypomineralization, 250
  hypoplasia, 250
  resin infiltration of, 254, 255f–257f
Developmental grooves, 146, 147f
DIAGNOdent, 346
Diagnostic mock-up
  additive mock-up, 486t–487t
  bonded porcelain with traditional full coverage, 508, 509f
  coronal volume subtraction/displacement, 489–495, 489f–495f
  description of, 478
  dual-additive wax-up/mock-up, 498–507, 498f–507f
  indirect mock-up, 495, 495f–497f
  lip remodeling by, 480
  orthodontic therapy, 510–513, 510f–513f
  powder mixes for, 488t
  step-by-step process of, 480–485
  subtractive wax-up, 492f–494f
  tooth preparations, 480
Diagnostic wax-up
  additive wax-up. *See* Additive wax-up.
  step-by-step process, 460–477
Diastema/diastemata
  closure of
    anterior indirect bonded porcelain restorations for, 576, 656
    composite resin additions for, 308f
    freehand placement for, 312
    illustration of, 721f
    tooth preparation for, 656, 656f–657f
  description of, 52
Digital dental photography
  DSLR/MILC cameras, 542–544, 543f
  flash system, 546, 546f–547f
  lens, 544, 544f–545f
Digital impressions, 666f
Digital single lens cameras/mirrorless interchangeable lens cameras. *See* DSLR/MILC cameras.
Digital wax-up, 464, 464f–467f
Direct composite resins, 456, 457f–459f, 530, 535f
Direct intraoral inlay, 382, 383f
Direct pulp capping, 408, 409f
Direct restorations, 424
Direct-indirect technique, 382
Discoloration
  bleaching of, 234, 235f
  fluorosis stains. *See* Fluorosis stains.
  selective intrinsic masking of, 722f–723f
  translucency versus, 244f


t.me/Dr_Mouayyad_AlbtousH

Distoincisal angle, 84, 85f, 124
Ditramax, 128, 130f
DME. *See* Deep margin elevation.
Dominance, 132
Drawing
exercises for, 178
step-by-step instructions for, 179
DSLR/MILC cameras, 542–544, 543f
Dual-additive wax-up/mock-up, 498–507, 498f–507f
Dual-cure composite resins, 730
Dual-polymerization, 301
DX, 542–544
Dynamic smile balance, 138–140

## E

"Edge loss," 552
eLAB system, 550, 552, 553f, 555f, 556
Elastic modulus, 36
Electric handpieces, 280, 281f
e.max CAD glass-ceramic veneers, 687f
Embrasures
cervical, 576
incisal, 125f
Enamel
age-related wear of, 30, 30f, 461f
antagonistic, 528
biocorrosion of, 598f–599f
characteristics of, 28, 30, 710, 711f
"clouds" in, 106, 106f
collagen tufts in, 22f
cracking of, 20–27, 24f–25f, 29f, 37f, 682
dentin and, interrelationship between, 28, 29f
etched, 284, 285f, 286
generalized dysplasia of, 602, 602f–605f
histology of, 23f
incisal wall of, 708
loss of, 32f, 598–601, 598f–601f
mineral deposits in, 102f
opacity of, 322
palatal, 32
physical properties of, 38t
refractive index of, 250
resin bonding to, 40, 416
semipermeability of, 234
staining of, 711f
stress distribution in, 16, 16f–17f, 24, 32
thickness of
age-related changes in, 30
in anterior versus posterior teeth, 28
restitution of, 32, 33f
stress distribution affected by, 16, 16f–17f
thinning of, 32, 32f
white defects of, 250, 252t
Enamel adhesives, 284–286
Enamel effects, 106, 106f
Enamel increments, 351f
Enamel margins, 340
Enamel prisms, 21f, 284, 648
Enamel skin, 709f, 710, 711f
Enamel tufts, 21f–22f
Enamic, 390
Endocrowns
bonded porcelain restorations, 565
CAD/CAM, 414, 415f, 436
endodontically treated incisors, 610
incisor, 436, 436f
Endodontically treated incisors, 608, 610
Endodontically treated teeth
biomechanics of, 258
coronal leakage, 410f
cuspal stiffness of, 422
deep margin elevation in, 359
glass-ionomer cement placement with, 398
immediate dentin sealing for, 400, 401f–403f, 410f
sealing of, 409, 410f
tooth fragment reattachment on, 274
Endodontics, microguided, 258, 259f
Erosive tooth wear, 598
Esthetic dentistry, 67
Esthetic treatment planning
bleaching, 456
elements of, 454
mucogingival surgery, 454, 454f–455f
overview of, 447
patient management in, 450, 451f
Esthetic width, 614, 614f
Esthetics
balanced composition, 70f–71f
checklist for, 69f, 132
fundamental criteria for
gingival balance, 76, 77f
gingival health, 72, 73f
interdental closure, 72, 73f
interdental contact, 76, 77f
overview of, 68–70
tooth axis, 74, 75f
tooth dimensions, 76, 78, 79f
zenith of the gingival seam, 74, 75f
gingival, 68
subjective, 70
Etch-and-rinse systems, 291f, 292
Etched dentin, 286, 287f
Etched enamel, 284, 285f, 286
ETI. *See* Endodontically treated incisors.
ETW. *See* Erosive tooth wear.
everX Flow, 354
everX Posterior, 298–299, 299f, 354
Extraoral inlay, 384, 384f–385f
Eye dominance, 138

## F

Facial analysis, 138, 139f
Facial analyzer, 130f
Facial surface, of incisors, 6
Feldspathic porcelain
crown rigidity and, 34
resin bonding to, 416
tensile strength of, 38
wear properties of, 38
FEM. *See* Finite element method.
FenderWedge, 282
Ferrule, 610
Ferrule effect, 414, 566
Fiberoptic transillumination, 342, 343f
Fiber-reinforced composite resins, 298–299
Finite element method, 10, 11f
Fixed dental prostheses, resin-bonded, 58, 60, 60f–62f
Flash system, 546, 546f–547f
Flexibility, 4
Flowable composite resins, 299
Flowable liners, 346, 348, 349f
Fluorescence
description of, 104, 107f, 108, 110
laser, 346, 347f
Fluorescent stains, 708
Fluoridation, 774
Fluorosis stains
description of, 236
microabrasion for, 250
treatment of, 252t
white, 248, 249f
FOTI. *See* Fiberoptic transillumination.
Fracture(s)
anterior indirect bonded porcelain restorations, 784–789, 785f–789f
coronal, 590–592, 591f, 644
crown, 588f–589f, 646, 650
incisors, 272, 590f–591f
porcelain onlay, 786, 787f
Free gingiva, 72, 73f
Freehand placement
Class 4 restoration, 314, 315f
composite resins, 312, 313f
description of, 312
incisal effects, 322, 322f–325f
"sandwich" layering, 326, 326f–327f
three-increment technique, 314, 314f–318f, 320f
universal additive principle, 319, 319f–321f
Front lens mounted telescopes, 306
Full veneer jacket crowns, 727f
Full-mouth rehabilitation, 525f
FX, 542–544

## G

Generalized enamel dysplasia, 602, 602f–605f
Gestalt, 134, 135f




t.me/Dr_Mouayyad_AlbtousH

GIC. *See* Glass-ionomer cements.
Gingiva
  attached, 72, 73f
  balance of, 76, 77f
  carbamide peroxide effects on, 238
  Class 1 height, 76
  Class 2 height, 76
  contouring of, 636
  esthetics of, 68
  free, 72, 73f
  health of, 72, 73f
Gingival deflection, 666–668, 667f
Gingival dentin margins, 660, 661f
Gingival seam, zenith of the, 74, 75f
Gingival zenith, 74, 75f
Glass-ionomer cements
  automix, 293f
  chemical structure of, 293f
  clinical uses of, 294
  composite resins and, 295f, 353
  as dentin replacement, 586
  disadvantages of, 294
  fluoride release from, 292
  history of, 292
  pediatric dentistry uses of, 44
  resin-modified
    clinical uses of, 294
    development of, 294
    pediatric dentistry uses of, 44
  setting of, 293f, 294
  viscosity of, 353
Glazing, 676
Gloss, 112
Glycerin, 240
Glycerophosphate dimethacrylate, 286
Gly-Oxide, 236
Gold inlays
  fractured cusp under, 44f
  replacement of, 44f
Gold onlays, 44f
"Golden percentage," 76, 78, 79f
"Golden proportion," 76, 78, 79f
"Golden rule," 78
GPDM. *See* Glycerophosphate dimethacrylate.
Guided placement technique, 330, 331f–335f
"Gull" shape, of incisal edges, 122, 122f

## H

Half-torpedo, 282, 283f
Herculite XRV, 312
High-magnification prismatic telescopes, 305, 306f
High-performance polymer material, 58
Horizontal layering technique, 348
Horizontal segmentation, 718
Hue, 116, 117f
Hybrid composite resins, 295
Hybrid layer, 288
Hydrofluoric acid, 736f–737f, 736–738, 796
Hydrogen peroxide
  carbamide peroxide versus, 240
  description of, 236, 238
Hygroscopic expansion, 304
Hypersensitivity, 246
Hypomineralization, 250
Hypoplasia, 250

## I

IDS. *See* Immediate dentin sealing.
Immediate dentin sealing
  bio-base, 398, 399f
  deep margin elevation and, 359, 409
  description of, 292, 382, 620
  endodontically treated teeth, 400, 401f–403f, 410f
  fundamental steps for, 400, 401f–403f, 402t
  reasons for, 404–411, 405f–410f, 411t
  in tooth preparation, 634, 658, 659f–663f
Immediate pre-endodontic dentin sealing, 409
Implant(s)
  alternatives to, 58, 60, 61f–62f
  biomechanical improvements in, 58
  biomimetic effect of, 54
  central incisor, 55f
  functional changes for, 58
  lateral incisors, 56f–57f
  natural teeth versus, 54
Implant-supported restorations
  bilaminar adhesive designs for, 58, 59f
  in fixed prosthodontics, 54
Impressions
  digital, 666f, 682
  gingival deflection for, 666–668, 667f
  one-step, double-mix technique for, 666, 668, 668f–671f
Incisal edges
  configuration of, 122, 122f–125f
  contour of, 122, 122f–123f
  fractured, 706
  "gull" shape, 122, 122f
  interincisal angles, 124, 124f
  lower lip and, 126
  nightguard vital bleaching of, 240
  rounded, 122
  thickness of, 124
  wear of, 510
Incisal embrasures, 125f
Incisivization, 6, 6f
Incisoproximal cutback, 430f–432f
Incisors. *See also* Central incisors; Lateral incisors.
  crown width/length ratios for, 81f, 83f
  endocrowns, 436, 436f
  facial surface of, 6
  failure of, 37f
  form of, 84–93, 84f–93f
  fracture of, 590f–591f
  length of
    alterations in, 330
    augmentation, 582–586
  mandibular
    characteristics of, 98, 98f–99f
    in prosthodontic patients, 82
    stress distribution in, 14, 14f–15f
  maxillary. *See* Maxillary incisors.
  palatal surface of, 6, 16, 17f
  stress distribution in, 12, 13f
  wear of, 90, 92f–93f
Indirect bonded porcelain restorations, 565
Indirect mock-up, 495, 495f–497f
Indirect porcelain veneers, 454f
Indirect restorations
  extreme applications of, 524
  flowchart for, 449t
  laboratory team involved in, 451
  patient management for, 450, 451f
Inhomogeneous microfilled composite resins, 295, 298
In-office bleaching, 236, 238
Inside/outside bleaching, 262, 264, 265f–267f
Interdental black triangles
  closure of, 576, 578, 656, 658
  description of, 54, 55f–56f
Interdental bone loss, 52
Interdental closure, 72, 73f
Interdental contacts, 76, 77f, 346, 576, 638f
Interdental emergence profile, 756f
Interdental finishing tools, 420f
Interdental layering, 348, 349f
Interdental margins, 636
Interdental papilla, 576f
Interdental preparation instruments, 282, 283f
Interdental tooth preparation, 340, 340f
Interdiffusion zone, 288
Interdigitating cusps, 8
Interincisal angles, 124, 124f
Internal ferrule, 414, 415f
Interocclusal space, 518
Interpupillary line, 128, 129f
Intraoral camera, 387
Intraoral scanners, 386
Intrinsic masking
  of nonvital teeth, 724
  selective, 722f–723f, 722–724
Inverted "V," 124
IOB. *See* Inside/outside bleaching.
IPDS. *See* Immediate pre-endodontic dentin sealing.
Irradiance, 303–304
Ishihara plates, 120, 121f
ISO, 542
Isovac mouthpiece, 278

t.me/Dr_Mouayyad_AlbtousH

## J

Jacket crowns
  dentin-bonded, 608, 609f
  full veneer, 727f
  porcelain, 608, 609f

## L

Labial line angles, 88
Labial lobes, 90
Labioproximal transition line angles, 94, 470f
Laboratory team, 451
Laser fluorescence, 346, 347f
Lateral incisors. *See also* Incisors.
  axis of, 74, 75f
  central incisors versus, 94
  characteristics of, 94, 94f
  gingival contour of, 76
  implant for, 56f–57f
  maxillary, 84, 94, 94f
  peg-shaped, 94
Layering techniques, 348, 349f
LED lights, 302, 302f
Lens, 544, 544f–545f
Leucite-reinforced glass-ceramics, 418
Light-activated luting materials, 408
Light-curing composite resins, 730
Light-curing units, 302–303
Light-polymerizing restoratives, 731f
Lingual clearance, 516
Lithium disilicate blocks, 392
Lithium disilicate glass-ceramic, 416, 528
LM-Arte set, 284
Loading
  on posterior teeth, 18
  vertical, 18
Load-to-failure tests, 10
Long-wrap veneers, 654
Loupes, 305
Lower lip line, 126, 127f
Low-intensity polymerization, 303
Low-magnification loupes, 305
Luminophores, 108
Luster, 112
Luting
  additive, 422, 422f–423f, 756, 756f
  adhesive, 759f
  composite resins, 419, 420f
  interdental adjustments during, 752, 752f–753f
  in posterior teeth, 416–423
  thermomodified, 418–420, 420f–421f
Luting ceramics, 725–726, 726f
Luting composite, 725–726, 726f
Luting composite resins, 299–300, 690, 730–731, 731f, 742, 743f, 784

## M

Machine-human connection, 438f
Macroabrasion, 252
Magnification instruments, 305–307, 306f–307f
Mandibular excursions, 748
Mandibular incisors
  characteristics of, 98, 98f–99f
  in prosthodontic patients, 82
  stress distribution in, 14, 14f–15f
Mandibular molars
  cusp of, 147f
  first
    characteristics of, 168, 168f–171f
    cusps of, 168
    left, 170f–171f
  second
    characteristics of, 172, 172f–173f
    left, 174f–175f
Mandibular premolars
  first, 162, 162f–163f
  second, 164, 164f–168f
Marginal crests, 16
Marginal ridges
  description of, 18
  integrity of, 422
  of posterior teeth, 148
Mark II porcelain, 390
Masking
  selective intrinsic, 552, 691, 722f–723f, 722–724
  show-through defect, 754, 754f
Masking veneers, 691
Mastication, 8, 8f, 34
Matrix metalloproteinases, 292
Matrix-in-a-matrix technique, deep margin elevation with, 364, 365f–366f
Maxillary incisors
  central
    development of, 144
    form of, 84–93, 84f–93f
    guided technique for restoration of, 336f
    illustration of, 12, 13f
    permanent, 144
    single-retainer cantilevered resin-bonded fixed dental prosthesis for, 62f
  stress distribution in, 12, 13f
  traumatic fractures of, 272
Maxillary molars
  first
    characteristics of, 154
    left, 156f–157f
    rhomboid shape of, 154, 154f
  second
    characteristics of, 158, 158f
    left, 160f–161f
Maxillary premolars
  first
    buccal cusps of, 148, 148f
    features of, 148, 148f
    left, 149, 150f
    mesial view of, 150
    mesiolingual cusps of, 148, 148f
  second
    characteristics of, 152, 152f–153f
    left, 153f
Maximum cuspal position, 34
Maximum intercuspal position
  illustration of, 537f
  posterior teeth in, 8
Megabrasion, 252, 253f
Mercury, 42
Mesiodistal spaces, 76, 78, 79f
Mesiogingival convexity, 96, 97f
Mesioincisal angle, 124
Mesio-occlusodistal restoration, 304f
Metamerism, 120
Microabrasion, 250, 254
Micro-Dahl principle, 516–518, 517f
Microguided endodontics, 258, 259f
Microhybrid composite resins, 730–731
Microhybrids, 298
Microparticle air abrasion, 684
"Microscallops," 20f–21f
Microtensile bond test, 40
Mimicry, 1
Minimally invasive occlusal veneers, 618f
Miniwings, 52, 53f, 54, 72, 576, 578, 664, 664f–665f
Miris2 shade guide, 328
Mirror, 140
MMPs. *See* Matrix metalloproteinases.
Mock-up analysis, 142, 143f, 178. *See also* Diagnostic mock-up.
Modified Von Mises criterion, 12, 14, 15f, 591f, 646
Molar incisor hypomineralization, 250
Molars. *See also* Mandibular molars; Maxillary molars.
  cuspal deformation of, 51t
  cusps of, 18
MTBS. *See* Microtensile bond test.
Mucogingival junction, 72, 73f
Mucogingival surgery, 454, 454f–455f
mVM. *See* Modified Von Mises criterion.

## N

Nanofilled composite resins, 295, 298
Natural Class 1 layering, 348, 349f
Natural guided stratification technique, 331f–332f
Natural layering concept, 328
"Negative space," 124, 142
NGVB. *See* Nightguard vital bleaching.




t.me/Dr_Mouayyad_AlbtousH

Nightguard vital bleaching
carbamide peroxide in, 236, 237f, 238
in cervical area, 246, 247f
in children, 242
composite resins and, 248
description of, 236
duration of use, 240
examination before, 240, 242
fluorosis stains treated with, 248, 249f
gingival health improvements with, 238, 239f
limitations of, 248
microabrasion with, 250
in pregnancy, 242
resistance to, 570, 571f
results of, 240, 241f
shade determination for, 240, 242
splotchy stage of, 242, 243f
step-by-step approach, 242, 245f
successes of, 240, 241f
tetracycline-stained teeth treated with, 240, 241f
tooth hypersensitivity caused by, 246
translucency and, 242, 244
tray used in, 242, 244, 245f
Nonarticular wear, 34, 35f
Nonscalloped nonreservoir bleaching tray, 245f

## O

Oblique ridge, 18
Oblique ridges, 148
Occlusal splint, 528, 528f
Occlusal veneers, 616–619, 617f–619f
Occlusal wear, 35f
Occlusion
Class III, 528–536, 529f–541f
deviations of, 176
natural history of, 34, 35f
normal, 176
posterior, 518
vertical dimension of, 16, 18, 520, 528, 600
Odontoblasts, 144
One-step, double-mix impression technique, 666, 668, 668f–671f
One-step, single-mix technique, 672, 674f–675f
Onlays
composite resin inlays/onlays, 394–399
fracture of, 786, 787f
try-in of, 414, 415f
Opalescence, 100, 101f
Open sandwich restorations, 353, 354f
OptiBond FL, 290, 292, 348, 398, 404, 405f
Oral hygiene
interdental closure affected by, 72
professional, 772–775, 773f–775f
Organofunctional silanes, 738
Orthodontics, 456
Orthognathic surgery, 456
Oscillating preparation instruments, 282f
Outer carious dentin, 344
Overglazing, 712
Over-the-counter bleaching, 238
Ovoid shape, of tooth, 86, 87f, 140
Oxygen inhibition, 302

## P

Palatal concavity, 16
Palatal fossa, 12
Palatal silicon index, 632, 708
Palatal stops, 16
Palatal surface
of canines, 7f
of incisors, 6, 16, 17f
Paradigm MZ100, 300, 300f, 394, 395f, 397f
Partial veneers, 308
Patient-operatory-laboratory relationships, 448, 449f
Pediatric dentistry. *See* Children.
Peg-shaped lateral incisors, 94
Perceptual skills, 134, 135f
Perikymata, 112, 336
Periodontal diseases
description of, 52
interdental closure affected by, 72
Periodontitis, 578f–581f
Peripheral seal concept, 345f
Peripheral seal zone, 344
Photoinitiators, 301
Photopolymerization, 301
Photoshop Smile Design, 452, 452f–453f, 506f
Physiologic enamel cracking, 20–27, 24f–25f, 29f
PICN. *See* Polymer-infiltrated ceramic network.
Pits and fissures, 26, 26f–27f
Platinum foil technique, 684
PMMA. *See* Polymethyl methacrylate.
Polishing, 714, 774
Polymer-infiltrated ceramic network
bonding, 424
description of, 390, 392
etching of, 418
wear of, 392, 393f
Polymerization contraction stress, 353
Polymerization kinetics, 303–304
Polymerization shrinkage, 348, 408
Polymethyl methacrylate, 294, 478, 509f, 673f
Porcelain
advantages and disadvantages of, 567t
characteristics of, 567t
silane-treated, 740, 740f
Porcelain jacket crown, 608, 609f
Porcelain laminates, 566, 572
Porcelain onlay fracture, 786, 787f
Porcelain veneers, 650
chipped, 782, 783f
Class 3 composite resin restoration replacement, 796, 797f
dentin-bonded, for incisor restoration, 37f
indirect, 454f
maxillary, 140, 141f
Porcelain-fused-to-metal abutment, 594
Porcelain-fused-to-metal crown, 608, 616
Porphyrins, 346
Postbonding cracks, 790, 790f–795f
Posterior mock-ups, 520
Posterior teeth. *See also* Molars; Premolars; *specific teeth.*
aging of, 34, 34f–35f
anterior teeth and, 146, 146f
CAD/CAM restorations
ceramics, 388–393
composite resins, 388–393
description of, 388
fatigue survival of, 388, 389f
cusps of, 146, 147f
direct restorations in
finishing, 356, 357f
layering techniques, 348, 349f
polishing, 356, 357f
sandwich restorations, 353–356, 354f–355f
tooth preparation, 340–346, 340f–346f
drawing of, 202–227
elements of, 146f–147f, 146–148
embryology of, 144, 145f
formation of, 144, 145f
function of, 8, 18, 18f–19f
grooves of, 146, 147f
loading effects on, 18
luting procedures in, 416–423
marginal ridge of, 148
in maximum intercuspal position, 8
mechanics of, 18, 18f–19f
morphology of, 144–177
oblique ridge of, 148
pits and fissures in, 26, 26f–27f
rationalized shape of, 8, 8f–9f
ridges of, 146, 147f, 148
transverse ridge of, 148
triangular ridge of, 148
wear of, 34, 34f–35f
Posts and cores, 610
Potassium nitrate, 246
Prebonding cracks, 758, 758f–759f
Pregnancy, nightguard vital bleaching in, 242
Premolars
cuspal deformation of, 50f
cusps of, 18

t.me/Dr_Mouayyad_AlbtousH

mandibular. *See* Mandibular premolars.
maxillary. *See* Maxillary premolars.
Prep-Ceram, 282, 283f
Pressed ceramic, 686
Printed models, 699, 699f–701f
Prismatic loupes, 306
Professional hygiene, 772–775, 773f–775f
Prototyping, 48
Provisional restorations
cementing of, 678, 679f
fabrication of, 672–676, 673f–677f
glazing of, 676
one-step, double-mix technique for, 672
one-step, single-mix technique for, 672, 674f–675f
shrink-fit locking of, 678, 678f
spot-bonding of, 680, 680f–681f
two-step, double-mix technique for, 676, 676f–677f
veneers, 674f, 676f–678f
Proximal adjustments, 752, 752f–753f
Proximal box elevation, 358
PSD. *See* Photoshop Smile Design.
Psychology, 134
PSZ. *See* Peripheral seal zone.
Pulp
exposure of, tooth fragment reattachment in, 274
formation of, 22
Pulp capping, direct, 408

## Q

Quartz-tungsten-halogen lights, 302

## R

Rationalized shape
of anterior teeth, 6, 6f–7f
of posterior teeth, 8, 8f–9f
Rayleigh scattering effect, 100, 101f–102f
RBFDPs. *See* Resin-bonded fixed dental prostheses.
Refractory die technique, porcelain fired over
alveolar model, 696, 698f, 701f
description of, 684
master casts in, 691–701, 692f–701f
printed models, 699, 699f–701f
refractory dies, 694
single dies, 691, 692f, 694, 695f
soft tissue model, 694, 697f–699f
solid model, 694, 696f, 699f
steps involved in, 692f
Rehydration, 253f
Remineralization, 254
Resilience, 4, 4f–5f
Resin bonding, 40–41, 41f, 416
Resin infiltration, 254, 255f–257f
Resin polymerization, 301
Resin-based provisional materials, 408
Resin-bonded fixed dental prostheses, 58, 60, 60f–62f
Resin-modified glass-ionomer cements
clinical uses of, 294
closed sandwich use of, 353
development of, 294
pediatric dentistry uses of, 44
Resin-to-porcelain chemical coupling, 739f
Restorative materials
crack propensity of, 725, 726f–727f
resin bonding to, 40
Retinal fatigue, 116, 118
Root resorption, 260
Rubber dam, 278, 278f

## S

Sandblasters, 776, 777f
"Sandwich" layering, 326, 326f–327f
Sandwich restorations, 353–356, 354f–355f
Sandwich techniques, 294, 348, 430f, 676f–677f
Scalers, 772
Scaling, 772, 773f
Sclerotic dentin, 292
Selective intrinsic masking, 552, 691, 722f–723f, 722–724
Self-etching systems, 288
Self-polymerization, 301
Semi-(in)direct CAD/CAM restorations
classification of, 379, 381t
description of, 379
direct intraoral inlay, 382, 383f
extraoral inlay, 384, 384f–385f
historical perspective of, 379–385
try-in of, 416
Semipermeability, 234
Sensodyne Pronamel, 246
Separation rings, 346, 347f
Shade documentation/communication, 548–554, 549f–561f
Shade tabs, 551f, 722
Show-through defect, 754, 754f
Shrink-fit locking, 678, 678f
Silane-treated porcelain, 740, 740f
Silanization, 738–742, 739f–740f
Silicatization, 776
Silicoating, 778, 779f
Silicon indexes, 478, 479f, 533f, 632
Siloxane, 741f
Simulation, 52
Single-hue composite resins, 328–330, 329f
Single-retainer cantilever prostheses, 58, 60, 60f–62f
Single-tooth replacements, 58
Smear layer, 286
Smile
aging effects on, 30
analysis of, 132
asymmetric balance of, 138
dynamic balance of, 138–140
esthetic integration with, 70
lower lip line, 126, 127f
"natural," 132
Photoshop Smile Design, 452, 452f–453f, 506f
Smile alignment, 128, 129f–131f
Smile line, 126
Sodium fluoride, 774
Sodium perborate with water, 262
SoftClamp, 278
Sonic oscillating preparation techniques, 642f–643f
Sonic scalers, 772
Spot-bonding, of provisional restorations, 680, 680f–681f, 732
Square shape, of tooth, 86, 87f, 140
Stone dies, 691
Stress distribution
determinants of, 16
enamel thickness effects on, 16, 16f–17f, 32
in mandibular incisors, 14, 14f–15f
in maxillary central incisors, 12, 13f
Subgingival margins, 358, 360, 361f, 387
Subgingival restorations, 367
Subtractive color model, 120
Subtractive wax-up, 492f–494f
Superclosed sandwich, 357f
Surface conditioning, 419t
Surface texture
anterior teeth, 336–339, 336f–339f
description of, 112–114, 113f–114f
Surgical crown lengthening, 359

## T

Teeth. *See also* Anterior teeth; Posterior teeth; *specific teeth.*
aging of, 28–35
biology of, 2
"biomechanisms" of, 26, 26f
characterization of, 100–111, 100f–111f
circle of death for, 46, 46f–47f
esthetics of, 2
fluorescence of, 104, 107f, 108, 110
forms of, 86, 87f
function of, 2
implants versus, 54
load resistance by, 36
physiologic performance of, 2f
resilience of, 4, 4f–5f
shapes of, 86, 87f, 140
surface texture of, 112–114, 113f–114f
translucency of, 101f, 104



t.me/Dr_Mouayyad_AlbtousH

TEGDMA. *See* Triethylene glycol dimethacrylate.
Teleconverter, 544
Teledentistry, 541
Telescopes, 305, 306f
Temp-Bond Clear, 679f
Temporomandibular disorders, 176
10-methacryloxyloxydcyl dihydrogen phosphate, 290
Tensile strength, 12
Tetracycline-stained teeth
  anterior indirect bonded porcelain restorations for, 570, 570f–571f
  laminate veneers for, 248
  nightguard vital bleaching of, 240, 241f
  walking bleaching technique for, 260
Thermal expansion, of composite resins, 38
Thermocatalytic technique, 260
Thermomodified luting, 418–420, 420f–421f
Three-increment technique, 314, 314f–318f, 320f
Through the lens telescopes, 306
Tight bites, 514, 600
Tooth axis, 74, 75f
Tooth dimensions
  brightness effects on, 82, 82f
  crown width/length ratios, 80, 81f, 82, 83f
  as fundamental esthetic criterion, 76, 78, 79f
  relative, 80f
Tooth fracture
  under amalgam, 46
  mandibular, 592
Tooth fragment
  reattachment of, 272–277, 273f–277f
  rebonding of, 592, 648, 778f
Tooth hypersensitivity, 246
Tooth preparation
  anterior indirect bonded porcelain restorations. *See* Anterior indirect bonded porcelain restorations, tooth preparation.
  for direct restorations in posterior teeth, 340–346, 340f–346f
  interdental, 340, 340f
Tooth structure loss, 518–528, 519f–528f
Tooth whitening
  definition of, 236
  strips for, 238, 239f
Tooth-colored materials, amalgam versus, 42
Torsio dentis, 88, 475f, 477
Transition line angles
  of central incisors, 85f
  definition of, 84
  labioproximal, 94
  of lateral incisors, 94, 94f
Translucency
  description of, 101f, 104
  discoloration versus, 244f
  nightguard vital bleaching and, 242, 244
Transverse ridges, of posterior teeth, 148
Trendy 3-layer concept, 328
Triangular ridges, of posterior teeth, 148
Triangular shape, of tooth, 86, 87f
Tribochemical silicoating, 776
Triethylene glycol dimethacrylate, 254, 295, 296f
"Trinitarian" adhesion, 40
Try-in
  of ceramic restoration, 732–734, 733f
  digital, 558f
  of onlays, 414, 415f
  of semi-(in)direct CAD/CAM restorations, 416
TTL system, 546
Turner's hypoplasia, 242, 243f, 250
2D-3D-4D concept, 178
Typodont model, 178

## U

UDMA. *See* Urethane dimethacrylate.
Ultrasonic scalers, 772
Umbrella effect, 614, 614f–615f
Undercuts, 363, 363f
Universal additive principle, 319, 319f–321f
Urethane dimethacrylate, 296f, 300, 394

## V

Value, 116, 117f
VDO. *See* Vertical dimension of occlusion.
Veneers
  autonomous, 691, 702, 731
  ceramic, 690–691
  contact lens, 690f, 690–691
  cracked, 683f
  e.max CAD glass-ceramic, 687f
  high-performance polymer material, 58
  masking, 691
  occlusal, 616–619, 617f–619f
  porcelain. *See* Porcelain veneers.
  provisional, 674f, 676f–678f
Vertical dimension of occlusion, 16, 18, 520, 528, 600
Vertical segmentation, 718
V-factor, 304
Visagism, 86
Visual tensions, 70, 132, 137f, 141f
VITA-based shade selection, 317f
Vital bleaching
  description of, 30, 234
  nightguard, 236–238, 237f
Vitalescence, 108, 108f
Vitrification, 303
VM. *See* Von Mises criterion.
Volumetric wear, 34
von Korff fibers, 20
Von Mises criterion, 12
V-shaped concavities, 90, 90f
V-shaped veneers, 540f

## W

Walking bleach technique
  bleaching mixtures for, 262, 263f
  endodontically treated teeth, 258
  final restoration after, 268, 269f
  history of, 260
  indications for, 264, 265f–267f, 608
  inside/outside bleaching, 262, 264, 265f–267f
  limited response to, 572, 573f
  long-term follow-up of, 270, 271f
  organic discoloration treated with, 270, 271f
  palatal restoration after, 268, 269f
  prognosis of, 270
  root resorption associated with, 260
  safety of, 260, 261f
Wax-ups. *See* Additive wax-up; Diagnostic wax-up.
WBT. *See* Walking bleach technique.
Wear
  abrasion versus, 34
  of anterior teeth, 28–33, 29f–33f
  biocorrosion as cause of, 514
  of central incisors, 92f–93f
  depth of, 34
  erosive, 598
  of incisal edges, 510
  of incisors, 90, 92f–93f
  polymer-infiltrated ceramic network, 392, 393f
  of posterior teeth, 34, 34f–35f
  volumetric, 34
Wet dentin bonding, 404
White enamel defects
  description of, 250, 252t
  ultraconservative treatments for, 252t
White halo effect, 106, 106f
Whitening. *See* Tooth whitening.
Whitening strips, 238, 239f
Working distance, 305

## Z

Zenith of the gingival seam, 74, 75f
Zirconia prosthesis, 60

t.me/Dr_Mouayyad_AlbtousH